A 55-year-old man comes to the office due to progressive headaches over the past 2 months. The headaches are throbbing, often associated with nausea, and worsen whenever the patient coughs or bears down during a bowel movement. Medical history is significant for episodic migraine without aura. MRI of the brain with gadolinium reveals a cystic mass, as shown in the image below:

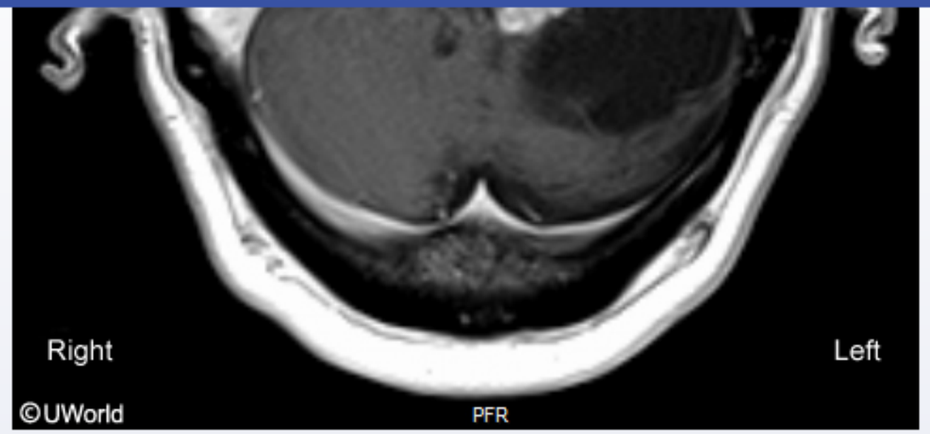

Which of the following findings is most likely to be seen on physical examination of this patient?

- A. Left dysdiadochokinesia
- B. Left Horner syndrome
- C. Left oculomotor nerve palsy
- D. Photophobia
- E. Right hemiparesis
- F. Right hemisensory loss
- G. Right homonymous hemianopia
- H. Right lower facial droop

Submit

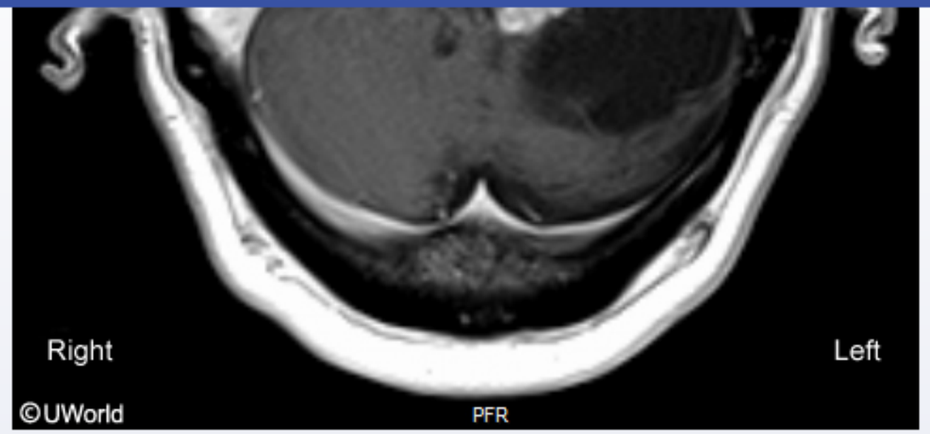

Which of the following findings is most likely to be seen on physical examination of this patient?

- A. Left dysdiadochokinesia (66%)
- B. Left Horner syndrome (3%)
- C. Left oculomotor nerve palsy (4%)
- D. Photophobia (1%)
- E. Right hemiparesis (8%)
- F. Right hemisensory loss (3%)
- G. Right homonymous hemianopia (8%)
- H. Right lower facial droop (3%)

Omitted
Correct answer

66%
Answered correctly

15 secs
Time Spent

07/06/2020
Last Updated

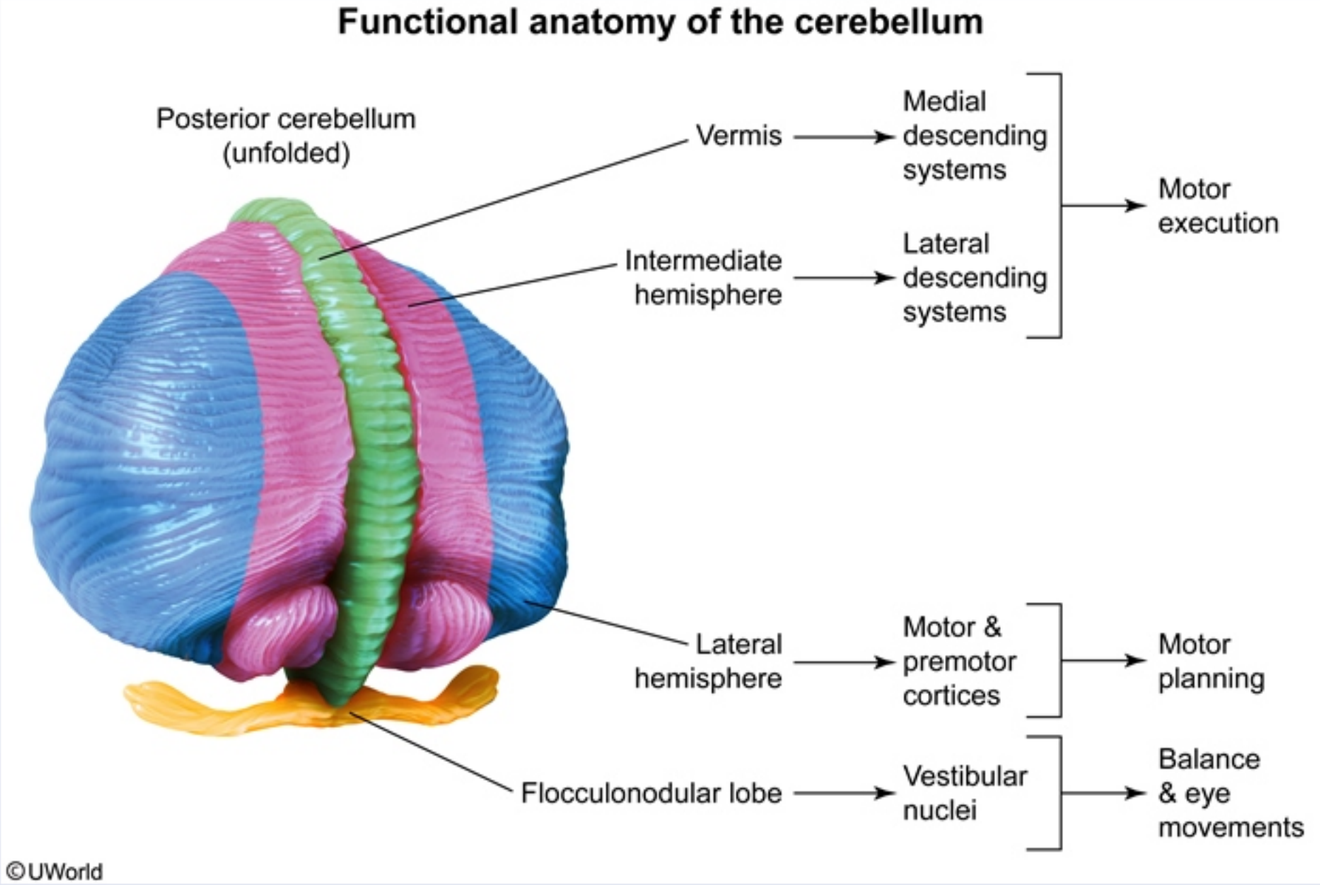

This patient has an expanding cystic neoplasm (likely a hemangioblastoma) in the **left cerebellar hemisphere** causing progressive headaches that worsen with Valsalva (maneuver increases intracranial pressure).

The cerebellum is the largest structure in the posterior fossa and consists of the vermis at the midline and 2 cerebellar hemispheres. The cerebellar hemispheres are primarily responsible for motor planning and **coordination** of the **ipsilateral extremities** via their connections with the lateral descending motor systems (eg, lateral corticospinal tract, rubrospinal tract). Consequently, lesions affecting the left cerebellar hemisphere typically result in **left dysdiadochokinesia** (impaired rapid alternating movements), limb dysmetria (overshoot/undershoot during targeted

©UWorld

This patient has an expanding cystic neoplasm (likely a hemangioblastoma) in the **left cerebellar hemisphere** causing progressive headaches that worsen with Valsalva (maneuver increases intracranial pressure).

The cerebellum is the largest structure in the posterior fossa and consists of the vermis at the midline and 2 cerebellar hemispheres. The cerebellar hemispheres are primarily responsible for motor planning and **coordination** of the **ipsilateral extremities** via their connections with the lateral descending motor systems (eg, lateral corticospinal tract, rubrospinal tract). Consequently, lesions affecting the left cerebellar hemisphere typically result in **left dysdiadochokinesia** (impaired rapid alternating movements), limb dysmetria (overshoot/undershoot during targeted movement), and **intention tremor** (tremor during targeted movement).

The cerebellar vermis modulates axial/truncal posture and coordination via connections with the medial descending motor systems (eg, anterior corticospinal, reticulospinal, vestibulospinal, and tectospinal tracts). Lesions to this region result in truncal ataxia (eg, wide-based, unsteady gait). Vertigo and nystagmus may also occur due to disruption of the inferior vermis and the flocculonodular lobe.

(Choice B) Horner syndrome (eg, partial ptosis, miosis, anhidrosis) is associated with lesions affecting the ipsilateral lateral hypothalamus or sympathetic tracts in the brainstem (eg, lateral medulla, carotid artery).

(Choice C) Oculomotor nerve palsy (mydriasis, complete ptosis, and "down and out" deviation of the eye) may occur with an ipsilateral lesion at the level of the anterior midbrain or midbrain tegmentum.

(Choice D) Acute migraine is characterized by throbbing unilateral headache associated with nausea/vomiting, phonophobia, and photophobia. Migraine is unlikely in this patient as his headache worsens with Valsalva (suggestive of increased intracranial pressure) and neuroimaging shows a cerebellar mass.

(Choices E, F, and H) Contralateral hemiparesis, hemisensory loss, and/or lower facial droop can occur with cortical, subcortical, or upper brainstem lesions.

(Choice G) A unilateral visual pathway lesion beyond the optic chiasm (eg, optic tract, lateral geniculate body, optic radiations, primary visual cortex) can cause contralateral homonymous hemianopia.

Educational objective:
The cerebellar hemispheres are responsible for motor planning and coordination of the ipsilateral extremities via their connections with the lateral

A 34-year-old man comes to the clinic with a 3-week history of difficulty hearing. He finds it increasingly difficult to tolerate everyday sounds. He also complains of ear pain and often avoids public places as a result. The patient has no past medical history and takes no medications. Injury to which of the following cranial nerves is most likely responsible for his condition?

- A. Accessory (1%)
- ✓ B. Facial (83%)
- C. Glossopharyngeal (7%)
- D. Hypoglossal (1%)
- E. Vagus (6%)

Omitted
Correct answer
B

83%
Answered correctly

02 secs
Time Spent

03/08/2020
Last Updated

Explanation

The **middle ear cavity** contains 3 auditory ossicles (malleus, incus, and stapes) and 2 skeletal muscles (tensor tympani and stapedius) that participate in the transmission of sound from the tympanic membrane to the cochlea. The stapedius muscle arises from the wall of the tympanic cavity and inserts on the neck of the stapes. It is innervated by the **stapedius nerve**, a branch of the **facial nerve (CN VII)**. The stapedius muscle functions to stabilize the stapes; paralysis of the muscle (secondary to an injury or lesion to the facial nerve) causes the stapes to oscillate more widely, producing **hyperacusis**. Patients will typically complain of increased sensitivity to everyday sounds (eg, shutting doors, ringing phones, traffic) and will often withdraw socially as a result. Treatment consists of retraining (or sound) therapy using broadband noise (eg, "white noise").

corticospinal, reticulospinal, vestibulospinal, and tectospinal tracts). Lesions to this region result in truncal ataxia (eg, wide-based, unsteady gait). Vertigo and nystagmus may also occur due to disruption of the inferior vermis and the flocculonodular lobe.

(Choice B) Horner syndrome (eg, partial ptosis, miosis, anhidrosis) is associated with lesions affecting the ipsilateral lateral hypothalamus or sympathetic tracts in the brainstem (eg, lateral medulla, carotid artery).

(Choice C) Oculomotor nerve palsy (mydriasis, complete ptosis, and "down and out" deviation of the eye) may occur with an ipsilateral lesion at the level of the anterior midbrain or midbrain tegmentum.

(Choice D) Acute migraine is characterized by throbbing unilateral headache associated with nausea/vomiting, phonophobia, and photophobia. Migraine is unlikely in this patient as his headache worsens with Valsalva (suggestive of increased intracranial pressure) and neuroimaging shows a cerebellar mass.

(Choices E, F, and H) Contralateral hemiparesis, hemisensory loss, and/or lower facial droop can occur with cortical, subcortical, or upper brainstem lesions.

(Choice G) A unilateral visual pathway lesion beyond the optic chiasm (eg, optic tract, lateral geniculate body, optic radiations, primary visual cortex) can cause contralateral homonymous hemianopia.

Educational objective:
The cerebellar hemispheres are responsible for motor planning and coordination of the ipsilateral extremities via their connections with the lateral descending motor systems. Consequently, cerebellar hemisphere lesions typically result in ipsilateral dysdiadochokinesia, limb dysmetria, and/or intention tremor.

References

- Lesion-symptom mapping of the human cerebellum.

Anatomy	Nervous System	Brain tumors
Subject	System	Topic

Copyright © UWorld. All rights reserved.

A 34-year-old man comes to the clinic with a 3-week history of difficulty hearing. He finds it increasingly difficult to tolerate everyday sounds. He also complains of ear pain and often avoids public places as a result. The patient has no past medical history and takes no medications. Injury to which of the following cranial nerves is most likely responsible for his condition?

A. Accessory
B. Facial
C. Glossopharyngeal
D. Hypoglossal
E. Vagus

Submit

1
2
3
4
5
6
7
8
9
10
11
12
13
14
15
16
17
18
19
20
21
22
23
24
25
26
27
28
29
30
31

Explanation

Exhibit Display

Peripheral facial palsy

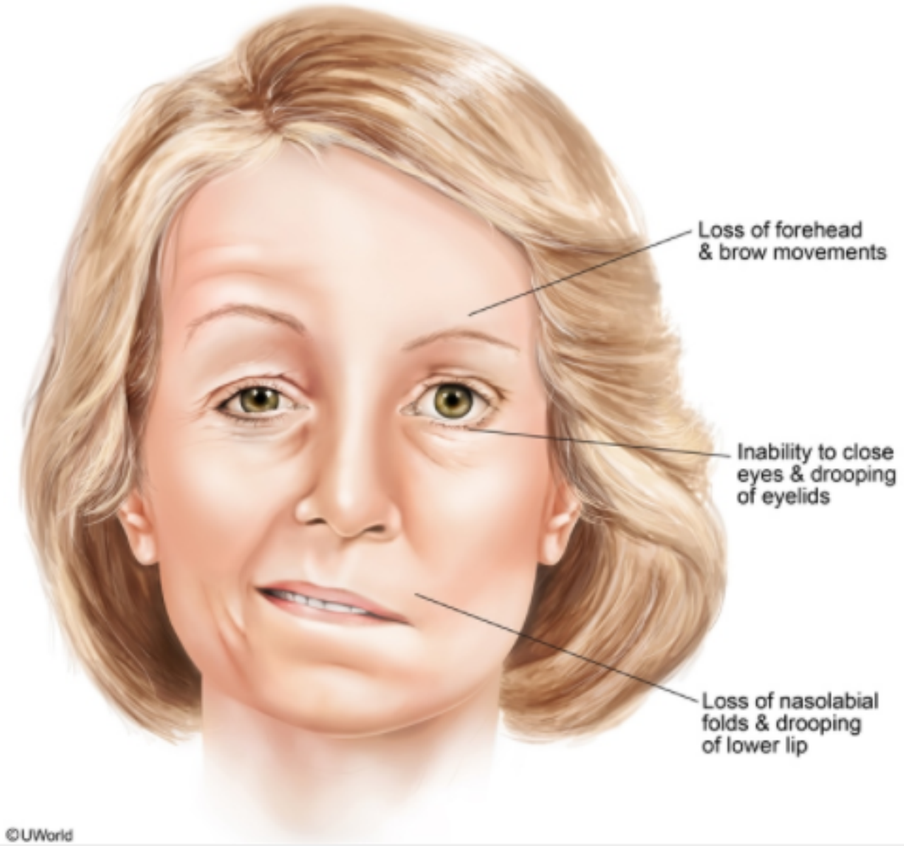

Zoom In | Zoom Out | Reset | Add To New Card | Existing Card

Tympanic

1
2
3
4
5
6
7
8
9
10
11
12
13
14
15
16
17
18
19
20
21
22
23
24
25
26
27
28
29
30
31

Middle ear anatomy

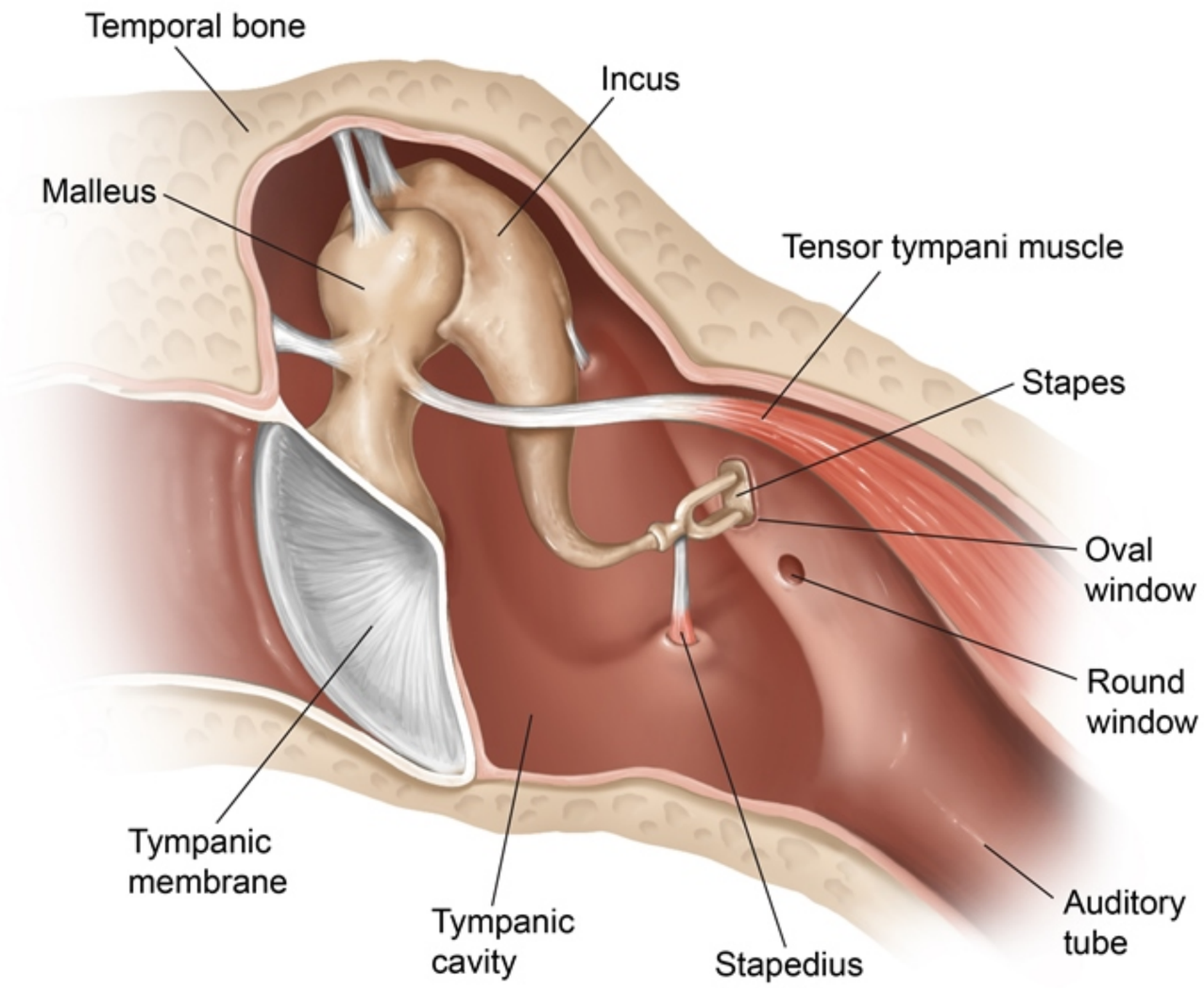

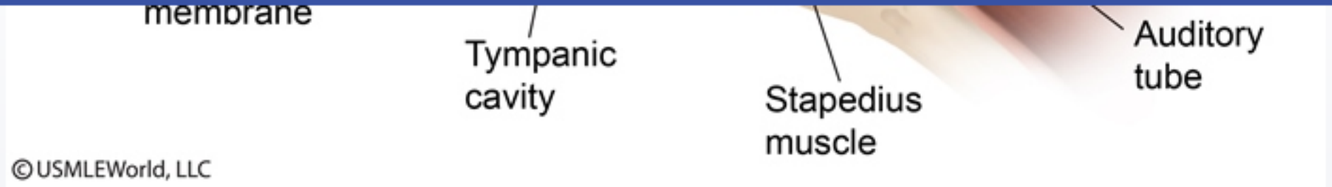

The **middle ear cavity** contains 3 auditory ossicles (malleus, incus, and stapes) and 2 skeletal muscles (tensor tympani and stapedius) that participate in the transmission of sound from the tympanic membrane to the cochlea. The stapedius muscle arises from the wall of the tympanic cavity and inserts on the neck of the stapes. It is innervated by the **stapedius nerve**, a branch of the **facial nerve (CN VII)**. The stapedius muscle functions to stabilize the stapes; paralysis of the muscle (secondary to an injury or lesion to the facial nerve) causes the stapes to oscillate more widely, producing **hyperacusis**. Patients will typically complain of increased sensitivity to everyday sounds (eg, shutting doors, ringing phones, traffic) and will often withdraw socially as a result. Treatment consists of retraining (or sound) therapy using broadband noise (eg, "white noise").

The tensor tympani muscle arises from the cartilaginous portion of the auditory tube and the adjoining part of the sphenoid bone and inserts into the malleus. It functions to contract the tympanic membrane medially, thereby increasing its tension and dampening sound transmission. It is innervated by the mandibular branch of the trigeminal nerve (CN V_3).

Ipsilateral hyperacusis is a common finding associated with Bell's palsy (unilateral/peripheral facial paralysis).

(Choices A, C, D, and E) The accessory (CN XI), glossopharyngeal (CN IX), hypoglossal (CN XII), and vagus (CN X) nerves are not associated with hyperacusis.

Educational objective:
The stapedius muscle is innervated by the stapedius nerve (a branch of the facial nerve). Paralysis of the stapedius muscle results in hyperacusis (eg, increased sensitivity to sound).

Anatomy	Nervous System	Facial nerve
Subject	System	Topic

Copyright © UWorld. All rights reserved.

A 53-year-old man comes to the emergency department due to severe lower back pain. The patient's back pain started 2 weeks ago without any preceding trauma and has been keeping him awake at night. The pain has acutely worsened over the past 2 days and is not relieved with over-the-counter pain medications. His vital signs are within normal limits. Examination shows low back pain that is worse with back flexion and raising of the legs; it radiates into his left leg. Pinprick in the perianal area does not cause rapid contraction of the anal sphincter. The rest of the neurologic examination is normal. Which of the following nerve roots is most likely to be involved in this patient's condition?

- A. T12
- B. L2
- C. L4
- D. L5
- E. S1
- F. S4

Submit

A 53-year-old man comes to the emergency department due to severe lower back pain. The patient's back pain started 2 weeks ago without any preceding trauma and has been keeping him awake at night. The pain has acutely worsened over the past 2 days and is not relieved with over-the-counter pain medications. His vital signs are within normal limits. Examination shows low back pain that is worse with back flexion and raising of the legs; it radiates into his left leg. Pinprick in the perianal area does not cause rapid contraction of the anal sphincter. The rest of the neurologic examination is normal. Which of the following nerve roots is most likely to be involved in this patient's condition?

- A. T12 (0%)
- B. L2 (3%)
- C. L4 (5%)
- D. L5 (5%)
- E. S1 (25%)
- ✓ F. S4 (59%)

Omitted
Correct answer
F

59%
Answered correctly

02 secs
Time Spent

03/04/2020
Last Updated

Explanation

Relation of spinal nerve roots to vertebrae

1
2
3
4
5
6
7
8
9
10
11
12
13
14
15
16
17
18
19
20
21
22
23
24
25
26
27
28
29
30
31

Relation of spinal nerve roots to vertebrae

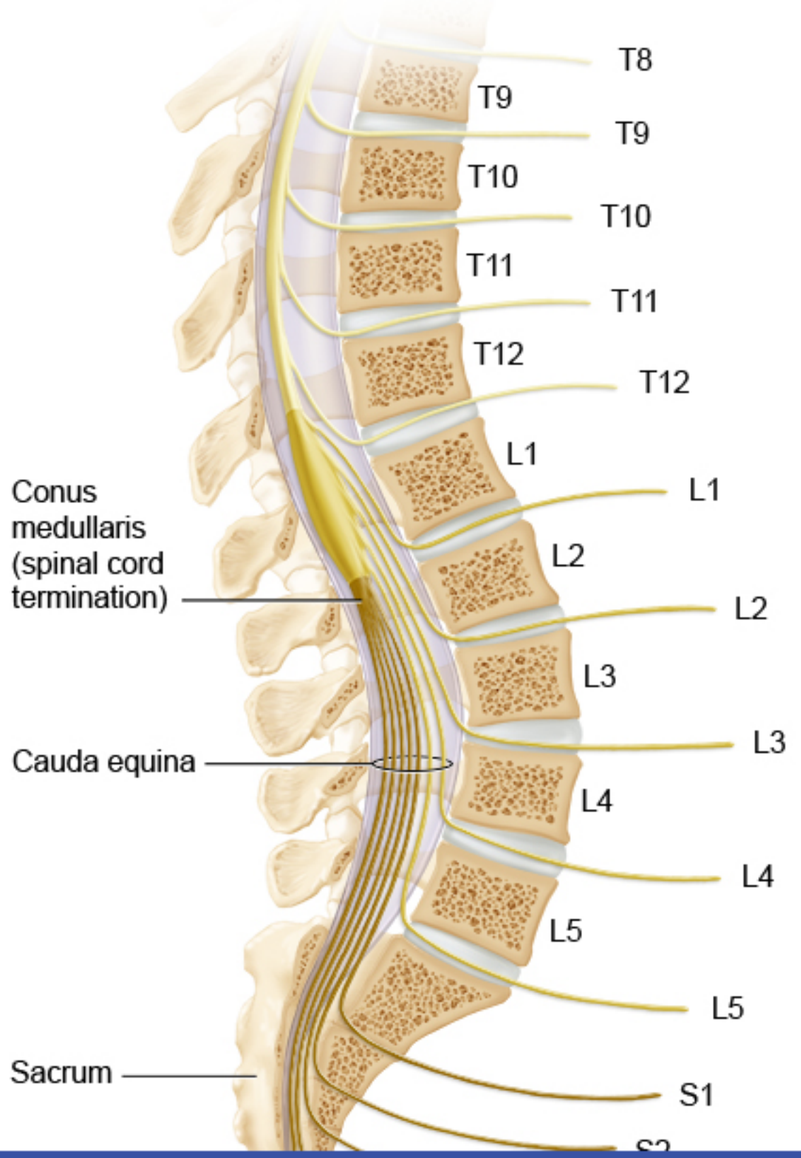

This patient's worsening low back pain with a positive straight leg test is consistent with subacute **lumbosacral radiculopathy**, which most often occurs due to a herniated disk; less common causes include neoplasm, fracture, or epidural hematoma/abscess. Compression of the spinal cord and/or nerve roots can cause a wide range of deficits based on the level(s) involved. This patient's **perianal anesthesia** with loss of the anocutaneous reflex indicates involvement of the **S2-S4** nerve roots.

In an adult, the spinal cord terminates in a tapering fashion as the **conus medullaris** (T12-S4) at the L1-L2 vertebral level. The collection of spinal nerves below this point (eg, L3-S4) exit inferiorly through their respective intervertebral foramina and are referred to as the **cauda equina** (ie, horse's tail). Lesions at the L1-L5 vertebral levels can affect the conus medullaris and/or T12-S4 nerve roots, resulting in a characteristic constellation of symptoms:

- **Radicular low back pain** (ie, radiates down one or both legs)
- Saddle/**perianal anesthesia** (S2-S4)
- Bowel and bladder dysfunction
- Lower extremity **weakness**

This pattern of neurologic deficits can occur with either conus medullaris syndrome (lesions around L1-L2 vertebrae) or cauda equina syndrome (lesions below L2 vertebra). **Conus medullaris syndrome** typically causes **bilateral**, symmetric lower extremity weakness with upper motor signs (eg, spasticity, hyperreflexia), while **cauda equina syndrome** tends to cause flaccid, **asymmetrical** lower extremity weakness. Due to the potential for further neurologic deterioration, affected patients require **urgent evaluation** including MRI of the spine.

(Choice A) Compression of the T12 nerve roots would result in lower abdominal or groin pain.

(Choices B and C) The L2-L4 spinal nerve roots contribute to the femoral nerve and mediate the quadriceps (ie, patellar) reflex. Lesions affecting these levels would cause loss of this reflex as well as anterior thigh sensory loss or paresthesia.

(Choice D) Lesions affecting the L5 nerve root would cause sensory loss or paresthesia over the lateral thigh and anterior calf.

(Choice E) The S1 nerve root supplies the Achilles reflex along with sensation to the posterior leg and posterolateral calf. Although the Achilles reflex can be affected in patients with lumbosacral radiculopathy, this patient does not have evidence of S1 nerve root involvement on examination.

Educational objective:

Compressive lesions (eg, disk herniation, tumors) affecting the L1-L5 vertebral levels can impinge upon the conus medullaris and/or T12-S4 nerve

- Lower extremity **weakness**

This pattern of neurologic deficits can occur with either conus medullaris syndrome (lesions around L1-L2 vertebrae) or cauda equina syndrome (lesions below L2 vertebra). **Conus medullaris syndrome** typically causes **bilateral**, symmetric lower extremity weakness with upper motor signs (eg, spasticity, hyperreflexia), while **cauda equina syndrome** tends to cause flaccid, **asymmetrical** lower extremity weakness. Due to the potential for further neurologic deterioration, affected patients require **urgent evaluation** including MRI of the spine.

(Choice A) Compression of the T12 nerve roots would result in lower abdominal or groin pain.

(Choices B and C) The L2-L4 spinal nerve roots contribute to the femoral nerve and mediate the quadriceps (ie, patellar) reflex. Lesions affecting these levels would cause loss of this reflex as well as anterior thigh sensory loss or paresthesia.

(Choice D) Lesions affecting the L5 nerve root would cause sensory loss or paresthesia over the lateral thigh and anterior calf.

(Choice E) The S1 nerve root supplies the Achilles reflex along with sensation to the posterior leg and posterolateral calf. Although the Achilles reflex can be affected in patients with lumbosacral radiculopathy, this patient does not have evidence of S1 nerve root involvement on examination.

Educational objective:
Compressive lesions (eg, disk herniation, tumors) affecting the L1-L5 vertebral levels can impinge upon the conus medullaris and/or T12-S4 nerve roots, causing radicular low back pain, changes in bowel/bladder function, saddle/perianal anesthesia (eg, loss of anocutaneous reflex), and lower extremity weakness. Perianal sensation is carried by the S2-S4 nerve roots.

References

- Cauda equina syndrome.
- Definitions of traumatic conus medullaris and cauda equina syndrome: a systematic literature review

Anatomy	Nervous System	Cauda equina syndrome
Subject	System	Topic

Copyright © UWorld. All rights reserved.

1
2
3
4
5
6
7
8
9
10
11
12
13
14
15
16
17
18
19
20
21
22
23
24
25
26
27
28
29
30
31

L5

Exhibit Display

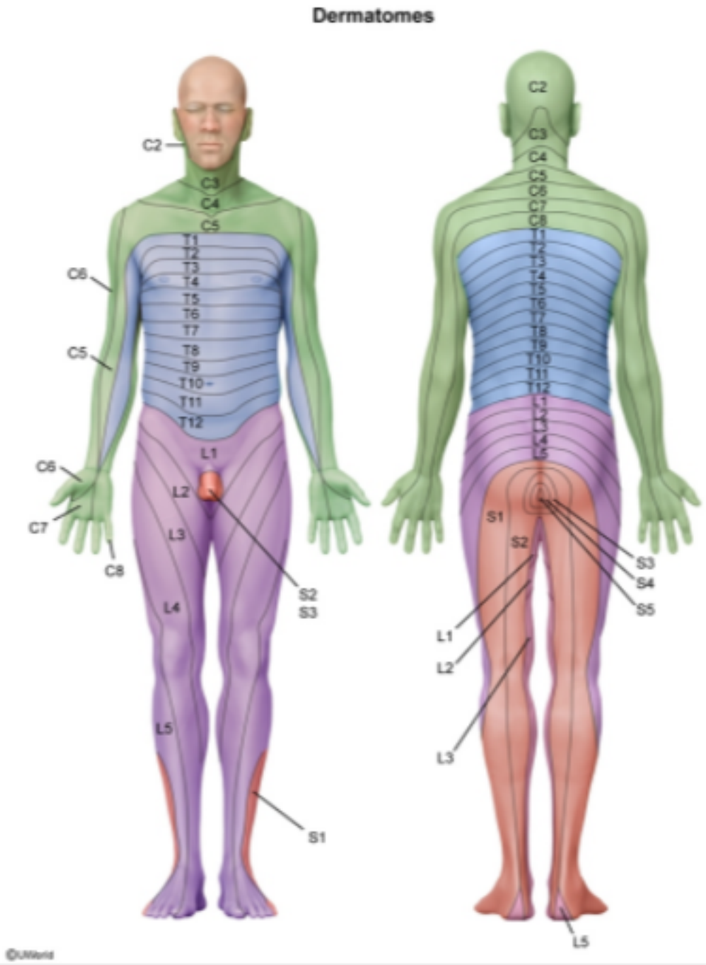

Zoom In | Zoom Out | Reset | Add To New Card | Existing Card

(Choice A) Compression of the T12 nerve roots would result in lower abdominal or groin pain.

A 35-year-old man comes to the office due to a painful tongue sore. For the past 2 weeks he has had a fever and has experienced myalgias and arthralgias. He has no known medical problems. The patient works as a driver for a local delivery service. He had unprotected sex with a stranger approximately 1 month ago. Physical examination shows a rash over his trunk and cervical lymphadenopathy. An ulcer is located on the median sulcus of the tongue and is 2 cm anterior to the foramen cecum. Blood is drawn for an HIV test. The pain sensation from his ulcer is most likely carried by which of the following nerves?

A. Chorda tympani

B. Glossopharyngeal nerve

C. Mandibular division of the trigeminal nerve

D. Maxillary division of the trigeminal nerve

E. Vagus nerve

Submit

A 35-year-old man comes to the office due to a painful tongue sore. For the past 2 weeks he has had a fever and has experienced myalgias and arthralgias. He has no known medical problems. The patient works as a driver for a local delivery service. He had unprotected sex with a stranger approximately 1 month ago. Physical examination shows a rash over his trunk and cervical lymphadenopathy. An ulcer is located on the median sulcus of the tongue and is 2 cm anterior to the foramen cecum. Blood is drawn for an HIV test. The pain sensation from his ulcer is most likely carried by which of the following nerves?

- A. Chorda tympani (9%)
- B. Glossopharyngeal nerve (27%)
- ✓ C. Mandibular division of the trigeminal nerve (50%)
- D. Maxillary division of the trigeminal nerve (8%)
- E. Vagus nerve (3%)

Omitted
Correct answer
C

50%
Answered correctly

02 secs
Time Spent

02/18/2020
Last Updated

Explanation

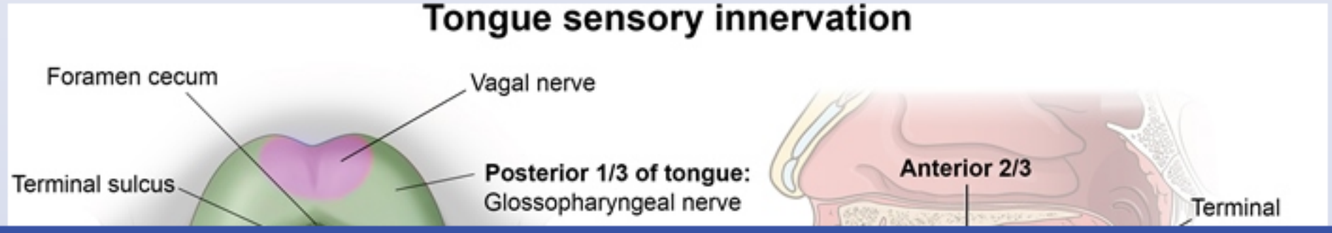

Tongue sensory innervation

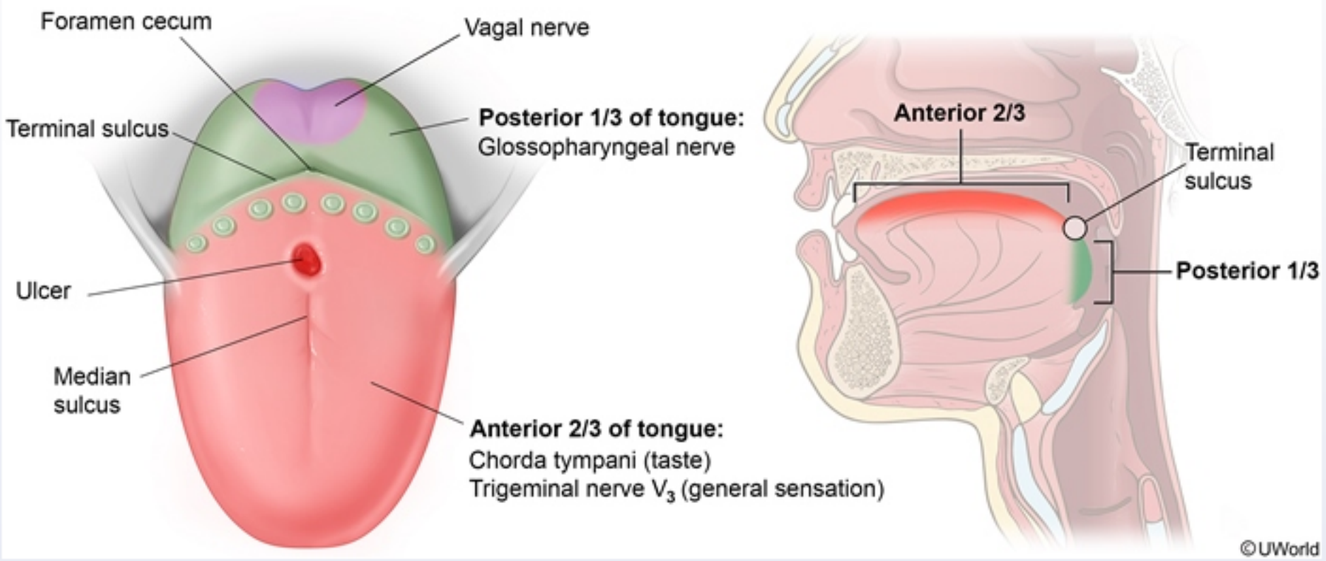

Acute HIV can present with rash, lymphadenopathy, fever, and painful oral ulcers on the tongue. Innervation of the tongue is complex, as there are motor, general sensory, and gustatory (taste) components.

1. **Motor innervation** of the tongue is provided by the hypoglossal nerve (cranial nerve [CN] XII) with the exception of the palatoglossus muscle, which is innervated by the vagus nerve (CN X).
2. **General sensory** innervation of the tongue (including touch, pain, pressure, and temperature sensation) is provided by:
   - Anterior 2/3 of the tongue: mandibular branch of trigeminal nerve (CN V_3)
   - Posterior 1/3 of the tongue: glossopharyngeal nerve (CN IX)
   - Posterior area of the tongue root: vagus nerve (CN X)
3. **Gustatory innervation** (taste buds) is as follows:
   - Anterior 2/3 of the tongue: chorda tympani branch of facial nerve (CN VII)
   - Posterior 1/3 of the tongue: glossopharyngeal nerve (CN IX)
   - Posterior area of the tongue root and taste buds of the larynx and upper esophagus: vagus nerve (CN X)

Tongue sensory innervation

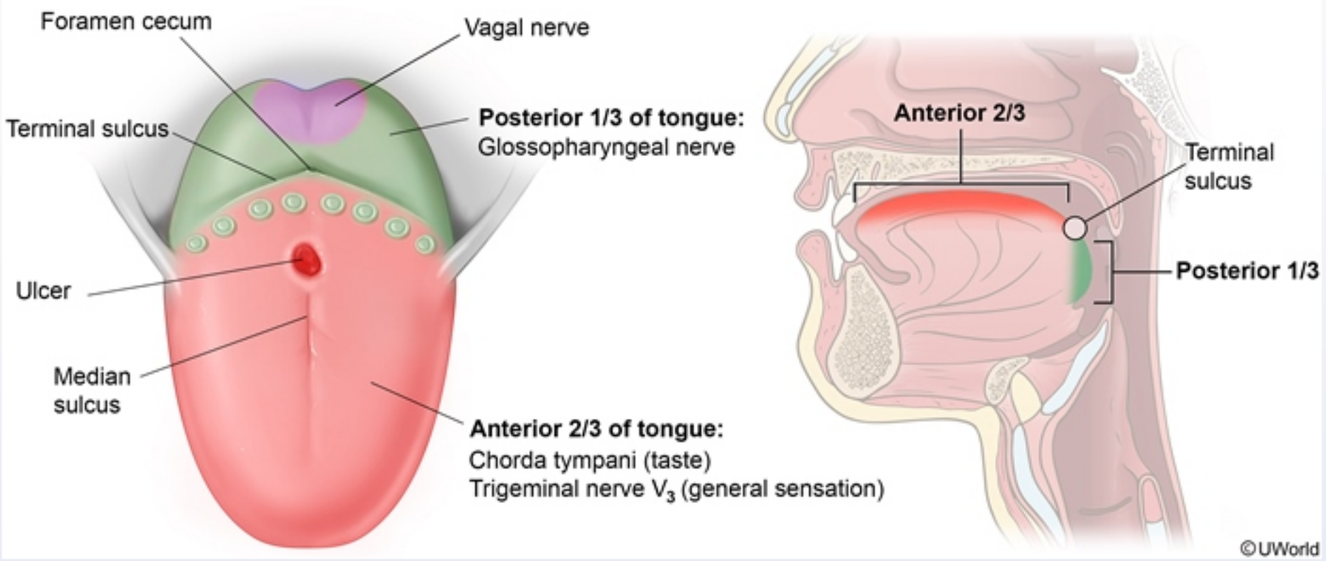

Acute HIV can present with rash, lymphadenopathy, fever, and painful oral ulcers on the tongue. Innervation of the tongue is complex, as there are motor, general sensory, and gustatory (taste) components.

1. **Motor innervation** of the tongue is provided by the hypoglossal nerve (cranial nerve [CN] XII) with the exception of the palatoglossus muscle, which is innervated by the vagus nerve (CN X).
2. **General sensory** innervation of the tongue (including touch, pain, pressure, and temperature sensation) is provided by:
   - Anterior 2/3 of the tongue: mandibular branch of trigeminal nerve (CN V_3)
   - Posterior 1/3 of the tongue: glossopharyngeal nerve (CN IX)
   - Posterior area of the tongue root: vagus nerve (CN X)
3. **Gustatory innervation** (taste buds) is as follows:
   - Anterior 2/3 of the tongue: chorda tympani branch of facial nerve (CN VII)
   - Posterior 1/3 of the tongue: glossopharyngeal nerve (CN IX)
   - Posterior area of the tongue root and taste buds of the larynx and upper esophagus: vagus nerve (CN X)

©UWorld

Acute HIV can present with rash, lymphadenopathy, fever, and painful oral ulcers on the tongue. Innervation of the tongue is complex, as there are motor, general sensory, and gustatory (taste) components.

1. **Motor innervation** of the tongue is provided by the hypoglossal nerve (cranial nerve [CN] XII) with the exception of the palatoglossus muscle, which is innervated by the vagus nerve (CN X).
2. **General sensory** innervation of the tongue (including touch, pain, pressure, and temperature sensation) is provided by:
   - Anterior 2/3 of the tongue: mandibular branch of trigeminal nerve (CN V_3)
   - Posterior 1/3 of the tongue: glossopharyngeal nerve (CN IX)
   - Posterior area of the tongue root: vagus nerve (CN X)
3. **Gustatory innervation** (taste buds) is as follows:
   - Anterior 2/3 of the tongue: chorda tympani branch of facial nerve (CN VII)
   - Posterior 1/3 of the tongue: glossopharyngeal nerve (CN IX)
   - Posterior area of the tongue root and taste buds of the larynx and upper esophagus: vagus nerve (CN X)

Any lesion anterior to the terminal sulcus and foramen cecum, including this patient's oral ulcer, would be located on the **anterior** 2/3 of the tongue. **Pain** from this region (as well as sensations of touch, pressure, and temperature) is transmitted by the **mandibular branch of the trigeminal nerve**.

(Choices A, B, and E) The chorda tympani branch of the facial nerve (CN VII) transmits gustatory sensation from the anterior 2/3 of the tongue but not painful stimuli. The glossopharyngeal nerve (CN IX) transmits taste, pain, temperature, and touch stimuli from the posterior 1/3 of the tongue. The vagus nerve (CN X) innervates the far posterior area of the tongue root, transmitting both gustatory and general sensory stimuli.

(Choice D) The maxillary division of the trigeminal nerve (CN V_2) does not participate in tongue innervation.

Educational objective:
General sensation from the anterior 2/3 of the tongue is carried by the mandibular division of the trigeminal nerve. Gustatory innervation of the anterior 2/3 of the tongue is provided by the chorda tympani branch of the facial nerve.

Anatomy	Nervous System	Trigeminal nerve
Subject	System	Topic

1. **Motor innervation** of the tongue is provided by the hypoglossal nerve (cranial nerve [CN] XII) with the exception of the palatoglossus muscle, which is innervated by the vagus nerve (CN X).
2. **General sensory** innervation of the tongue (including touch, pain, pressure, and temperature sensation) is provided by:
   - Anterior 2/3 of the tongue: mandibular branch of trigeminal nerve (CN V_3)
   - Posterior 1/3 of the tongue: glossopharyngeal nerve (CN IX)
   - Posterior area of the tongue root: vagus nerve (CN X)
3. **Gustatory innervation** (taste buds) is as follows:
   - Anterior 2/3 of the tongue: chorda tympani branch of facial nerve (CN VII)
   - Posterior 1/3 of the tongue: glossopharyngeal nerve (CN IX)
   - Posterior area of the tongue root and taste buds of the larynx and upper esophagus: vagus nerve (CN X)

Any lesion anterior to the terminal sulcus and foramen cecum, including this patient's oral ulcer, would be located on the **anterior** 2/3 of the tongue. **Pain** from this region (as well as sensations of touch, pressure, and temperature) is transmitted by the **mandibular branch of the trigeminal nerve**.

(Choices A, B, and E) The chorda tympani branch of the facial nerve (CN VII) transmits gustatory sensation from the anterior 2/3 of the tongue but not painful stimuli. The glossopharyngeal nerve (CN IX) transmits taste, pain, temperature, and touch stimuli from the posterior 1/3 of the tongue. The vagus nerve (CN X) innervates the far posterior area of the tongue root, transmitting both gustatory and general sensory stimuli.

(Choice D) The maxillary division of the trigeminal nerve (CN V_2) does not participate in tongue innervation.

Educational objective:
General sensation from the anterior 2/3 of the tongue is carried by the mandibular division of the trigeminal nerve. Gustatory innervation of the anterior 2/3 of the tongue is provided by the chorda tympani branch of the facial nerve.

Anatomy	Nervous System	Trigeminal nerve
Subject	System	Topic

Copyright © UWorld. All rights reserved.

1
2
3
4
5
6
7
8
9
10
11
12
13
14
15
16
17
18
19
20
21
22
23
24
25
26
27
28
29
30
31

A 72-year-old man is brought to the emergency department due to involuntary movements of his right arm that started several hours ago. He was watching television when his arm "threw the remote control across the room." His past medical history is significant for long-standing hypertension and diabetes mellitus. The patient does not use alcohol, tobacco, or illicit drugs. Physical examination shows wild, large-amplitude, flinging movements affecting the proximal muscles of his right arm. Which of the following areas of the brain is most likely injured in this patient?

A. Caudate nucleus
B. Internal capsule
C. Lentiform nucleus
D. Substantia nigra
E. Subthalamic nucleus
F. Ventral posterior thalamus

Submit

1
2
3
4
5
6
7
8
9
10
11
12
13
14
15
16
17
18
19
20
21
22
23
24
25
26
27
28
29
30
31

A 72-year-old man is brought to the emergency department due to involuntary movements of his right arm that started several hours ago. He was watching television when his arm "threw the remote control across the room." His past medical history is significant for long-standing hypertension and diabetes mellitus. The patient does not use alcohol, tobacco, or illicit drugs. Physical examination shows wild, large-amplitude, flinging movements affecting the proximal muscles of his right arm. Which of the following areas of the brain is most likely injured in this patient?

- A. Caudate nucleus (22%)
- B. Internal capsule (5%)
- C. Lentiform nucleus (3%)
- D. Substantia nigra (6%)
- ✓ E. Subthalamic nucleus (59%)
- F. Ventral posterior thalamus (2%)

Omitted
Correct answer
E

59%
Answered correctly

01 sec
Time Spent

03/07/2020
Last Updated

Explanation

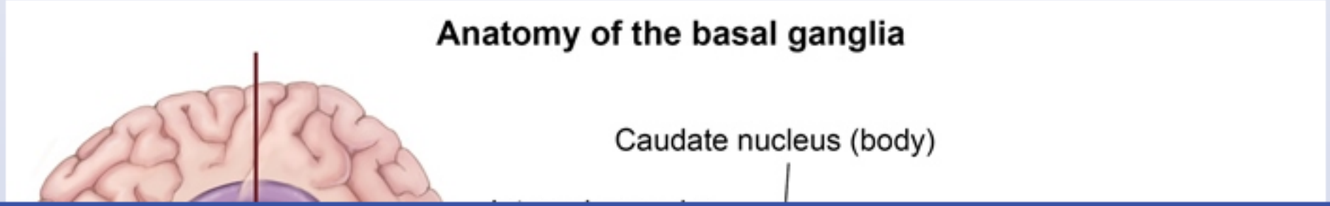

1
2
3
4
5
6
7
8
9
10
11
12
13
14
15
16
17
18
19
20
21
22
23
24
25
26
27
28
29
30
31

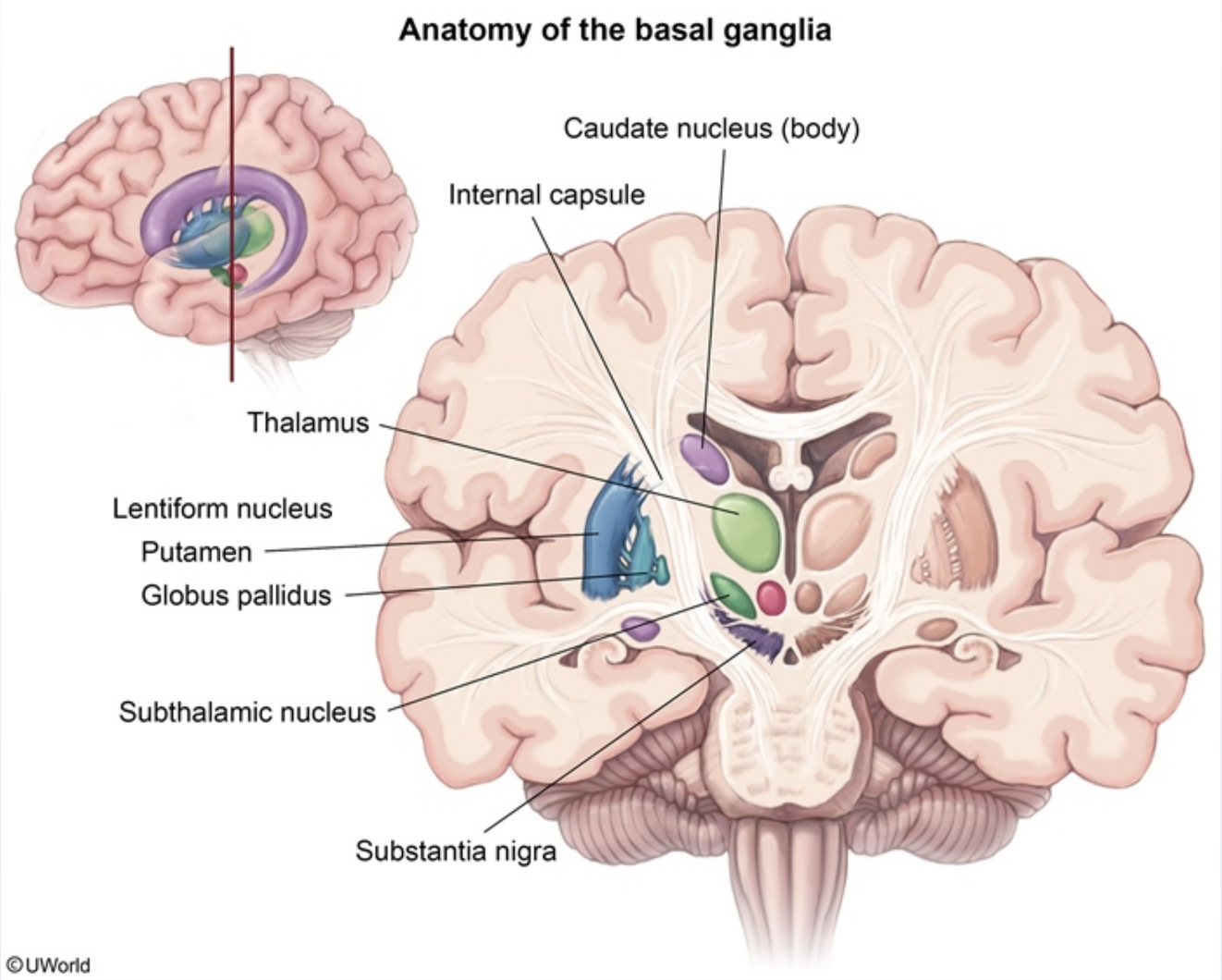

The **subthalamic nucleus** is a lens-shaped structure located ventral (inferior) to the thalamus, dorsal (superior) to the substantia nigra, and medial to the internal capsule. It is a component of the **basal ganglia** and plays an important role in the modulation of basal ganglia output.

©UWorld

The **subthalamic nucleus** is a lens-shaped structure located ventral (inferior) to the thalamus, dorsal (superior) to the substantia nigra, and medial to the internal capsule. It is a component of the **basal ganglia** and plays an important role in the modulation of basal ganglia output.

Damage to the subthalamic nucleus can decrease excitation of the globus pallidus internus, thereby reducing inhibition of the thalamus. This may result in contralateral **hemiballism**, a movement disorder characterized by wild, involuntary, large-amplitude, flinging movements involving the proximal limbs (eg, arm and/or leg) on one side of the body. This most commonly occurs in the setting of **lacunar stroke**, which is often a consequence of long-standing hypertension and diabetes mellitus.

(Choice A) Atrophy of the caudate nucleus occurs in Huntington disease, which is characterized by the insidious onset of chorea (involuntary, low-amplitude movements involving the distal limbs), dementia, and behavioral abnormalities.

(Choice B) Damage to the internal capsule may occur with lacunar infarcts, but patients typically have contralateral pure motor or combined sensorimotor deficits.

(Choice C) Atrophy of the lentiform nucleus (eg, globus pallidus and putamen) occurs in Wilson disease (hepatolenticular degeneration), which is characterized by liver (eg, hepatitis, cirrhosis), psychiatric (eg, depression, personality changes), and neurologic (eg, dysarthria, movement disorder) abnormalities.

(Choice D) Degeneration of the substantia nigra occurs in Parkinson disease, which is characterized by bradykinesia, rigidity, and resting tremor.

(Choice F) Lacunar stroke involving the ventral posterior lateral nucleus and ventral posterior medial nucleus of the thalamus typically results in complete contralateral sensory loss. Damage to the thalamus may also cause thalamic syndrome, characterized by contralateral burning or stabbing pain over one side of the body.

Educational objective:
The subthalamic nucleus plays an important role in the modulation of basal ganglia output. Damage to this structure (eg, due to lacunar stroke) may result in contralateral hemiballism, characterized by wild, involuntary, large-amplitude, flinging movements of the proximal limbs (eg, arm and/or leg) on one side of the body.

References

- Hemiballismus: current concepts and review.

consequence of long-standing hypertension and diabetes mellitus.

(Choice A) Atrophy of the caudate nucleus occurs in Huntington disease, which is characterized by the insidious onset of chorea (involuntary, low-amplitude movements involving the distal limbs), dementia, and behavioral abnormalities.

(Choice B) Damage to the internal capsule may occur with lacunar infarcts, but patients typically have contralateral pure motor or combined sensorimotor deficits.

(Choice C) Atrophy of the lentiform nucleus (eg, globus pallidus and putamen) occurs in Wilson disease (hepatolenticular degeneration), which is characterized by liver (eg, hepatitis, cirrhosis), psychiatric (eg, depression, personality changes), and neurologic (eg, dysarthria, movement disorder) abnormalities.

(Choice D) Degeneration of the substantia nigra occurs in Parkinson disease, which is characterized by bradykinesia, rigidity, and resting tremor.

(Choice F) Lacunar stroke involving the ventral posterior lateral nucleus and ventral posterior medial nucleus of the thalamus typically results in complete contralateral sensory loss. Damage to the thalamus may also cause thalamic syndrome, characterized by contralateral burning or stabbing pain over one side of the body.

Educational objective:
The subthalamic nucleus plays an important role in the modulation of basal ganglia output. Damage to this structure (eg, due to lacunar stroke) may result in contralateral hemiballism, characterized by wild, involuntary, large-amplitude, flinging movements of the proximal limbs (eg, arm and/or leg) on one side of the body.

References

- Hemiballismus: current concepts and review.
- The subthalamic nucleus in the context of movement disorders.

Anatomy	Nervous System	Hemiballismus
Subject	System	Topic

Copyright © UWorld. All rights reserved.

1
2
3
4
5
6
7
8
9
10
11
12
13
14
15
16
17
18
19
20
21
22
23
24
25
26
27
28
29
30
31

Exhibit Display

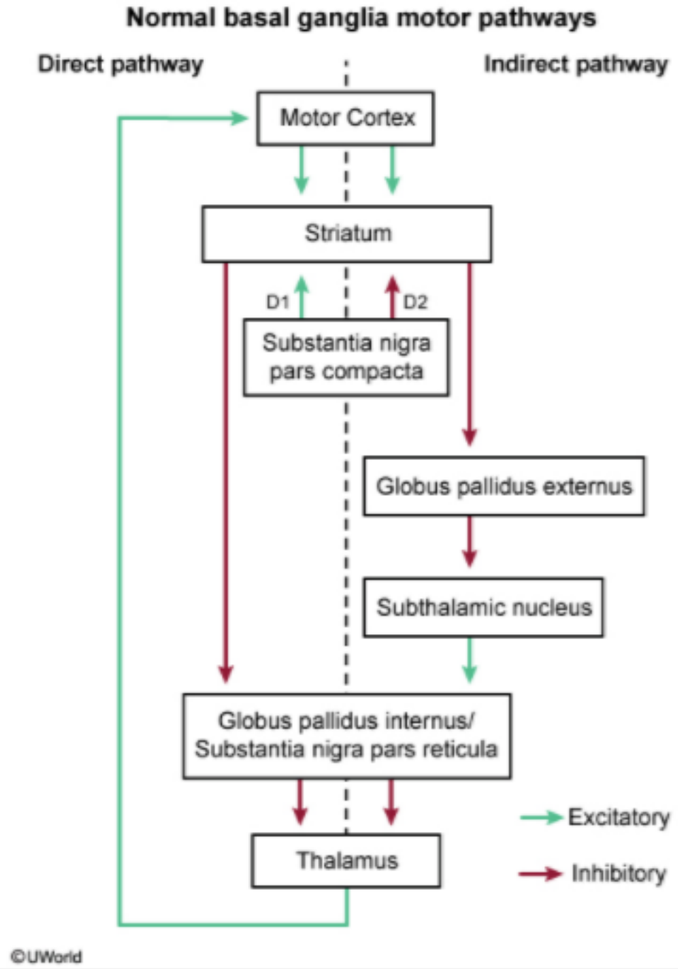

Zoom In | Zoom Out | Reset | Add To New Card | Existing Card

disorder) abnormalities

A 34-year-old man is evaluated in the clinic due to difficulty walking over the past 2 weeks. His symptoms have resulted in several recent falls, but he has had no head trauma or loss of consciousness. He has never had these symptoms before. The patient is frustrated as he cannot carry out his duties as a mailman. He has a history of crack cocaine use in the distant past but no current illicit drug use. The patient is in a monogamous relationship but previously had numerous sexual partners. The physician asks him to stand with his feet close together, arms to the sides, and eyes closed. This maneuver most likely tests for abnormalities in which of the following?

A. Cortical sensory integration

B. Gait

C. Motor coordination

D. Muscle strength

E. Proprioception

Submit

A 34-year-old man is evaluated in the clinic due to difficulty walking over the past 2 weeks. His symptoms have resulted in several recent falls, but he has had no head trauma or loss of consciousness. He has never had these symptoms before. The patient is frustrated as he cannot carry out his duties as a mailman. He has a history of crack cocaine use in the distant past but no current illicit drug use. The patient is in a monogamous relationship but previously had numerous sexual partners. The physician asks him to stand with his feet close together, arms to the sides, and eyes closed. This maneuver most likely tests for abnormalities in which of the following?

- A. Cortical sensory integration (9%)
- B. Gait (5%)
- C. Motor coordination (6%)
- D. Muscle strength (0%)
- ✓ E. Proprioception (77%)

Omitted
Correct answer
E

77%
Answered correctly

02 secs
Time Spent

02/12/2020
Last Updated

Explanation

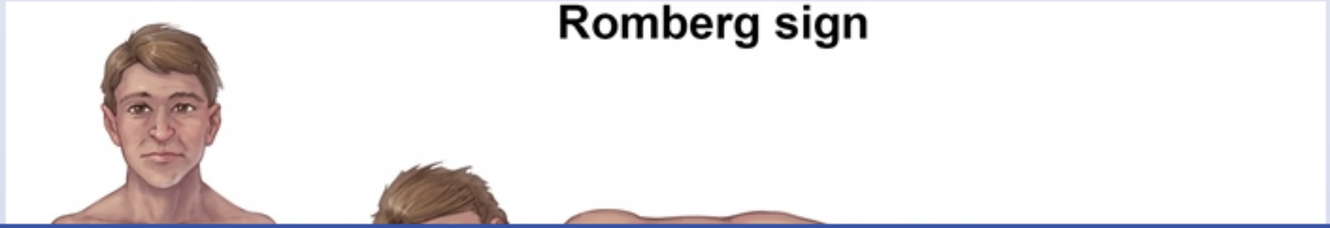

1
2
3
4
5
6
7
8
9
10
11
12
13
14
15
16
17
18
19
20
21
22
23
24
25
26
27
28
29
30
31

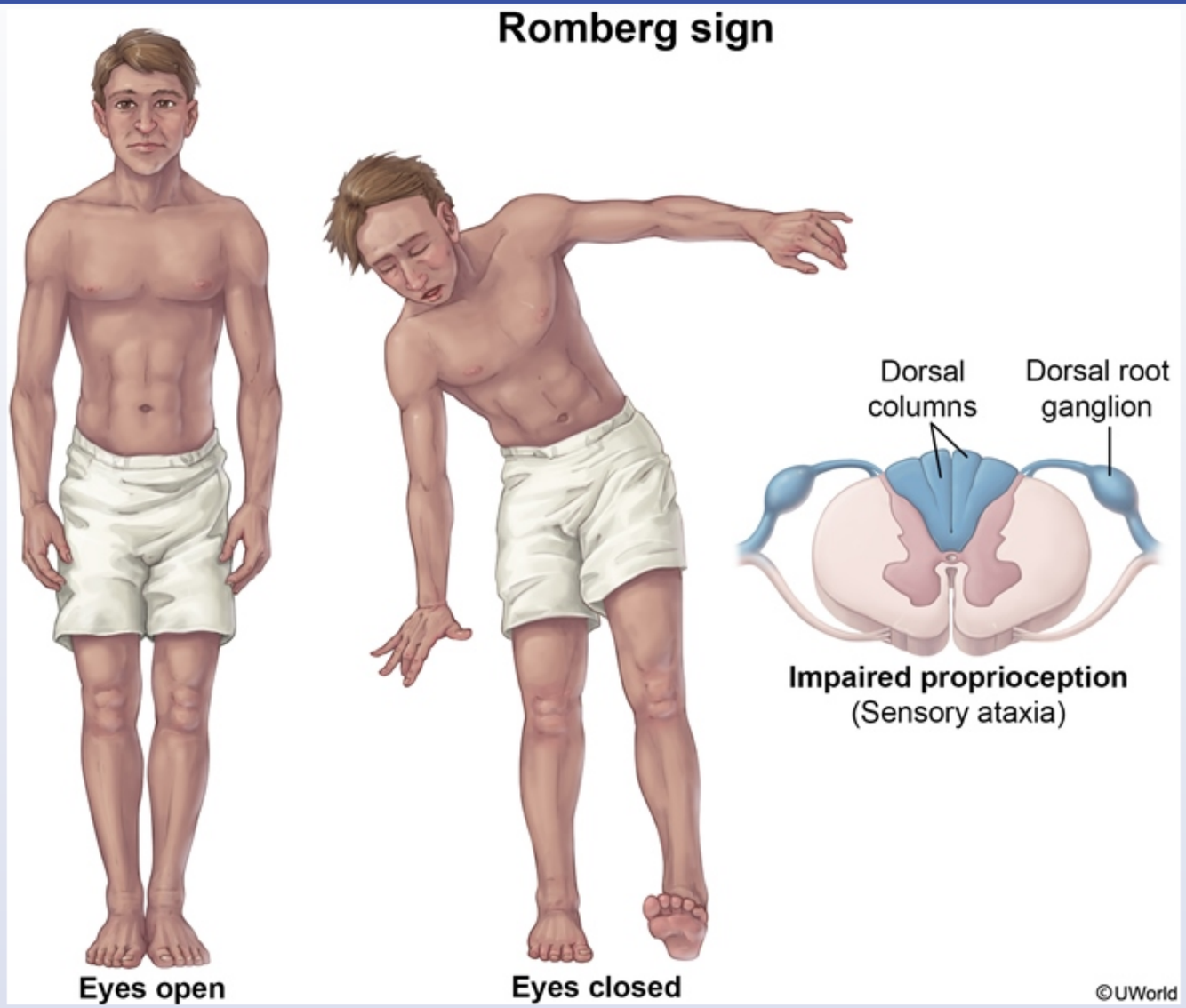

The **Romberg test** is a test of **proprioception** used to distinguish sensory from cerebellar ataxia. The maneuver is executed by first instructing the patient to stand with the feet close together, arms to the sides, and eyes open. During this time, the patient is observed for unsteadiness. If

The **Romberg test** is a test of **proprioception** used to distinguish sensory from cerebellar ataxia. The maneuver is executed by first instructing the patient to stand with the feet close together, arms to the sides, and eyes open. During this time, the patient is observed for unsteadiness. If the patient is unable to maintain this stance easily, some form of ataxia (cerebellar or sensory) is likely present.

To differentiate sensory from cerebellar ataxia, the patient is asked to close the eyes while maintaining the aforementioned posture. Removing the visual input forces the patient to rely on input from proprioceptive receptors in the trunk and extremities for posture maintenance. Failure to maintain this posture with the eyes closed is referred to as a positive Romberg sign and indicates **sensory ataxia**. Sensory ataxia may be caused by defects in the **posterior column** or **peripheral nerves**, which are classically caused by tabes dorsalis (syphilis) or vitamin B_{12} deficiency.

Patients who show little or no change in their unsteadiness with their eyes closed (negative Romberg sign) likely have cerebellar ataxia due to impaired motor coordination. Cerebellar function/motor coordination is typically evaluated with rapid alternating movements, finger-to-nose testing, and heel-to-shin testing **(Choice C)**.

(Choice A) The parietal association cortex is an area that integrates multisensory (eg, visual, tactile, verbal) information to comprehend events and generate responses. Lesions in the nondominant hemisphere typically cause contralateral neglect, anosognosia (lack of awareness of illness), and constructional apraxia (inability to draw objects). Patients are tested by being asked to draw a clock or bisect a horizontal line.

(Choice B) Gait is tested by observing the patient walk casually, in tandem, on the heels, and on the toes. The patient should be assessed for speed, stride length, step height, and arm swing.

(Choice D) Muscle strength is tested directly by having the patient press or pull against resistance. Muscle strength is graded on a scale of 0-5 (0=no contraction, 3=contraction able to overcome gravity, 5=normal).

Educational objective:
The Romberg test is a test of proprioception in which patients are observed for unsteadiness as they stand with their feet close together, arms to the sides, and eyes closed. Failure to maintain this posture indicates sensory ataxia, which may be caused by defects in the posterior column or peripheral nerves (eg, tabes dorsalis, vitamin B_{12} deficiency).

References

- Romberg's test.

To differentiate sensory from cerebellar ataxia, the patient is asked to close the eyes while maintaining the aforementioned posture. Removing the visual input forces the patient to rely on input from proprioceptive receptors in the trunk and extremities for posture maintenance. Failure to maintain this posture with the eyes closed is referred to as a positive Romberg sign and indicates **sensory ataxia**. Sensory ataxia may be caused by defects in the **posterior column** or **peripheral nerves**, which are classically caused by tabes dorsalis (syphilis) or vitamin B_{12} deficiency.

Patients who show little or no change in their unsteadiness with their eyes closed (negative Romberg sign) likely have cerebellar ataxia due to impaired motor coordination. Cerebellar function/motor coordination is typically evaluated with rapid alternating movements, finger-to-nose testing, and heel-to-shin testing **(Choice C)**.

(Choice A) The parietal association cortex is an area that integrates multisensory (eg, visual, tactile, verbal) information to comprehend events and generate responses. Lesions in the nondominant hemisphere typically cause contralateral neglect, anosognosia (lack of awareness of illness), and constructional apraxia (inability to draw objects). Patients are tested by being asked to draw a clock or bisect a horizontal line.

(Choice B) Gait is tested by observing the patient walk casually, in tandem, on the heels, and on the toes. The patient should be assessed for speed, stride length, step height, and arm swing.

(Choice D) Muscle strength is tested directly by having the patient press or pull against resistance. Muscle strength is graded on a scale of 0-5 (0=no contraction, 3=contraction able to overcome gravity, 5=normal).

Educational objective:
The Romberg test is a test of proprioception in which patients are observed for unsteadiness as they stand with their feet close together, arms to the sides, and eyes closed. Failure to maintain this posture indicates sensory ataxia, which may be caused by defects in the posterior column or peripheral nerves (eg, tabes dorsalis, vitamin B_{12} deficiency).

References

- Romberg's test.

Anatomy	Nervous System	Peripheral neuropathy
Subject	System	Topic

Copyright © UWorld. All rights reserved.

A 10-minute-old boy is being evaluated in the delivery room. The patient was born at term to a 30-year-old primigravida woman. Pregnancy was unremarkable, but labor was complicated by recurrent late decelerations necessitating vacuum assistance for vaginal delivery. Apgar scores were 6 and 8 at 1 and 5 minutes, respectively. Temperature is 37 C (98.6 F), pulse is 170/min, and respirations are 40/min. Scalp examination shows large, fluctuant swelling at the occiput that extends bilaterally to the ears, superiorly toward the crown, and inferiorly into the nape of the neck. This patient's hemorrhage is most likely located between which of the following structures?

A. Arachnoid mater and dura mater

B. Brain and arachnoid mater

C. Dura mater and periosteum

D. Periosteum and galea aponeurosis

E. Skull and the periosteum

Submit

A 10-minute-old boy is being evaluated in the delivery room. The patient was born at term to a 30-year-old primigravida woman. Pregnancy was unremarkable, but labor was complicated by recurrent late decelerations necessitating vacuum assistance for vaginal delivery. Apgar scores were 6 and 8 at 1 and 5 minutes, respectively. Temperature is 37 C (98.6 F), pulse is 170/min, and respirations are 40/min. Scalp examination shows large, fluctuant swelling at the occiput that extends bilaterally to the ears, superiorly toward the crown, and inferiorly into the nape of the neck. This patient's hemorrhage is most likely located between which of the following structures?

- A. Arachnoid mater and dura mater (23%)
- B. Brain and arachnoid mater (9%)
- C. Dura mater and periosteum (19%)
- ✓ D. Periosteum and galea aponeurosis (30%)
- E. Skull and the periosteum (16%)

Omitted
Correct answer
D

30%
Answered correctly

01 sec
Time Spent

03/19/2020
Last Updated

Explanation

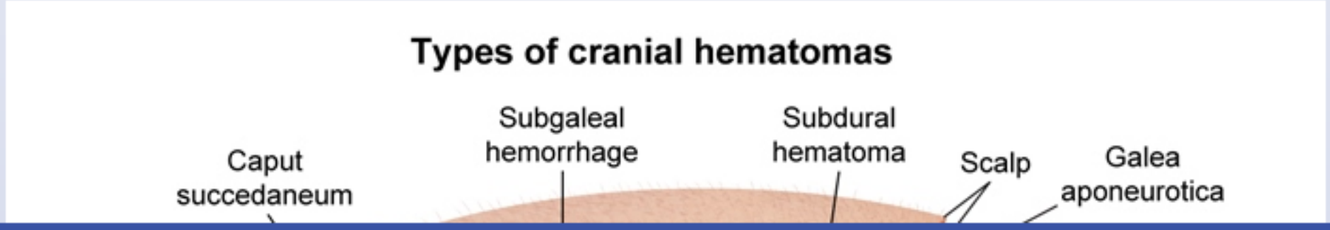

1
2
3
4
5
6
7
8
9
10
11
12
13
14
15
16
17
18
19
20
21
22
23
24
25
26
27
28
29
30
31

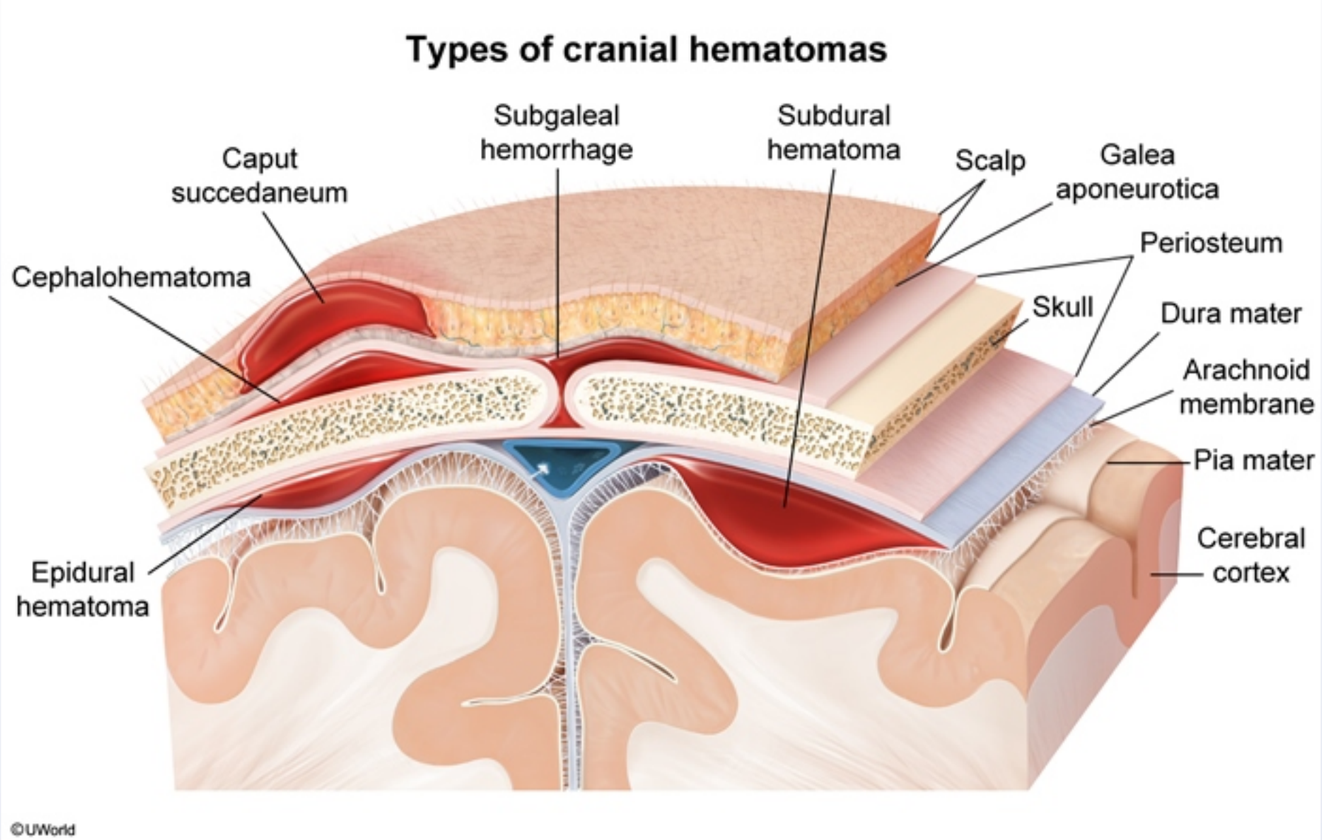

This newborn has diffuse, fluctuant swelling across the scalp and into the neck, findings concerning for a **subgaleal hemorrhage**.

Subgaleal hemorrhage is a rare, neonatal extracranial head injury caused by damage to the **emissary veins**, typically from **traction** on the scalp during vacuum-assisted delivery. Shearing of these veins, which connect veins of the scalp to the meningeal veins and dural sinuses, leads to hemorrhage in the potential space between the **periosteum** and **galea aponeurosis** (subgaleal space).

This potential space extends over the whole calvaria and into the neck. Therefore, **massive blood accumulation** (eg, 20%-40% of neonatal blood volume) can occur. Physical examination typically shows **diffuse**, **fluctuant scalp swelling** that extends **beyond suture lines** and potentially into the neck. The swelling may shift with movement and can continue to expand over 2-3 days. Progressive bleeding can lead to

©UWorld

This newborn has diffuse, fluctuant swelling across the scalp and into the neck, findings concerning for a **subgaleal hemorrhage**.

Subgaleal hemorrhage is a rare, neonatal extracranial head injury caused by damage to the **emissary veins**, typically from **traction** on the scalp during vacuum-assisted delivery. Shearing of these veins, which connect veins of the scalp to the meningeal veins and dural sinuses, leads to hemorrhage in the potential space between the **periosteum** and **galea aponeurosis** (subgaleal space).

This potential space extends over the whole calvaria and into the neck. Therefore, **massive blood accumulation** (eg, 20%-40% of neonatal blood volume) can occur. Physical examination typically shows **diffuse**, **fluctuant scalp swelling** that extends **beyond suture lines** and potentially into the neck. The swelling may shift with movement and can continue to expand over 2-3 days. Progressive bleeding can lead to hypovolemia, shock, and death, making prompt recognition critical.

(Choices A, B, and C) Neonatal intracranial bleeds are also associated with assisted deliveries. Subarachnoid hemorrhage develops between the brain and arachnoid mater; subdural hematoma occurs between the arachnoid mater and dura mater; and epidural hematoma occurs between the dura mater and periosteum. Symptomatic intracranial bleeds typically present with seizures or hemodynamic instability, not diffuse scalp fluctuance.

(Choice E) Bleeding between the skull and periosteum results in a cephalohematoma, which usually presents as a small area of swelling over the parietal or occipital bone. Because the periosteum is fixed at suture lines (eg, sagittal, coronal), the firm, nonfluctuant swelling of a cephalohematoma does not cross suture lines and spread over the calvaria.

Educational objective:
Subgaleal hemorrhage is a potentially fatal neonatal bleed that occurs during delivery when emissary veins between the dural sinuses and scalp are sheared. The accumulation of blood between the periosteum and galea aponeurosis presents with a diffuse, progressive, fluctuant scalp and neck swelling; massive blood loss can lead to shock and death if not promptly recognized.

References

- Neurological neonatal birth injuries: a literature review.

Anatomy	Nervous System	Scalp hematomas
Subject	System	Topic

Subgaleal hemorrhage is a rare, neonatal extracranial head injury caused by damage to the **emissary veins**, typically from **traction** on the scalp during vacuum-assisted delivery. Shearing of these veins, which connect veins of the scalp to the meningeal veins and dural sinuses, leads to hemorrhage in the potential space between the **periosteum** and **galea aponeurosis** (subgaleal space).

This potential space extends over the whole calvaria and into the neck. Therefore, **massive blood accumulation** (eg, 20%-40% of neonatal blood volume) can occur. Physical examination typically shows **diffuse**, **fluctuant scalp swelling** that extends **beyond suture lines** and potentially into the neck. The swelling may shift with movement and can continue to expand over 2-3 days. Progressive bleeding can lead to hypovolemia, shock, and death, making prompt recognition critical.

(Choices A, B, and C) Neonatal intracranial bleeds are also associated with assisted deliveries. Subarachnoid hemorrhage develops between the brain and arachnoid mater; subdural hematoma occurs between the arachnoid mater and dura mater; and epidural hematoma occurs between the dura mater and periosteum. Symptomatic intracranial bleeds typically present with seizures or hemodynamic instability, not diffuse scalp fluctuance.

(Choice E) Bleeding between the skull and periosteum results in a cephalohematoma, which usually presents as a small area of swelling over the parietal or occipital bone. Because the periosteum is fixed at suture lines (eg, sagittal, coronal), the firm, nonfluctuant swelling of a cephalohematoma does not cross suture lines and spread over the calvaria.

Educational objective:
Subgaleal hemorrhage is a potentially fatal neonatal bleed that occurs during delivery when emissary veins between the dural sinuses and scalp are sheared. The accumulation of blood between the periosteum and galea aponeurosis presents with a diffuse, progressive, fluctuant scalp and neck swelling; massive blood loss can lead to shock and death if not promptly recognized.

References

- Neurological neonatal birth injuries: a literature review.

Anatomy	Nervous System	Scalp hematomas
Subject	System	Topic

Copyright © UWorld. All rights reserved.

Subgaleal hemorrhage is a rare, neonatal extracranial head injury caused by damage to the **emissary veins**, typically from **traction** on the scalp

Exhibit Display

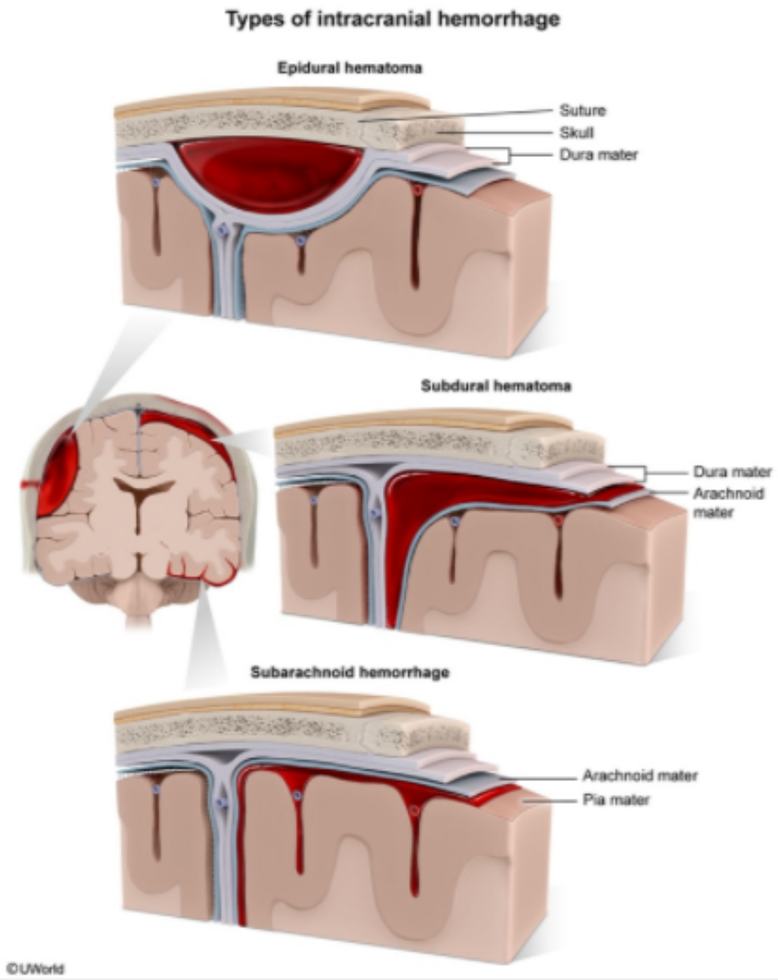

Zoom In Zoom Out Reset Add To Flash Card

1
2
3
4
5
6
7
8
9
10
11
12
13
14
15
16
17
18
19
20
21
22
23
24
25
26
27
28
29
30
31

A 25-year-old man fractures his right tibia in a motor vehicle accident. His right leg is fixed in a cast and he requires underarm crutches to ambulate. Two weeks later, he comes to the clinic with right upper-extremity weakness and numbness. He has no neck or arm pain. The patient is concerned because he is right handed and cannot perform his duties as an electrician. On neurologic examination, there is diminished strength on extension of the right wrist with an absent triceps reflex. Injury to which of the following nerves is most likely responsible for this patient's symptoms?

A. Accessory
B. Axillary
C. Long thoracic
D. Median
E. Radial
F. Suprascapular

Submit

A 25-year-old man fractures his right tibia in a motor vehicle accident. His right leg is fixed in a cast and he requires underarm crutches to ambulate. Two weeks later, he comes to the clinic with right upper-extremity weakness and numbness. He has no neck or arm pain. The patient is concerned because he is right handed and cannot perform his duties as an electrician. On neurologic examination, there is diminished strength on extension of the right wrist with an absent triceps reflex. Injury to which of the following nerves is most likely responsible for this patient's symptoms?

- A. Accessory (0%)
- B. Axillary (12%)
- C. Long thoracic (0%)
- D. Median (3%)
- ✓ E. Radial (81%)
- F. Suprascapular (0%)

Omitted
Correct answer
E

81%
Answered correctly

02 secs
Time Spent

04/14/2020
Last Updated

Explanation

Radial nerve
(posterior view)

1
2
3
4
5
6
7
8
9
10
11
12
13
14
15
16
17
18
19
20
21
22
23
24
25
26
27
28
29
30
31

Radial nerve
(posterior view)

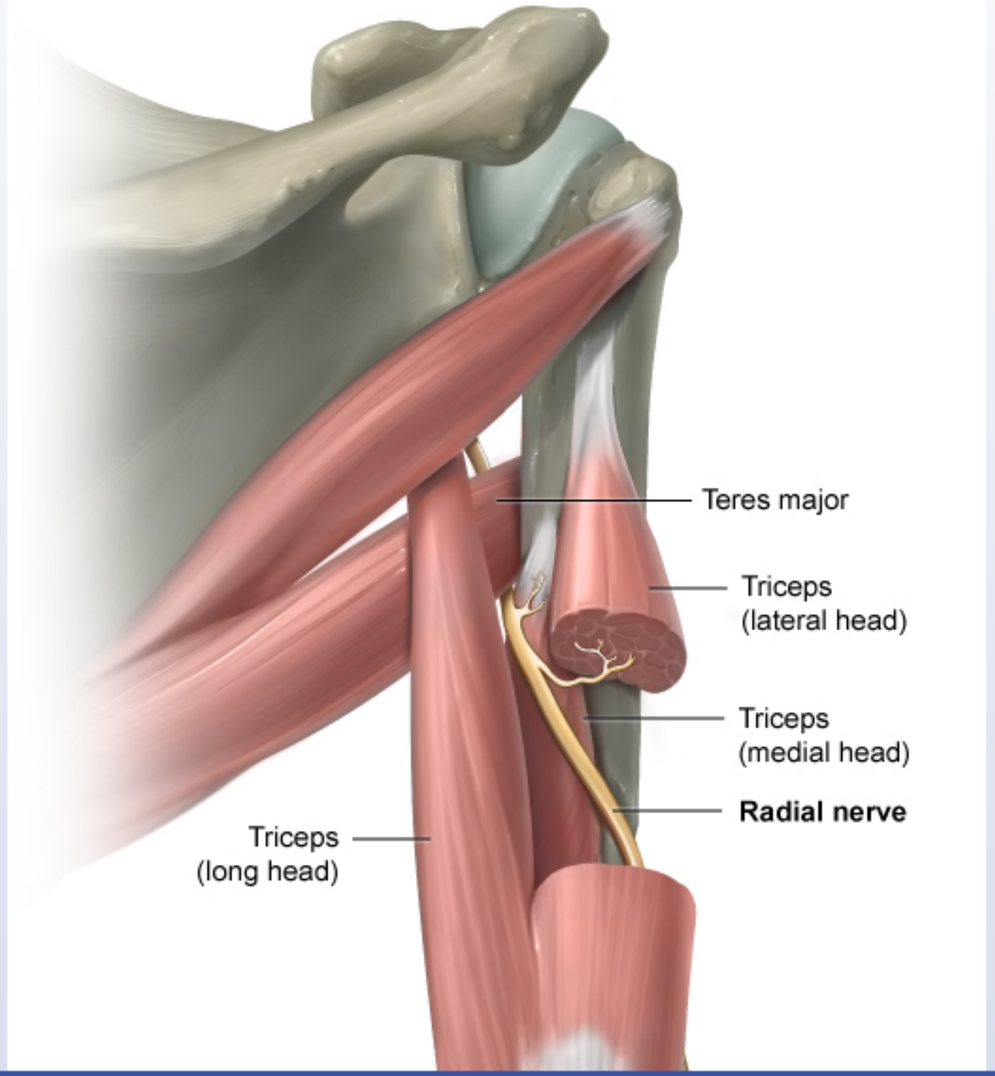

1
2
3
4
5
6
7
8
9
10
11
12
13
14
15
16
17
18
19
20
21
22
23
24
25
26
27
28
29
30
31

©UWorld

The radial nerve is derived from the C5-T1 spinal nerves and is one of the two final branches of the posterior cord of the brachial plexus. The nerve initially courses medial to the surgical neck of the humerus inferior to the teres major muscle within the axilla before entering the posterior arm to course between the long head of the triceps brachii and the posterior humerus.

Proximal radial nerve injury can occur at the nerve's superficial location within the axilla by repetitive pressure/trauma caused by an ill-fitting crutch ("**crutch palsy**") or if an individual sleeps with the arm over a chair ("Saturday night palsy"). Injury to the nerve at this location may cause weakness or paralysis of the forearm, hand, and finger **extensor muscles** (eg, wrist drop, absent triceps reflex). Sensory loss may also be observed over the radial nerve distribution. Injuries to the proximal radial nerve as it crosses the posterior humerus (eg, midshaft humeral fractures) spare the triceps brachii, as the fibers innervating this muscle leave the nerve before it enters the radial groove.

(Choice A) The spinal accessory nerve (CN XI) exits the skull through the jugular foramen and courses over the levator scapulae muscle to innervate the sternocleidomastoid and trapezius muscles.

(Choice B) Fracture of the surgical neck of the humerus and anterior dislocation of the glenohumeral joint can cause injury to the axillary nerve. The resultant paralysis of the deltoid and teres minor muscles causes weakness on arm abduction. Sensory loss over the deltoid may also be evident.

The radial nerve is derived from the C5-T1 spinal nerves and is one of the two final branches of the posterior cord of the brachial plexus. The nerve initially courses medial to the surgical neck of the humerus inferior to the teres major muscle within the axilla before entering the posterior arm to course between the long head of the triceps brachii and the posterior humerus.

Proximal radial nerve injury can occur at the nerve's superficial location within the axilla by repetitive pressure/trauma caused by an ill-fitting crutch ("**crutch palsy**") or if an individual sleeps with the arm over a chair ("Saturday night palsy"). Injury to the nerve at this location may cause weakness or paralysis of the forearm, hand, and finger **extensor muscles** (eg, wrist drop, absent triceps reflex). Sensory loss may also be observed over the radial nerve distribution. Injuries to the proximal radial nerve as it crosses the posterior humerus (eg, midshaft humeral fractures) spare the triceps brachii, as the fibers innervating this muscle leave the nerve before it enters the radial groove.

(Choice A) The spinal accessory nerve (CN XI) exits the skull through the jugular foramen and courses over the levator scapulae muscle to innervate the sternocleidomastoid and trapezius muscles.

(Choice B) Fracture of the surgical neck of the humerus and anterior dislocation of the glenohumeral joint can cause injury to the axillary nerve. The resultant paralysis of the deltoid and teres minor muscles causes weakness on arm abduction. Sensory loss over the deltoid may also be evident.

(Choice C) Damage to the long thoracic nerve causes paralysis of the serratus anterior muscle and winging of the scapula. This nerve is often injured during lymph node dissection in patients undergoing radical mastectomy.

(Choice D) Proximal median nerve injury often occurs with supracondylar humerus fractures. This results in sensory loss over the palmar aspect of the first 3 digits and impairment of thumb flexion/opposition, flexion of the second/third digits, and wrist flexion/abduction.

(Choice F) The suprascapular nerve innervates the supraspinatus and infraspinatus muscles. These muscles function to abduct and laterally rotate the arm, respectively.

Educational objective:
Radial nerve injury can occur with repetitive pressure/trauma at the axilla (eg, improperly fitted crutches). Findings include weakness of the forearm, hand, and fingers extensors (eg, wrist drop, absent triceps reflex) and sensory loss over the posterior arm and forearm, dorsolateral hand, and dorsal thumb. More distal lesions spare the triceps brachii.

References

- Clinical features of wrist drop caused by compressive radial neuropathy and its anatomical considerations

fractures) spare the triceps brachii, as the fibers innervating this muscle leave the nerve before it enters the radial groove.

(Choice A) The spinal accessory nerve (CN XI) exits the skull through the jugular foramen and courses over the levator scapulae muscle to innervate the sternocleidomastoid and trapezius muscles.

(Choice B) Fracture of the surgical neck of the humerus and anterior dislocation of the glenohumeral joint can cause injury to the axillary nerve. The resultant paralysis of the deltoid and teres minor muscles causes weakness on arm abduction. Sensory loss over the deltoid may also be evident.

(Choice C) Damage to the long thoracic nerve causes paralysis of the serratus anterior muscle and winging of the scapula. This nerve is often injured during lymph node dissection in patients undergoing radical mastectomy.

(Choice D) Proximal median nerve injury often occurs with supracondylar humerus fractures. This results in sensory loss over the palmar aspect of the first 3 digits and impairment of thumb flexion/opposition, flexion of the second/third digits, and wrist flexion/abduction.

(Choice F) The suprascapular nerve innervates the supraspinatus and infraspinatus muscles. These muscles function to abduct and laterally rotate the arm, respectively.

Educational objective:
Radial nerve injury can occur with repetitive pressure/trauma at the axilla (eg, improperly fitted crutches). Findings include weakness of the forearm, hand, and fingers extensors (eg, wrist drop, absent triceps reflex) and sensory loss over the posterior arm and forearm, dorsolateral hand, and dorsal thumb. More distal lesions spare the triceps brachii.

References

- Clinical features of wrist drop caused by compressive radial neuropathy and its anatomical considerations.
- Anatomical, clinical, and electrodiagnostic features of radial neuropathies.

Anatomy	Nervous System	Radial neuropathy
Subject	System	Topic

Copyright © UWorld. All rights reserved.

1
2
3
4
5
6
7
8
9
10
11
12
13
14
15
16
17
18
19
20
21
22
23
24
25
26
27
28
29
30
31

Exhibit Display

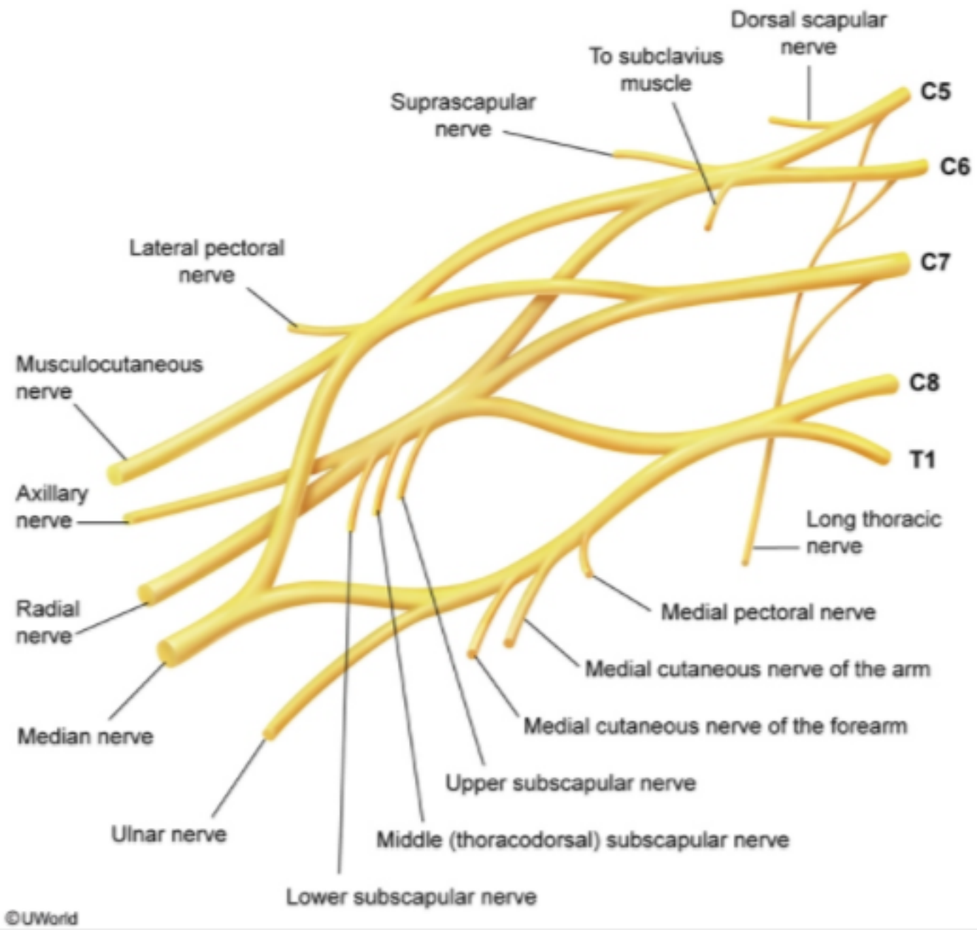

Zoom In | Zoom Out | Reset | Add To New Card | Existing Card

innervate the sternocleidomastoid and trapezius muscles.

Lateral

Exhibit Display

Important nerves in the arm

Nerve	Motor function	Region of sensory loss with neuropathy
Radial nerve	Extension at all arm, wrist, & finger joints below the shoulder, forearm supination, thumb abduction in plane of palm	

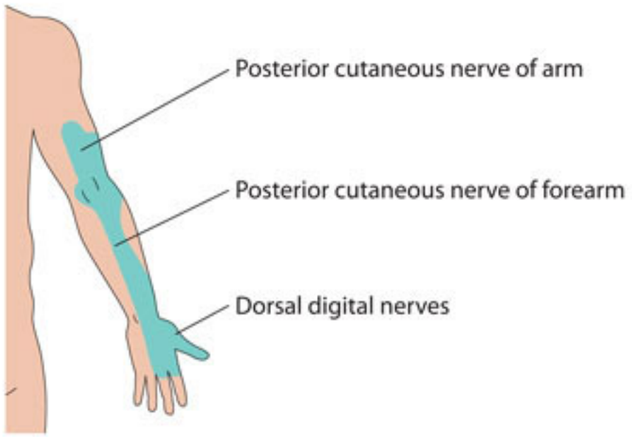

©UWorld

Zoom In
Zoom Out
Reset
Add To New Card | Existing Card

Educational objective:

fractures) spare the triceps brachii, as the fibers innervating this muscle leave the nerve before it enters the radial groove.

(Choice A) The spinal accessory nerve (CN XI) exits the skull through the jugular foramen and courses over the levator scapulae muscle to innervate the sternocleidomastoid and trapezius muscles.

(Choice B) Fracture of the surgical neck of the humerus and anterior dislocation of the glenohumeral joint can cause injury to the axillary nerve. The resultant paralysis of the deltoid and teres minor muscles causes weakness on arm abduction. Sensory loss over the deltoid may also be evident.

(Choice C) Damage to the long thoracic nerve causes paralysis of the serratus anterior muscle and winging of the scapula. This nerve is often injured during lymph node dissection in patients undergoing radical mastectomy.

(Choice D) Proximal median nerve injury often occurs with supracondylar humerus fractures. This results in sensory loss over the palmar aspect of the first 3 digits and impairment of thumb flexion/opposition, flexion of the second/third digits, and wrist flexion/abduction.

(Choice F) The suprascapular nerve innervates the supraspinatus and infraspinatus muscles. These muscles function to abduct and laterally rotate the arm, respectively.

Educational objective:
Radial nerve injury can occur with repetitive pressure/trauma at the axilla (eg, improperly fitted crutches). Findings include weakness of the forearm, hand, and fingers extensors (eg, wrist drop, absent triceps reflex) and sensory loss over the posterior arm and forearm, dorsolateral hand, and dorsal thumb. More distal lesions spare the triceps brachii.

References

- Clinical features of wrist drop caused by compressive radial neuropathy and its anatomical considerations.
- Anatomical, clinical, and electrodiagnostic features of radial neuropathies.

Anatomy	Nervous System	Radial neuropathy
Subject	System	Topic

Copyright © UWorld. All rights reserved.

The following vignette applies to the next **2** items. The items in the set must be answered in sequential order. Once you click **Proceed to Next Item**, you will not be able to add or change an answer.

A 62-year-old woman comes to the emergency department due to difficulty walking that started 3 hours ago. The patient cannot feel the right side of her body. She has a history of hypertension and diabetes mellitus. She has smoked a pack of cigarettes daily for the past 30 years. The patient's father had a myocardial infarction at age 60. Physical examination shows loss of touch, temperature, and vibratory sensation affecting the right upper and lower extremities. Sensation is also diminished over the right side of the face. Muscle strength is 5/5 throughout.

Item 1 of 2

This patient has most likely suffered a stroke affecting which of the following brain structures?

- A. Base of the pons
- B. Caudate nucleus
- C. Frontal cortex
- D. Posterior limb of the internal capsule
- E. Ventral posterior thalamus

Submit

The following vignette applies to the next **2** items. The items in the set must be answered in sequential order. Once you click **Proceed to Next Item**, you will not be able to add or change an answer.

A 62-year-old woman comes to the emergency department due to difficulty walking that started 3 hours ago. The patient cannot feel the right side of her body. She has a history of hypertension and diabetes mellitus. She has smoked a pack of cigarettes daily for the past 30 years. The patient's father had a myocardial infarction at age 60. Physical examination shows loss of touch, temperature, and vibratory sensation affecting the right upper and lower extremities. Sensation is also diminished over the right side of the face. Muscle strength is 5/5 throughout.

Item 1 of 2

This patient has most likely suffered a stroke affecting which of the following brain structures?

- A. Base of the pons (11%)
- B. Caudate nucleus (3%)
- C. Frontal cortex (5%)
- D. Posterior limb of the internal capsule (28%)
- ✓ E. Ventral posterior thalamus (50%)

Omitted
Correct answer
E

50%
Answered correctly

02 secs
Time Spent

06/10/2020
Last Updated

Explanation

Explanation

This patient with right-sided pure hemisensory loss has likely suffered from a **thalamic stroke**. The thalamic **ventral posterior lateral nucleus** (receives input from the spinothalamic tract and dorsal columns) and **ventral posterior medial nucleus** (receives input from the trigeminal pathway) send somatosensory projections to the cortex via thalamocortical fibers. Damage to these nuclei (eg, due to ischemia, hemorrhage) may result in **complete contralateral sensory loss** (eg, touch, pain/temperature, vibration/proprioception). Severe proprioceptive defects may cause **unsteady gait**.

(Choice A) Injury to the base of the pons is frequently associated with contralateral weakness and ataxia due to involvement of the descending motor tracts (eg, corticospinal, corticobulbar) and pontocerebellar fibers.

(Choice B) Damage to the caudate nucleus typically causes behavioral abnormalities (eg, agitation, psychosis, abulia), speech/language disturbances, and movement disorders (eg, choreoathetosis).

(Choice C) Frontal cortex lesions usually cause social disinhibition and deficits in attention and executive function (eg, planning, organizing, decision making).

(Choice D) The anterior two-thirds of the posterior limb of the internal capsule is mainly composed of motor fibers (eg, corticospinal tract), and the posterior one-third contains sensory fibers (eg, thalamocortical tract). Although very small lesions to the posterior limb may cause contralateral pure sensory deficits, most lesions result in pure motor or combined sensorimotor deficits.

Educational objective:
The ventral posterior lateral nucleus (receives input from the spinothalamic tract and dorsal columns) and ventral posterior medial nucleus (receives input from the trigeminal pathway) of the thalamus send somatosensory projections to the cortex via thalamocortical fibers. Damage to these nuclei results in complete contralateral sensory loss.

References

- Pure sensory stroke. Clinical-radiological correlates of 21 cases.

Anatomy	Nervous System	Ischemic stroke
Subject	System	Topic

1
2
3
4
5
6
7
8
9
10
11
12
13
14
15
16
17
18
19
20
21
22
23
24
25
26
27
28
29
30
31

Explanation

This patient with right-sided pure hemisensory loss has likely suffered from a **thalam**
(receives input from the spinothala
pathway) send somatosensory pro
may result in **complete contralateral sensory loss** (eg, touch, pain/temperature, vi
cause **unsteady gait**.

Highlight | Add To New Card | Add

(Choice A) Injury to the base of the pons is frequently associated with contralateral
motor tracts (eg, corticospinal, corticobulbar) and pontocerebellar fibers.

(Choice B) Damage to the caudate nucleus typically causes behavioral abnormaliti
disturbances, and movement disorders (eg, choreoathetosis).

(Choice C) Frontal cortex lesions usually cause social disinhibition and deficits in a
decision making).

(Choice D) The anterior two-thirds of the posterior limb of the internal capsule is ma
posterior one-third contains sensory fibers (eg, thalamocortical tract). Although very
pure sensory deficits, most lesions result in pure motor or combined sensorimotor de

Educational objective:
The ventral posterior lateral nucleus (receives input from the spinothalamic tract anc
(receives input from the trigeminal pathway) of the thalamus send somatosensory pr
these nuclei results in complete contralateral sensory loss.

References

- Pure sensory stroke. Clinical-radiological correlates of 21 cases.

Anatomy	Nervous System	Ischemic stroke
Subject	System	Topic

Exhibit Display

Zoom In | Zoom Out | Reset | Add To New

Explanation

Exhibit Display

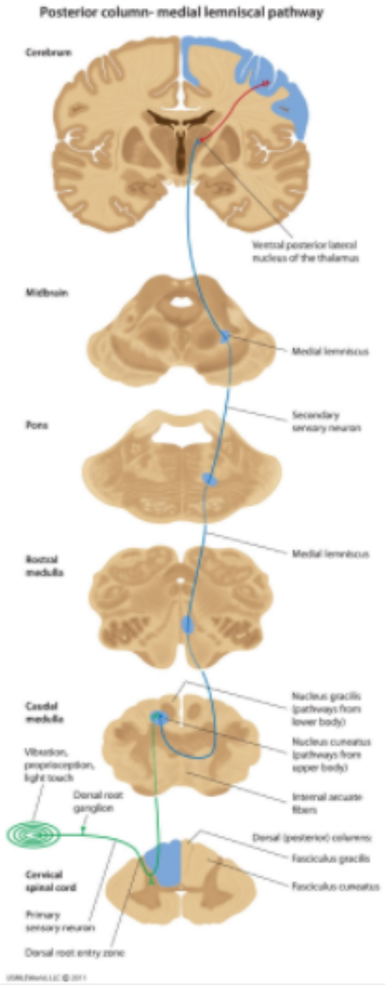

Zoom In | Zoom Out | Reset | Add To New Card | Existing Card

1
2
3
4
5
6
7
8
9
10
11
12
13
14
15
16
17
18
19
20
21
22
23
24
25
26
27
28
29
30
31

Item 2 of 2

The patient was diagnosed with a pure sensory stroke and received the appropriate treatment. Her symptoms improved and she returned home to live with her daughter after a few weeks of physical rehabilitation. Five years later, the patient dies of a large myocardial infarction. On autopsy, there are two 5- to 6-mm cavities in the deep structures of her brain filled with clear fluid. Which of the following processes was most likely responsible for the patient's brain findings?

A. Autoimmune demyelination

B. Embolic carotid atherosclerosis

C. Embolic mitral valve disease

D. Lipohyalinosis with small vessel occlusion

E. Malignant cell infiltration

Submit

Item 2 of 2

The patient was diagnosed with a pure sensory stroke and received the appropriate treatment. Her symptoms improved and she returned home to live with her daughter after a few weeks of physical rehabilitation. Five years later, the patient dies of a large myocardial infarction. On autopsy, there are two 5- to 6-mm cavities in the deep structures of her brain filled with clear fluid. Which of the following processes was most likely responsible for the patient's brain findings?

- A. Autoimmune demyelination (3%)
- B. Embolic carotid atherosclerosis (23%)
- C. Embolic mitral valve disease (7%)
- ✓ D. Lipohyalinosis with small vessel occlusion (62%)
- E. Malignant cell infiltration (3%)

Omitted
Correct answer
D

62%
Answered correctly

02 secs
Time Spent

06/10/2020
Last Updated

Explanation

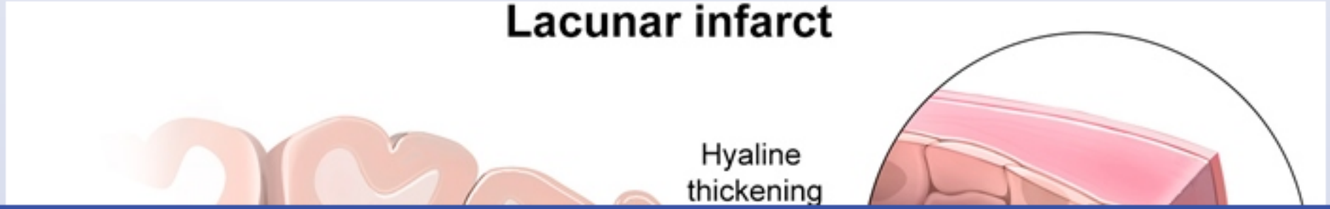

1
2
3
4
5
6
7
8
9
10
11
12
13
14
15
16
17
18
19
20
21
22
23
24
25
26
27
28
29
30
31

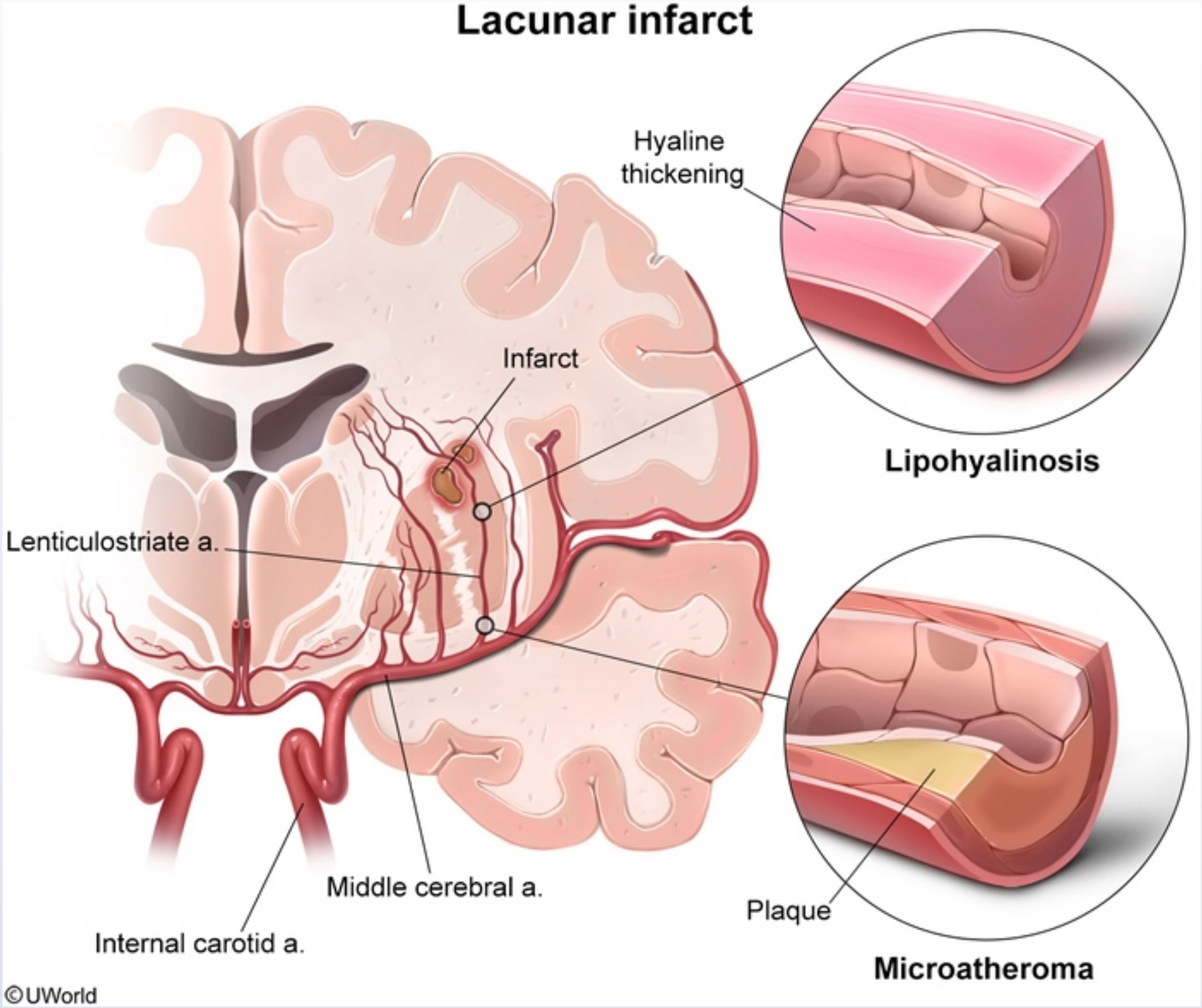

Lacunes are small (<15 mm) cavitary infarcts located within the basal ganglia, posterior limb of the internal capsule, pons, and cerebellum. The

Lacunes are small (<15 mm) cavitary infarcts located within the basal ganglia, posterior limb of the internal capsule, pons, and cerebellum. The infarcts result from occlusion of the **small penetrating arteries** that supply these deep brain structures (eg, lenticulostriate arteries), most commonly in the setting of chronic uncontrolled **hypertension** or **diabetes mellitus**.

Lipohyalinosis and microatheromas are believed to be the primary causes of lacunar infarcts. **Lipohyalinosis** occurs secondary to leakage of plasma proteins through damaged endothelium and is characterized by hyaline thickening of the vascular wall, collagenous sclerosis, and accumulation of mural foamy macrophages. **Microatheromas** result from atherosclerotic accumulation of lipid-laden macrophages within the intimal layer of a penetrating artery near its origin off the parent vessel. These changes predispose to small-vessel **occlusion** and infarction of central nervous system (CNS) tissue with **liquefactive necrosis** and the formation of a fluid-filled cavity.

(Choice A) Multiple sclerosis is an autoimmune demyelinating disease of the CNS. The CNS lesions in multiple sclerosis do not form cavities; instead, they appear grossly as pink patches in the white matter tracts.

(Choices B and C) Embolism due to carotid atherosclerosis and mitral valve disease (eg, bacterial endocarditis) most commonly causes cortical infarcts. Although microemboli released from atherosclerotic lesions or valvular disease may be the cause of some lacunar infarcts, lipohyalinosis/microatheromas are a much more common etiology.

(Choice E) Malignant neoplasms tend to cause space-occupying lesions rather than small cavities. The center of a large tumor may cavitate due to insufficient perfusion, with resultant necrosis and hemorrhage.

Educational objective:
Lacunar infarctions are the result of small vessel occlusion (eg, due to lipohyalinosis and microatheroma formation) in the penetrating vessels supplying the deep brain structures. Uncontrolled hypertension and diabetes mellitus are major risk factors for this condition.

References

- Lacunar infarction and small vessel disease: pathology and pathophysiology.

Anatomy	Nervous System	Ischemic stroke
Subject	System	Topic

Copyright © UWorld. All rights reserved.

1
2
3
4
5
6
7
8
9
10
11
12
13
14
15
16
17
18
19
20
21
22
23
24
25
26
27
28
29
30
31

A 34-year-old woman is evaluated for several months of moderate hearing loss. She has also noticed a ringing in her left ear. The patient has had no recent ear infections or cold symptoms, does not use cotton ear swabs, and has no history of head trauma. Her father has bilateral hearing loss attributed to old age. On physical examination, the auditory canals are patent and tympanic membranes appear gray with a well-visualized light reflex. Hearing is diminished on the left side. Neurologic examination shows left-sided facial numbness, an asymmetric smile, and diminished corneal reflex response in the left eye. This patient's condition suggests an intracranial mass in which of the following locations?

A. Above the sellar diaphragm

B. Adjacent to the sagittal sinus

C. Between the cerebellum and lateral pons

D. In the dorsal midbrain

E. Over the lateral cerebral convexity

Submit

1
2
3
4
5
6
7
8
9
10
11
12
13
14
15
16
17
18
19
20
21
22
23
24
25
26
27
28
29
30
31

A 34-year-old woman is evaluated for several months of moderate hearing loss. She has also noticed a ringing in her left ear. The patient has had no recent ear infections or cold symptoms, does not use cotton ear swabs, and has no history of head trauma. Her father has bilateral hearing loss attributed to old age. On physical examination, the auditory canals are patent and tympanic membranes appear gray with a well-visualized light reflex. Hearing is diminished on the left side. Neurologic examination shows left-sided facial numbness, an asymmetric smile, and diminished corneal reflex response in the left eye. This patient's condition suggests an intracranial mass in which of the following locations?

A. Above the sellar diaphragm (2%)

B. Adjacent to the sagittal sinus (4%)

✓ C. Between the cerebellum and lateral pons (78%)

D. In the dorsal midbrain (9%)

E. Over the lateral cerebral convexity (4%)

Omitted
Correct answer
C

78%
Answered correctly

03 secs
Time Spent

02/10/2020
Last Updated

Explanation

Cerebellopontine angle with vestibular schwannoma

1
2
3
4
5
6
7
8
9
10
11
12
13
14
15
16
17
18
19
20
21
22
23
24
25
26
27
28
29
30
31

Cerebellopontine angle with vestibular schwannoma

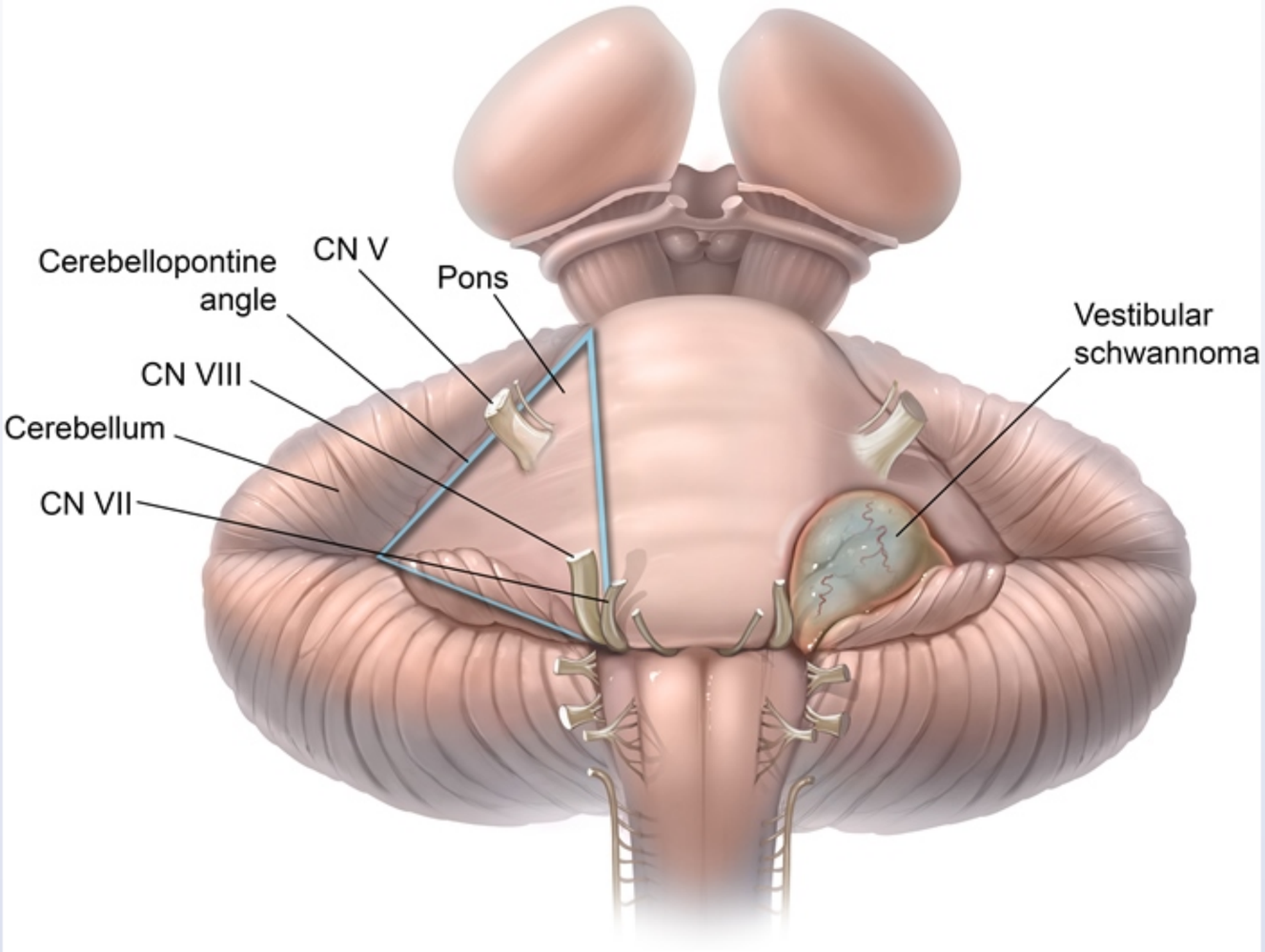

©UWorld

Anterior view

This patient's unilateral hearing loss with associated facial numbness and weakness, is highly suggestive of a **vestibular schwannoma**, the most

This patient's unilateral hearing loss with associated facial numbness and weakness, is highly suggestive of a **vestibular schwannoma**, the most common cause of cerebellopontine angle (ie, between the cerebellum and lateral pons) tumors in adults. Vestibular schwannomas most often arise from the vestibular portion of the vestibulocochlear nerve (CN VIII). Spontaneous vestibular schwannomas are usually unilateral, whereas bilateral vestibular schwannomas are associated with neurofibromatosis type 2.

The facial nerve (CN VII) and trigeminal nerve (CN V) are in proximity to CN VIII at the cerebellopontine angle and may be compressed by vestibular schwannomas. Symptoms can vary based on the pattern of nerve involvement:

- Impairment of the cochlear portion of CN VIII leads to ipsilateral **sensorineural hearing loss** and **tinnitus** (ringing in the ear), and damage to the vestibular portion causes unsteadiness and **disequilibrium**.
- Compression of CN V may cause loss of ipsilateral facial sensation with interruption of the afferent limb of the corneal reflex.
- CN VII compression can result in ipsilateral facial muscle paralysis (eg, asymmetric smile).

(Choice A) Craniopharyngiomas arise from remnants of Rathke's pouch and are typically located in the suprasellar region. Patients usually have hypothalamic or pituitary dysfunction and changes in vision due to disruption of the optic chiasm (eg, bitemporal hemianopia), none of which are evident in this patient.

(Choices B and E) Meningiomas are most commonly found in the falcine/parasagittal region or over the convexities of the cerebral hemispheres. Most are discovered incidentally, but some patients may have seizures, headaches, or focal neurologic deficits. This patient's findings are localized to CN V, CN VII, and CN VIII, making vestibular schwannoma more likely.

(Choice D) Germ cell tumors frequently arise from the pineal gland in the dorsal midbrain. Pineal tumors can cause obstructive hydrocephalus with symptoms of increased intracranial pressure (eg, headache, vomiting, altered mental status) and Parinaud syndrome (eg, upward gaze palsy).

Educational objective:
Vestibular schwannomas arise from the vestibulocochlear nerve (CN VIII) and are usually located at the cerebellopontine angle. These tumors can cause a range of symptoms by damaging the vestibulocochlear nerve (unsteadiness and ipsilateral sensorineural hearing loss with tinnitus), trigeminal nerve (ipsilateral facial paresthesia and diminished corneal reflex), and facial nerve (ipsilateral facial paresis). Bilateral acoustic neuromas are associated with neurofibromatosis type 2.

1
2
3
4
5
6
7
8
9
10
11
12
13
14
15
16
17
18
19
20
21
22
23
24
25
26
27
28
29
30
31

Exhibit Display

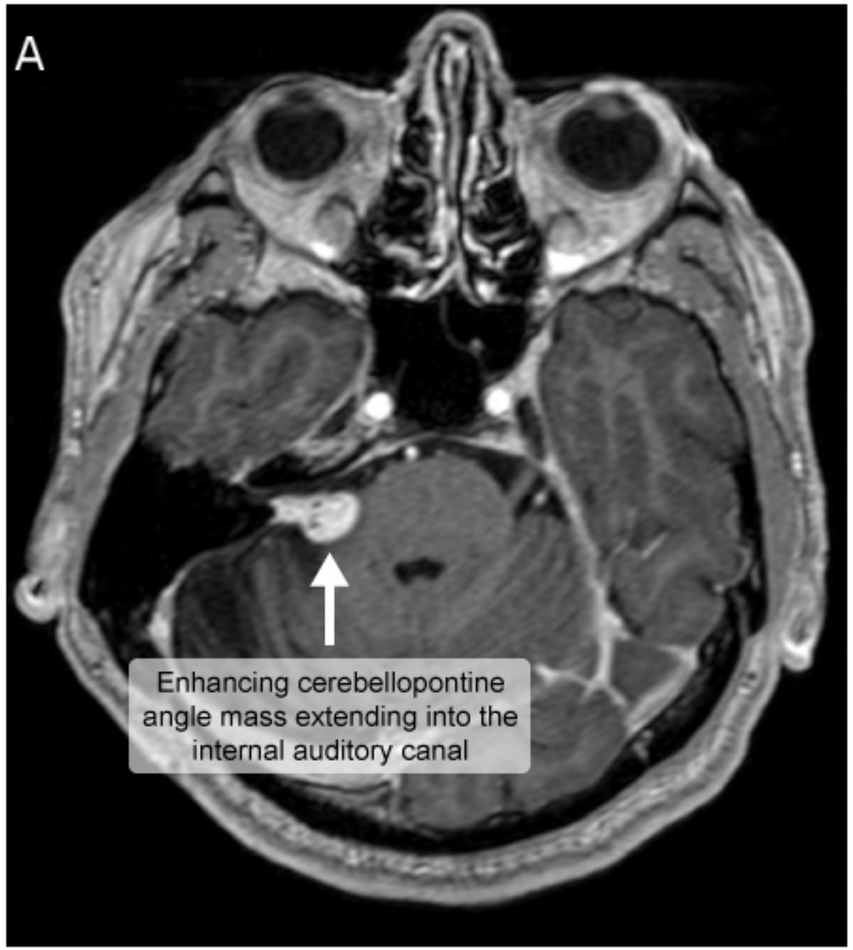

Zoom In | Zoom Out | Reset | Add To New Card | Existing Card

neuromas are associated with neurofibromatosis type 2

1
2
3
4
5
6
7
8
9
10
11
12
13
14
15
16
17
18
19
20
21
22
23
24
25
26
27
28
29
30
31

Exhibit Display

Meningioma Para-falcine meningioma

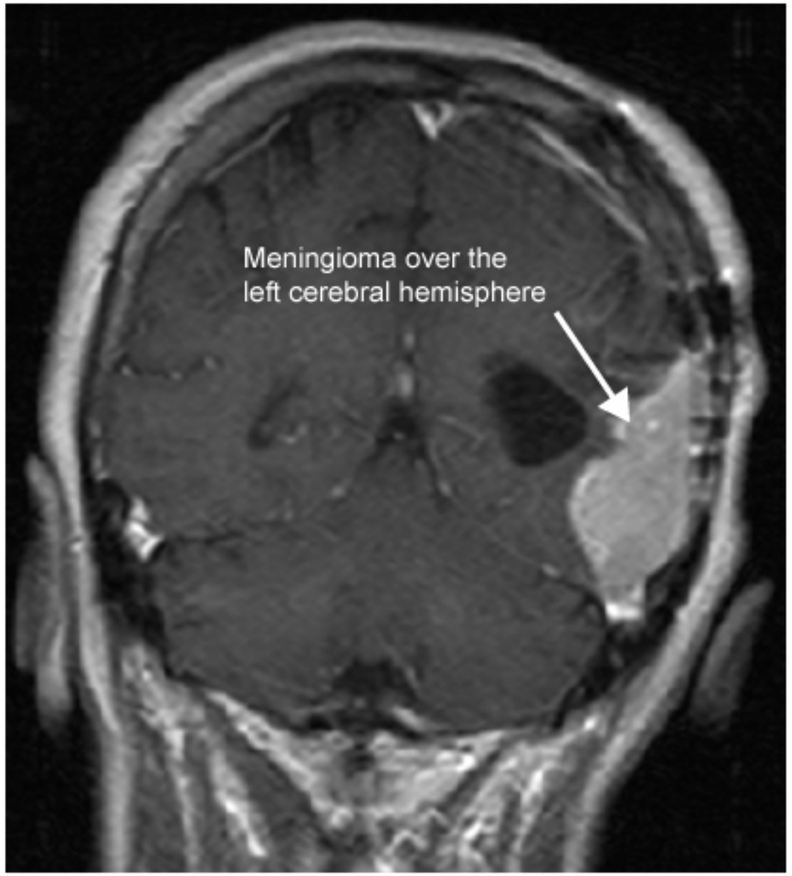

Zoom In Zoom Out Reset Add To New Card | Existing Card

neuromas are associated with neurofibromatosis type 2

1
2
3
4
5
6
7
8
9
10
11
12
13
14
15
16
17
18
19
20
21
22
23
24
25
26
27
28
29
30
31

Exhibit Display

Meningioma Para-falcine meningioma

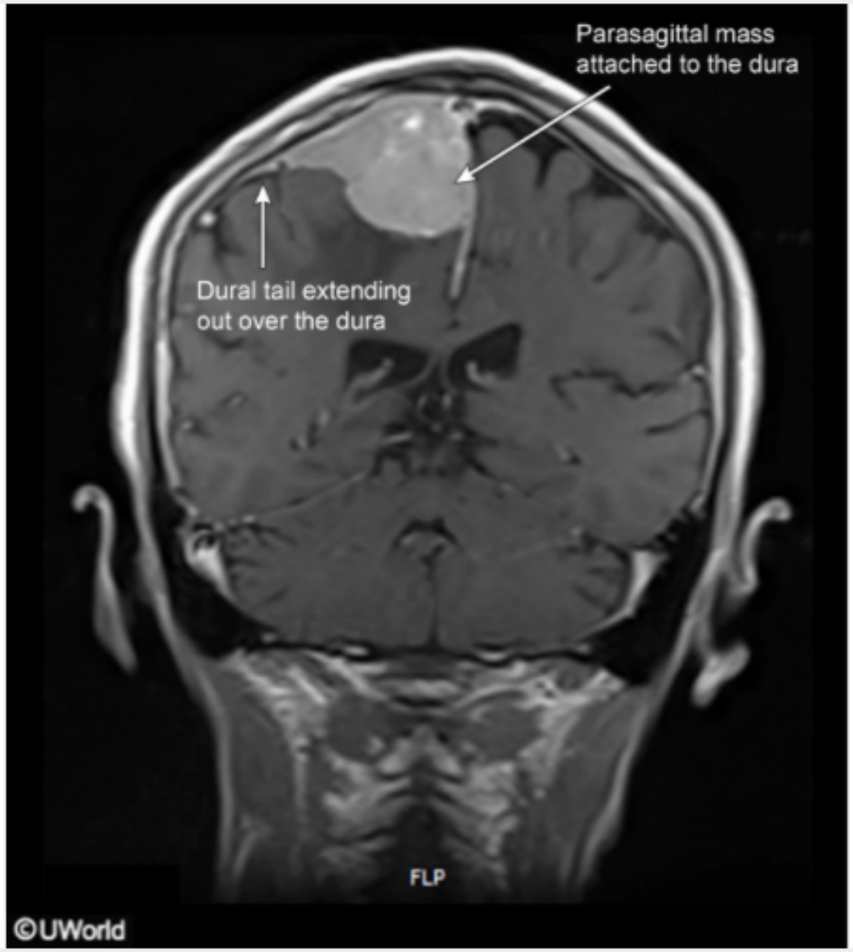

Zoom In Zoom Out Reset Add To New Card | Existing Card

neuromas are associated with neurofibromatosis type 2

1
2
3
4
5
6
7
8
9
10
11
12
13
14
15
16
17
18
19
20
21
22
23
24
25
26
27
28
29
30
31

Exhibit Display

Meningioma Para-falcine meningioma

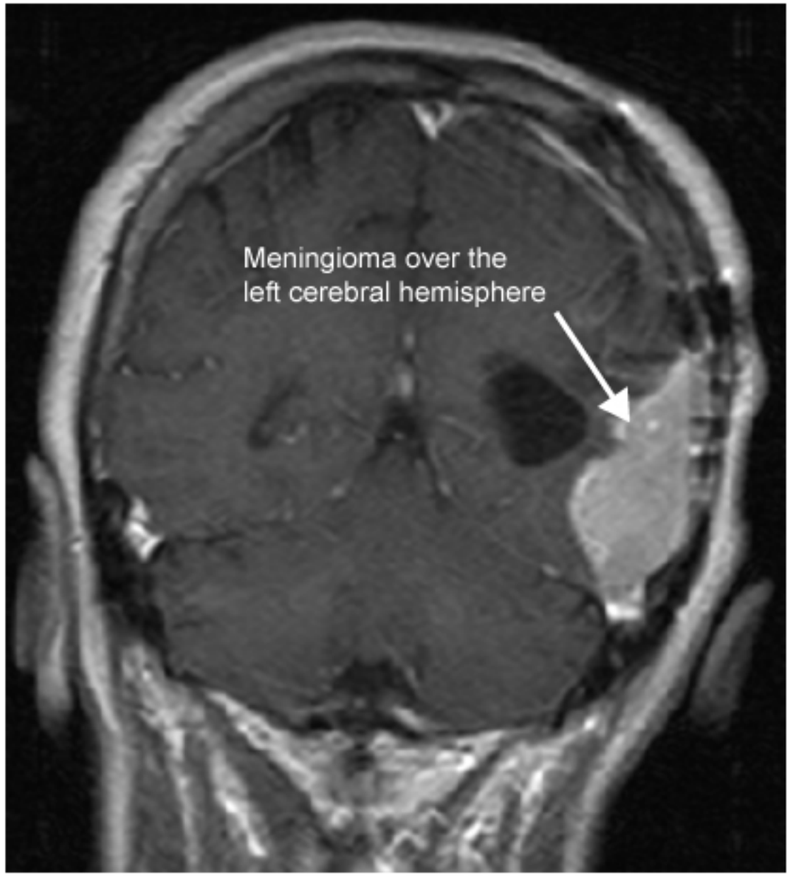

Zoom In Zoom Out Reset Add To New Card | Existing Card

neuromas are associated with neurofibromatosis type 2

1
2
3
4
5
6
7
8
9
10
11
12
13
14
15
16
17
18
19
20
21
22
23
24
25
26
27
28
29
30
31

Exhibit Display

Meningioma Para-falcine meningioma

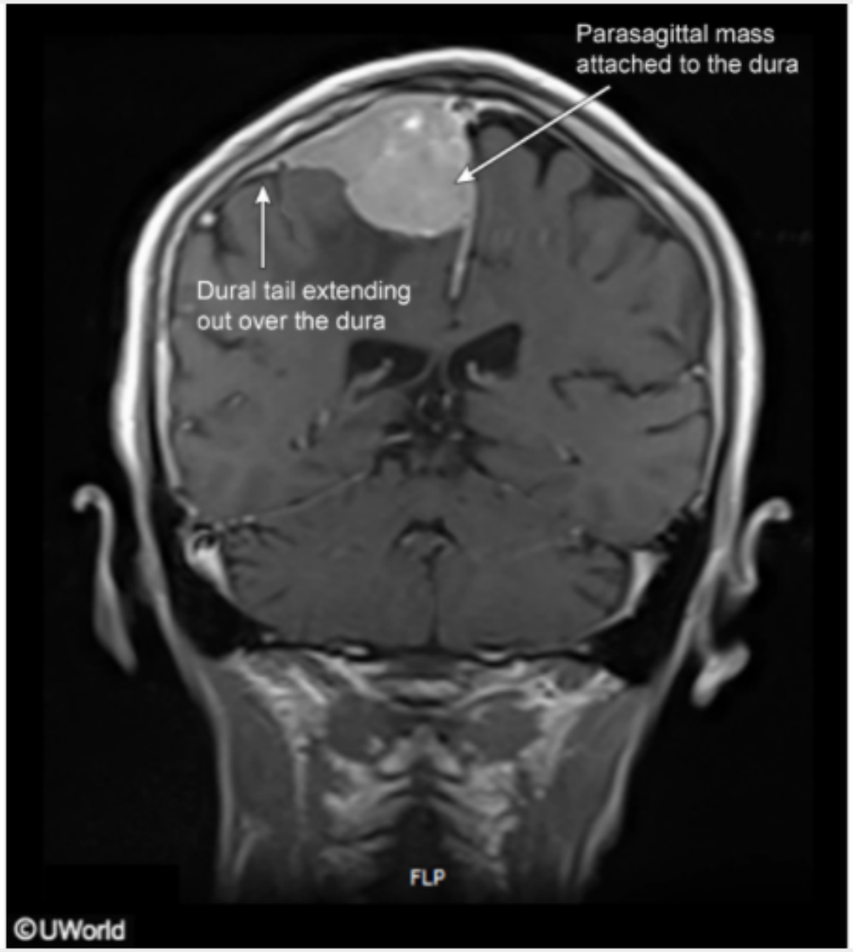

Zoom In Zoom Out Reset Add To New Card | Existing Card

neuromas are associated with neurofibromatosis type 2

1
2
3
4
5
6
7
8
9
10
11
12
13
14
15
16
17
18
19
20
21
22
23
24
25
26
27
28
29
30
31

Exhibit Display

Median brain

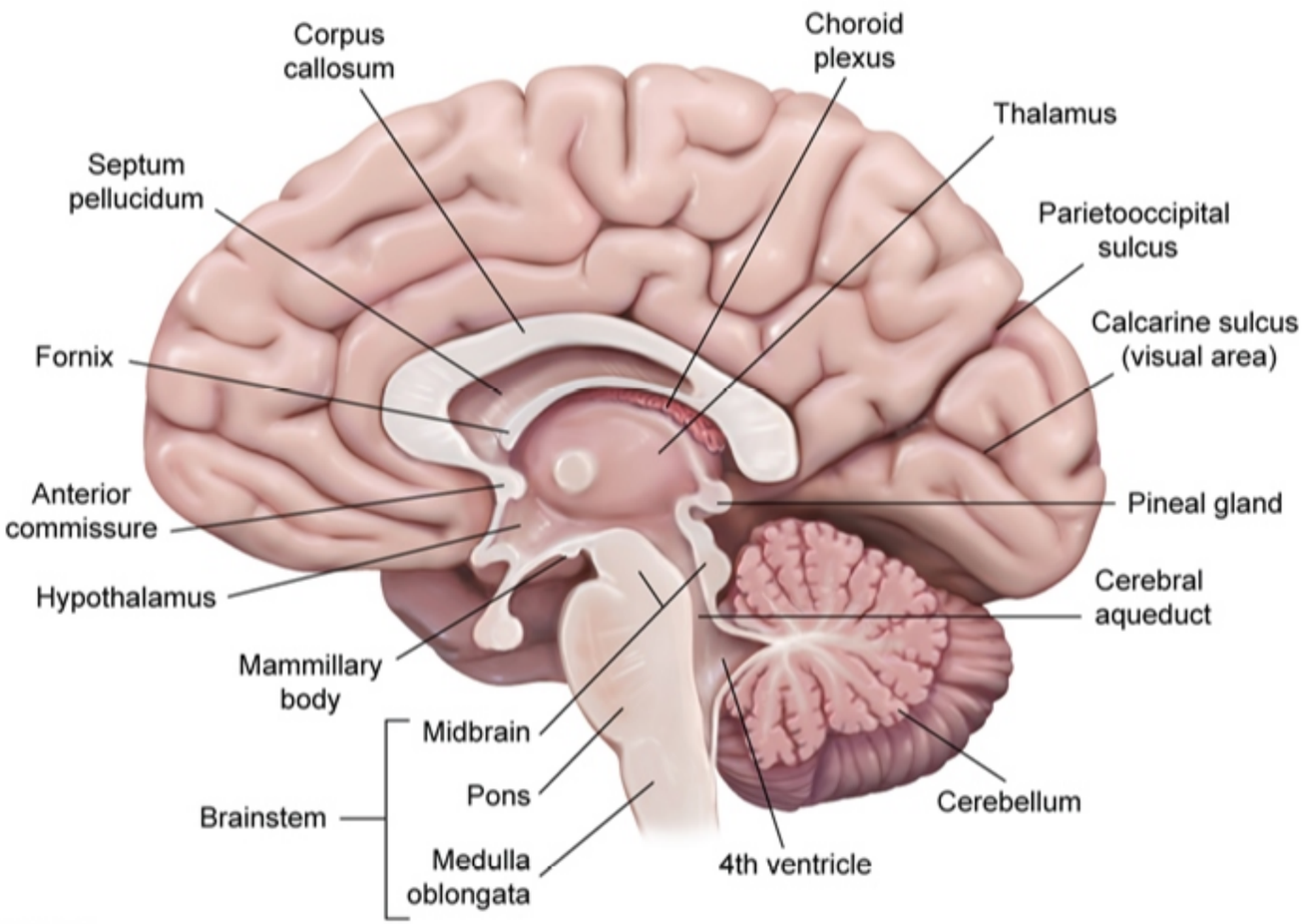

Zoom In | Zoom Out | Reset | Add To New Card | Existing Card

neuromas are associated with neurofibromatosis type 2

1
2
3
4
5
6
7
8
9
10
11
12
13
14
15
16
17
18
19
20
21
22
23
24
25
26
27
28
29
30
31

A 59-year-old man comes to the office due to diplopia and a drooping right eyelid. His symptoms began a day earlier and have since worsened. Physical examination shows a dilated right pupil that is nonreactive to both light and accommodation. There is vertical and horizontal diplopia. When the patient is asked to stare straight ahead, the right eye is directed inferiorly and laterally with respect to the left eye. MRI of the brain reveals an aneurysm involving the right posterior communicating artery. Which of the following muscles is most likely to remain functionally intact in this patient?

A. Inferior oblique
B. Inferior rectus
C. Lateral rectus
D. Levator palpebrae
E. Medial rectus
F. Superior rectus

Submit

A 59-year-old man comes to the office due to diplopia and a drooping right eyelid. His symptoms began a day earlier and have since worsened. Physical examination shows a dilated right pupil that is nonreactive to both light and accommodation. There is vertical and horizontal diplopia. When the patient is asked to stare straight ahead, the right eye is directed inferiorly and laterally with respect to the left eye. MRI of the brain reveals an aneurysm involving the right posterior communicating artery. Which of the following muscles is most likely to remain functionally intact in this patient?

- A. Inferior oblique (5%)
- B. Inferior rectus (1%)
- ✓ C. Lateral rectus (86%)
- D. Levator palpebrae (2%)
- E. Medial rectus (1%)
- F. Superior rectus (2%)

Omitted
Correct answer
C

86%
Answered correctly

02 secs
Time Spent

03/03/2020
Last Updated

Explanation

Nerve	Eye muscle(s) innervated	Oculomotor functions	Lesion findings
	• Superior rectus • Medial rectus	• Adduction • Depression	• Eye deviated downward & laterally • Diagonal diplopia

Nerve	Eye muscle(s) innervated	Oculomotor functions	Lesion findings
Oculomotor (CN III)	• Superior rectus • Medial rectus • Inferior rectus • Inferior oblique • Levator palpebrae superioris	• Adduction • Depression • Elevation • External rotation	• Eye deviated downward & laterally • Diagonal diplopia • Dilation of pupil & loss of accommodation • Ptosis
Trochlear (CN IV)	• Superior oblique	• Abduction • Internal rotation • Depression while adducted	• Eye deviated upward • Vertical & torsional diplopia
Abducens (CN VI)	• Lateral rectus	• Abduction	• Eye deviated medially • Horizontal diplopia

This patient has a right **oculomotor nerve (CN III) palsy** secondary to a compressive aneurysm. Lesions involving CN III cause ptosis (drooping of the upper eyelid) and impair adduction, depression, and elevation of the eye. As a result, diagonal (eg, horizontal and vertical) diplopia is frequently present. The eye rests in a **"down and out" position** due to the unopposed action of the **superior oblique** (CN IV) and **lateral rectus** (CN VI) muscles. Pupillary constriction and accommodation can also be affected as CN III carries parasympathetic fibers to the ciliary muscle and the iris sphincter.

CN III palsy can be due to a variety of causes, including intracranial tumors or aneurysms, nerve ischemia, and head trauma. Aneurysms causing CN III palsy most often involve the **posterior communicating artery**. When due to an aneurysm, symptoms that develop acutely are especially worrisome as they suggest active aneurysmal dilation and possible impending rupture.

(Choices A, B, D, E, and F) All of these muscles are innervated by CN III, so their function will be impaired in this patient.

Educational objective:
Lesions involving the oculomotor nerve (CN III) cause ptosis, a downward and laterally deviated eye, impaired pupillary constriction and accommodation, and diagonal diplopia. The most dreaded cause of CN III palsy is an enlarging intracranial aneurysm.

(CN III)	• Inferior oblique • Levator palpebrae superioris	• External rotation	• Ptosis
Trochlear (CN IV)	• Superior oblique	• Abduction • Internal rotation • Depression while adducted	• Eye deviated upward • Vertical & torsional diplopia
Abducens (CN VI)	• Lateral rectus	• Abduction	• Eye deviated medially • Horizontal diplopia

This patient has a right **oculomotor nerve (CN III) palsy** secondary to a compressive aneurysm. Lesions involving CN III cause ptosis (drooping of the upper eyelid) and impair adduction, depression, and elevation of the eye. As a result, diagonal (eg, horizontal and vertical) diplopia is frequently present. The eye rests in a **"down and out" position** due to the unopposed action of the **superior oblique** (CN IV) and **lateral rectus** (CN VI) muscles. Pupillary constriction and accommodation can also be affected as CN III carries parasympathetic fibers to the ciliary muscle and the iris sphincter.

CN III palsy can be due to a variety of causes, including intracranial tumors or aneurysms, nerve ischemia, and head trauma. Aneurysms causing CN III palsy most often involve the **posterior communicating artery**. When due to an aneurysm, symptoms that develop acutely are especially worrisome as they suggest active aneurysmal dilation and possible impending rupture.

(Choices A, B, D, E, and F) All of these muscles are innervated by CN III, so their function will be impaired in this patient.

Educational objective:
Lesions involving the oculomotor nerve (CN III) cause ptosis, a downward and laterally deviated eye, impaired pupillary constriction and accommodation, and diagonal diplopia. The most dreaded cause of CN III palsy is an enlarging intracranial aneurysm.

Anatomy	Nervous System	Cranial nerve palsy
Subject	System	Topic

Copyright © UWorld. All rights reserved.

1
2
3
4
5
6
7
8
9
10
11
12
13
14
15
16
17
18
19
20
21
22
23
24
25
26
27
28
29
30
31

A 56-year-old man is evaluated in the clinic due to worsening lower extremity pain and weakness. The patient has had hematuria and intermittent burning on urination for the past year. He has no history of pelvic trauma or surgery. The patient has smoked a pack of cigarettes daily for the past 35 years. His urine culture is negative for bacterial growth. Urine cytology and cystoscopy confirm the diagnosis of transitional cell carcinoma. Abdominal CT shows an advanced bladder tumor compressing a nerve that passes through the obturator canal. Which of the following actions would most likely be impaired in this patient?

A. Abduction of the thigh
B. Adduction of the thigh
C. Extension of the leg
D. Extension of the thigh
E. Flexion of the thigh

Submit

1 2 3 4 5 6 7 8 9 10 11 12 13 14 15 16 17 18 19 20 21 22 23 24 25 26 27 28 29 30 31

A 56-year-old man is evaluated in the clinic due to worsening lower extremity pain and weakness. The patient has had hematuria and intermittent burning on urination for the past year. He has no history of pelvic trauma or surgery. The patient has smoked a pack of cigarettes daily for the past 35 years. His urine culture is negative for bacterial growth. Urine cytology and cystoscopy confirm the diagnosis of transitional cell carcinoma. Abdominal CT shows an advanced bladder tumor compressing a nerve that passes through the obturator canal. Which of the following actions would most likely be impaired in this patient?

- A. Abduction of the thigh (12%)
- ✓ B. Adduction of the thigh (71%)
- C. Extension of the leg (2%)
- D. Extension of the thigh (7%)
- E. Flexion of the thigh (6%)

Omitted
Correct answer
B

71%
Answered correctly

02 secs
Time Spent

03/29/2020
Last Updated

Explanation

Obturator nerve

Nerve	Motor function	Cutaneous innervation

Obturator nerve

Nerve	Motor function	Cutaneous innervation
Obturator nerve	Adduction of the thigh	

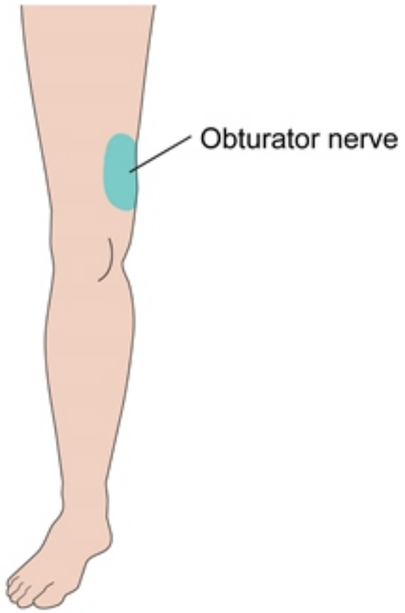

©UWorld

The **obturator nerve** arises from the lumbar plexus and carries fibers from the L2-L4 spinal segments. It descends posteromedial to the iliopsoas muscle and courses along the lateral aspect of the lesser pelvis before descending through the **obturator canal**. The obturator nerve is the only major nerve that exits the pelvis through this canal. Once the nerve has entered the thigh, it supplies the obturator externus muscle and divides into anterior and posterior branches that supply the rest of the **thigh adductor** muscles (eg, adductor longus, brevis, magnus). The anterior division of the nerve gives off a terminal cutaneous branch that provides **sensation** over the **distal medial thigh**.

Obturator nerve injury is most commonly caused by compression due to pelvic trauma, surgery, or tumors (eg, bladder cancer). Patients typically present with weakness on thigh adduction and sensory loss in the distal medial thigh.

The **obturator nerve** arises from the lumbar plexus and carries fibers from the L2-L4 spinal segments. It descends posteromedial to the iliopsoas muscle and courses along the lateral aspect of the lesser pelvis before descending through the **obturator canal**. The obturator nerve is the only major nerve that exits the pelvis through this canal. Once the nerve has entered the thigh, it supplies the obturator externus muscle and divides into anterior and posterior branches that supply the rest of the **thigh adductor** muscles (eg, adductor longus, brevis, magnus). The anterior division of the nerve gives off a terminal cutaneous branch that provides **sensation** over the **distal medial thigh**.

Obturator nerve injury is most commonly caused by compression due to pelvic trauma, surgery, or tumors (eg, bladder cancer). Patients typically present with weakness on thigh adduction and sensory loss in the distal medial thigh.

(Choice A) Abduction of the thigh is primarily accomplished by the gluteus medius, gluteus minimus, and tensor fascia lata, which are supplied by the superior gluteal nerve. This nerve exits the pelvis through the greater sciatic foramen above the piriformis.

(Choice C) Extension of the leg is mainly accomplished by the quadriceps femoris muscle group. These muscles are innervated by the femoral nerve, which gains access to the thigh deep to the midpoint of the inguinal ligament.

(Choice D) Extension of the thigh is mostly accomplished by the gluteus maximus muscle, which is supplied by the inferior gluteal nerve. This nerve exits the pelvis through the greater sciatic foramen below the piriformis.

(Choice E) Flexion of the thigh is primarily accomplished by the psoas, iliacus, and sartorius muscles. The psoas is directly innervated by the lumbar plexus, and the iliacus is innervated by the femoral nerve.

Educational objective:
The obturator nerve is the only major nerve that exits the pelvis through the obturator foramen. Nerve injury typically results from compression (eg, due to pelvic trauma, surgery, or tumor) and presents with weakness on thigh adduction and sensory loss over the distal medial thigh.

References

- Obturator neuropathy.
- Obturator mononeuropathy caused by pelvic cancer: six cases.

Anatomy	Nervous System	Bladder cancer
Subject	System	Topic

A 67-year-old woman comes to the clinic due to decreased vision in her right eye that she noticed a week ago. The patient says that her sight in the right eye is "narrower" than in the left. Her past medical history is significant for hypertension, type 2 diabetes mellitus, and hyperlipidemia. She also suffers from intermittent lower limb claudication and has had 2 prior episodes of transient vision loss in her right eye. Visual field testing reveals a right nasal hemianopia. MRI/magnetic resonance angiography of the head and neck reveal a right internal carotid artery aneurysm. Which of the following portions of the visual pathway is most likely disrupted in this patient?

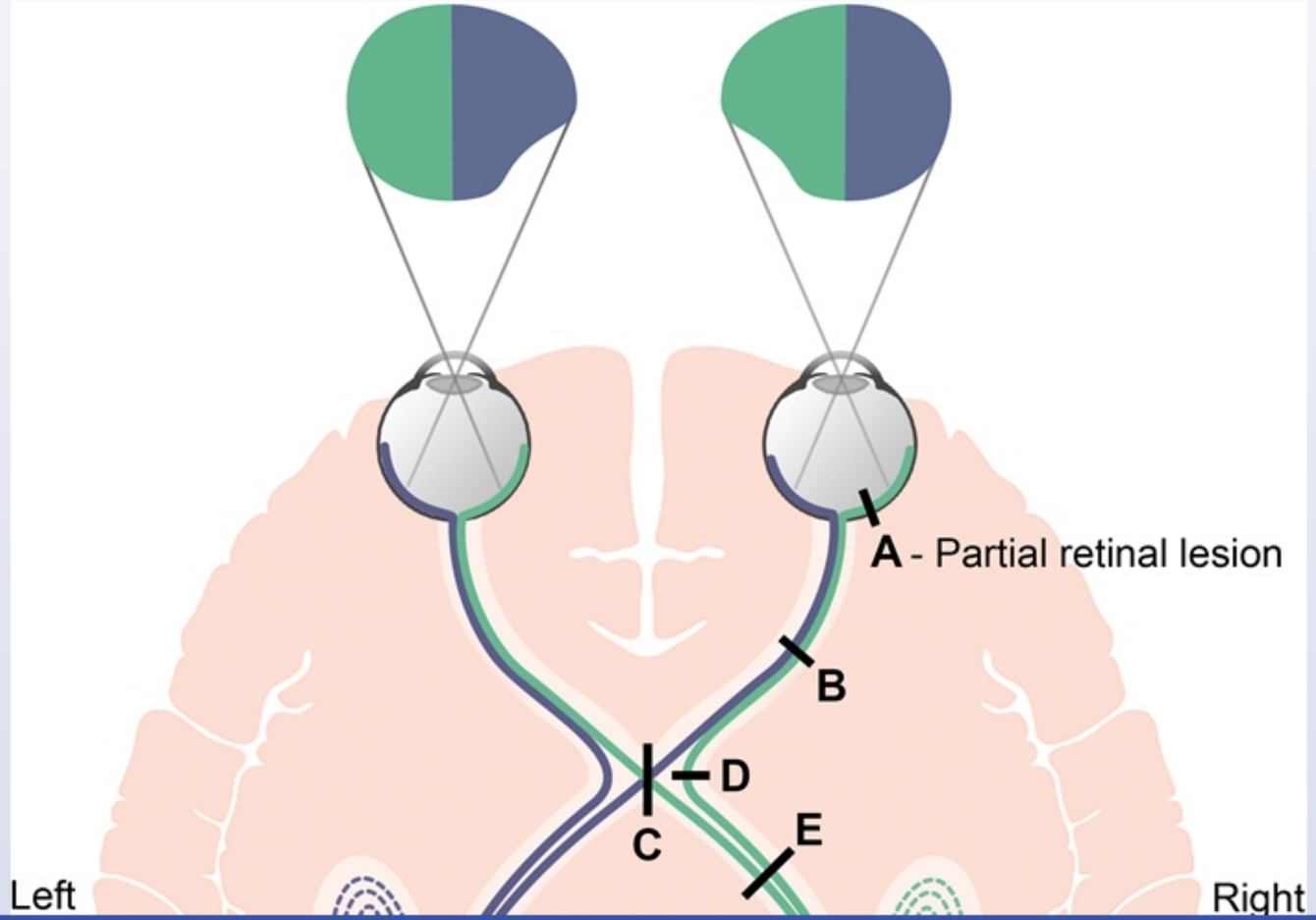

3
4
5
6
7
8
9
10
11
12
13
14
15
16
17
18
19
20
21
22
23
24
25
26
27
28
29
30
31
32
33

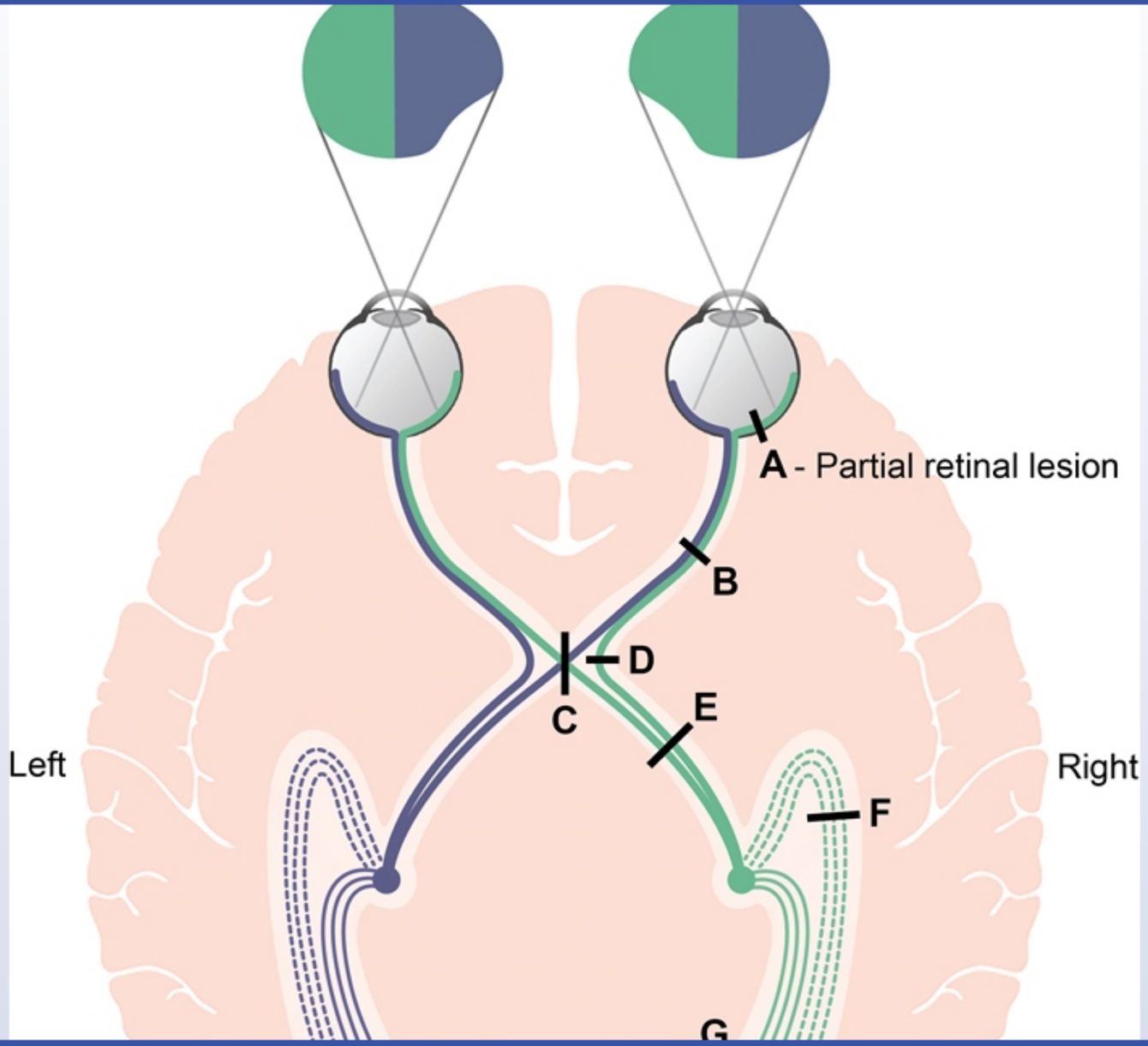

3
4
5
6
7
8
9
10
11
12
13
14
15
16
17
18
19
20
21
22
23
24
25
26
27
28
29
30
31
32
33

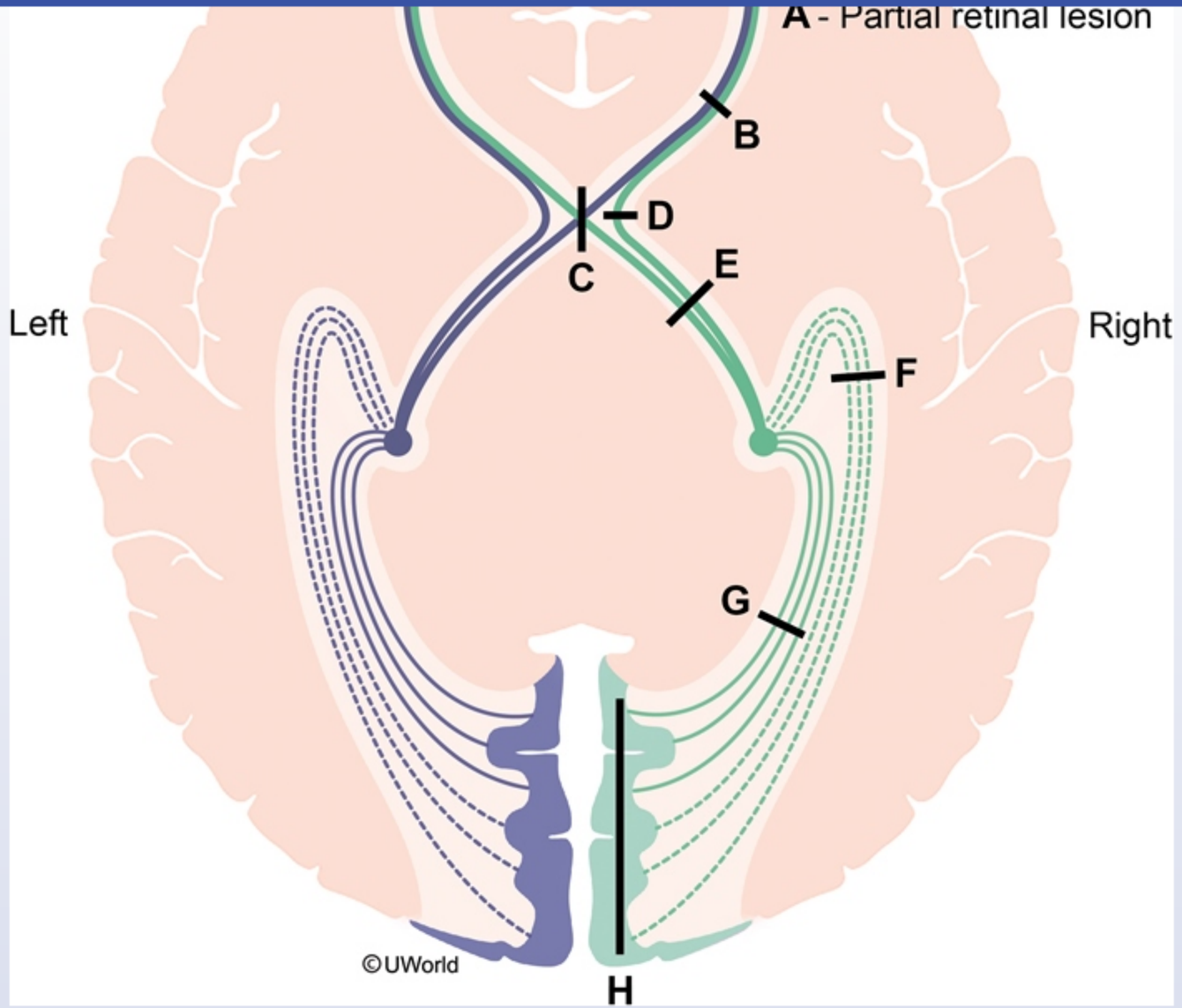

A. A

3
4
5
6
7
8
9
10
11
12
13
14
15
16
17
18
19
20
21
22
23
24
25
26
27
28
29
30
31
32
33

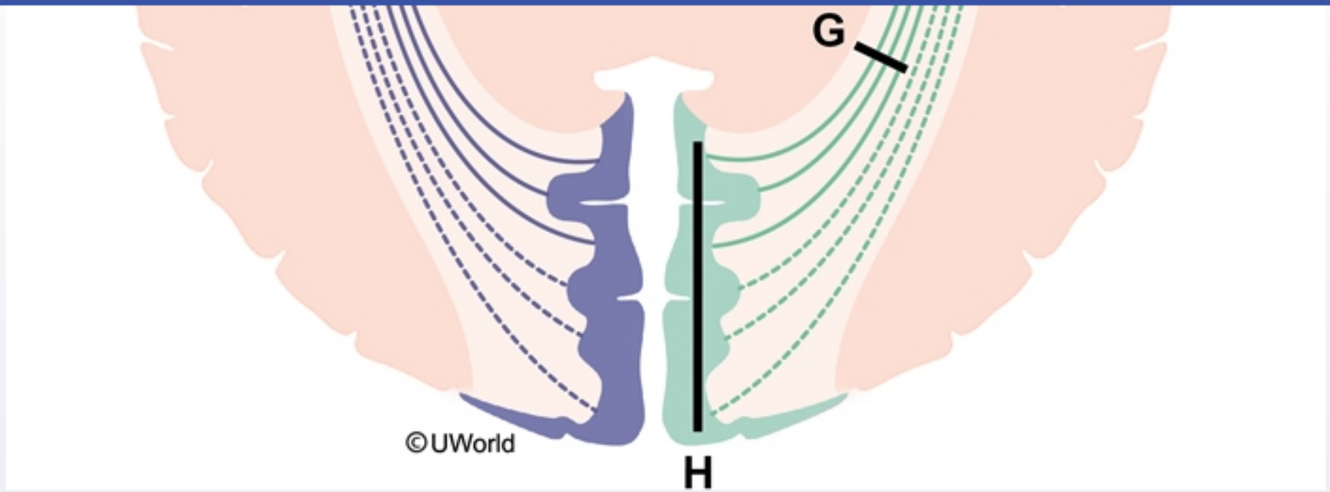

A. A
B. B
C. C
D. D
E. E
F. F
G. G
H. H

Submit

3
4
5
6
7
8
9
10
11
12
13
14
15
16
17
18
19
20
21
22
23
24
25
26
27
28
29
30
31
32
33

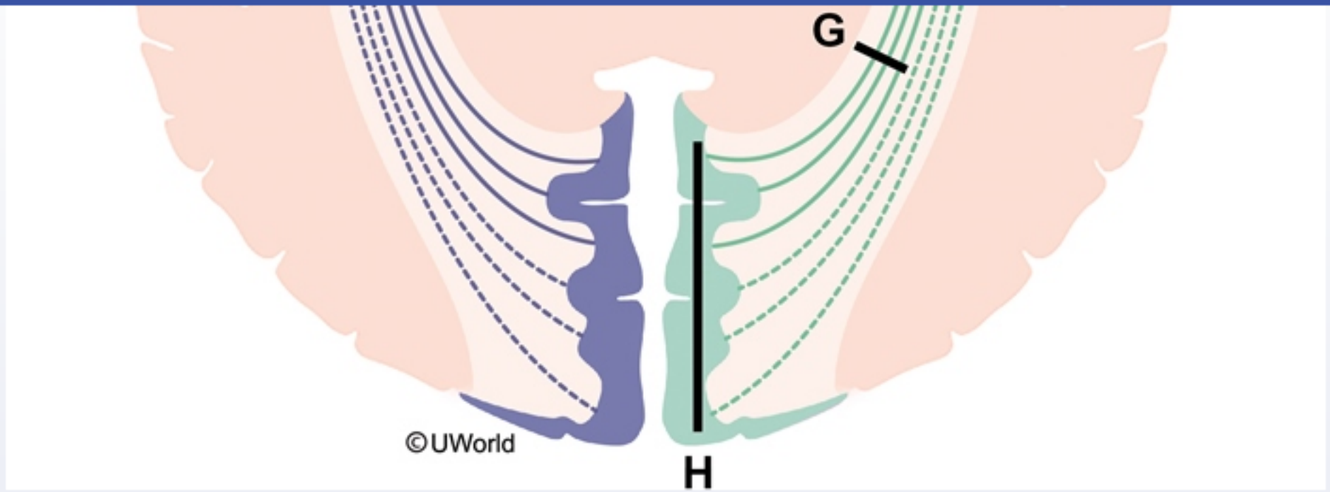

A. A (27%)
B. B (4%)
C. C (1%)
✓ D. D (56%)
E. E (4%)
F. F (2%)
G. G (0%)
H. H (0%)

Omitted
Correct answer

56%
Answered correctly

10 secs
Time Spent

04/29/2020
Last Updated

3
4
5
6
7
8
9
10
11
12
13
14
15
16
17
18
19
20
21
22
23
24
25
26
27
28
29
30
31
32
33

Visual field defect	Location of lesion	Possible causes
A. Monocular scotoma 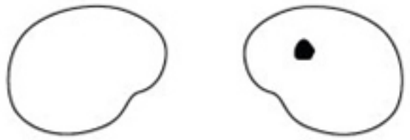	Partial lesion in the retina, optic disc, optic nerve	Macular degeneration, optic neuritis
B. Right anopia	Right optic nerve	Retinal artery or central retinal vein occlusion
C. Bitemporal hemianopia 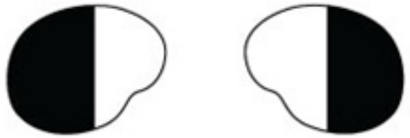	Optic chiasm	Pressure exerted by a pituitary tumor, craniopharyngioma, aneurysm of anterior communicating artery
D. Right nasal hemianopia	Right peri-chiasmal lesion	Calcification or aneurysm of the internal carotid artery impinging on uncrossed, lateral retinal fibers
E. Left homonymous hemianopia	Right optic tract or optic radiation	Optic tract: occlusion of anterior choroidal artery Optic radiation: occlusion of a

3
4
5
6
7
8
9
10
11
12
13
14
15
16
17
18
19
20
21
22
23
24
25
26
27
28
29
30
31
32
33

C. Bitemporal hemianopia 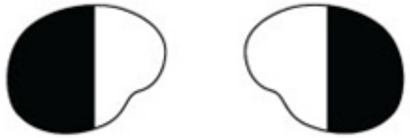	Optic chiasm	Pressure exerted by a pituitary tumor, craniopharyngioma, aneurysm of anterior communicating artery
D. Right nasal hemianopia	Right peri-chiasmal lesion	Calcification or aneurysm of the internal carotid artery impinging on uncrossed, lateral retinal fibers
E. Left homonymous hemianopia	Right optic tract or optic radiation	Optic tract: occlusion of anterior choroidal artery Optic radiation: occlusion of a middle cerebral artery branch or lesion involving posterior limb of internal capsule
F. Left homonymous superior quadrantanopia ("pie in the sky") 	Right temporal lobe (Meyer's loop)	Lesion or stroke involving temporal lobe
G. Left homonymous inferior quadrantanopia ("pie on the floor")	Right parietal lobe (dorsal optic radiation)	Lesion or stroke involving parietal lobe

3
4
5
6
7
8
9
10
11
12
13
14
15
16
17
18
19
20
21
22
23
24
25
26
27
28
29
30
31
32
33

F. Left homonymous superior quadrantanopia ("pie in the sky") 	Right temporal lobe (Meyer's loop)	Lesion or stroke involving temporal lobe
G. Left homonymous inferior quadrantanopia ("pie on the floor") 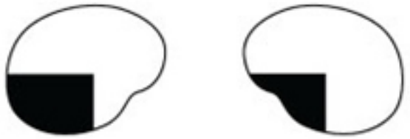	Right parietal lobe (dorsal optic radiation)	Lesion or stroke involving parietal lobe
H. Left homonymous hemianopia with macular sparing	Right primary visual cortex (occipital lobe)	Occlusion of posterior cerebral artery. Macula is spared due to collateral blood from the middle cerebral artery

©UWorld

Humans have a maximum horizontal field of view of about 200 degrees with both eyes. The central 120 degrees make up the binocular field of view (stereoscopic vision), with 2 side fields of about 40 degrees seen by only 1 eye (monoscopic vision). Unilateral visual defects within the binocular field of view (such as unilateral nasal hemianopia) may be masked due to compensation by the normal eye and may go unnoticed by the patient.

Light from the nasal visual field strikes the temporal side of each retina, and optic nerve fibers from the temporal part of the retina travel laterally

with macular sparing | cortex (occipital lobe) | artery. Macula is spared due to

Exhibit Display

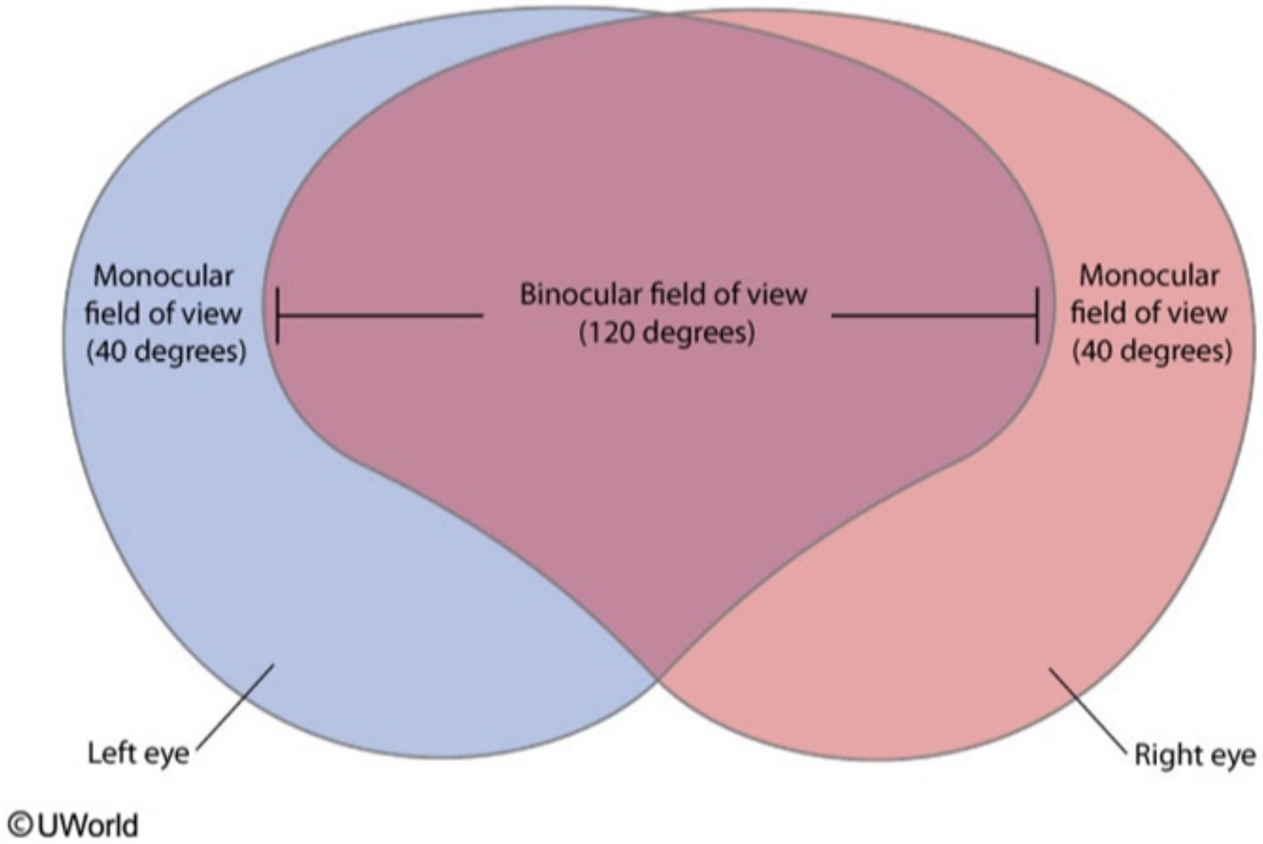

Zoom In | Zoom Out | Reset | Add To New Card | Existing Card

3
4
5
6
7
8
9
10
11
12
13
14
15
16
17
18
19
20
21
22
23
24
25
26
27
28
29
30
31
32
33

A 70-year-old right-handed woman comes to the emergency department with left-sided visual loss that she noticed on awakening in the morning. She has no headache, slurred speech, difficulty swallowing, weakness, or difficulty walking. Her other medical problems include hypertension, atrial fibrillation, and hyperlipidemia. Blood pressure is 170/102 mm Hg and pulse is 90/min and irregular. On neurologic examination, she is alert and oriented to person, place, and time. Her speech is fluent, and she follows complex commands. Examination of her visual fields shows left homonymous hemianopia with macular sparing. There is decreased sensation over the left side of her body. The remainder of the neurologic examination is within normal limits. Non-contrast head CT demonstrates an area of focal parenchymal hypoattenuation, as shown in the image below.

3
4
5
6
7
8
9
10
11
12
13
14
15
16
17
18
19
20
21
22
23
24
25
26
27
28
29
30
31
32
33

3
4
5
6
7
8
9
10
11
12
13
14
15
16
17
18
19
20
21
22
23
24
25
26
27
28
29
30
31
32
33

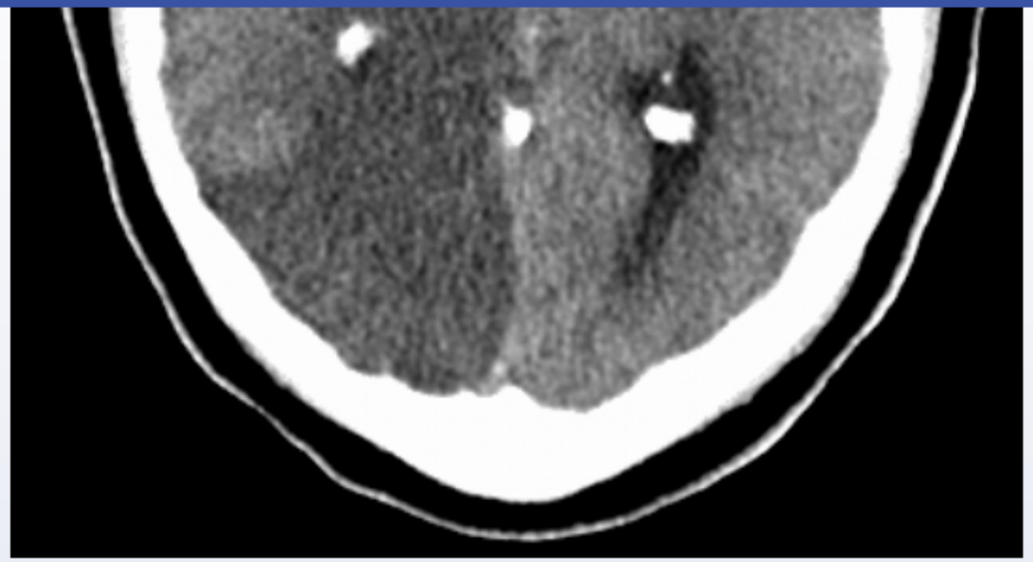

Which of the following cerebral arteries is most likely to be compromised in this patient?

- A. Anterior cerebral artery
- B. Anterior choroidal artery
- C. Artery of Percheron
- D. Basilar artery
- E. Middle cerebral artery
- F. Posterior cerebral artery

Submit

3
4
5
6
7
8
9
10
11
12
13
14
15
16
17
18
19
20
21
22
23
24
25
26
27
28
29
30
31
32
33

Blood supply to the cerebral hemispheres

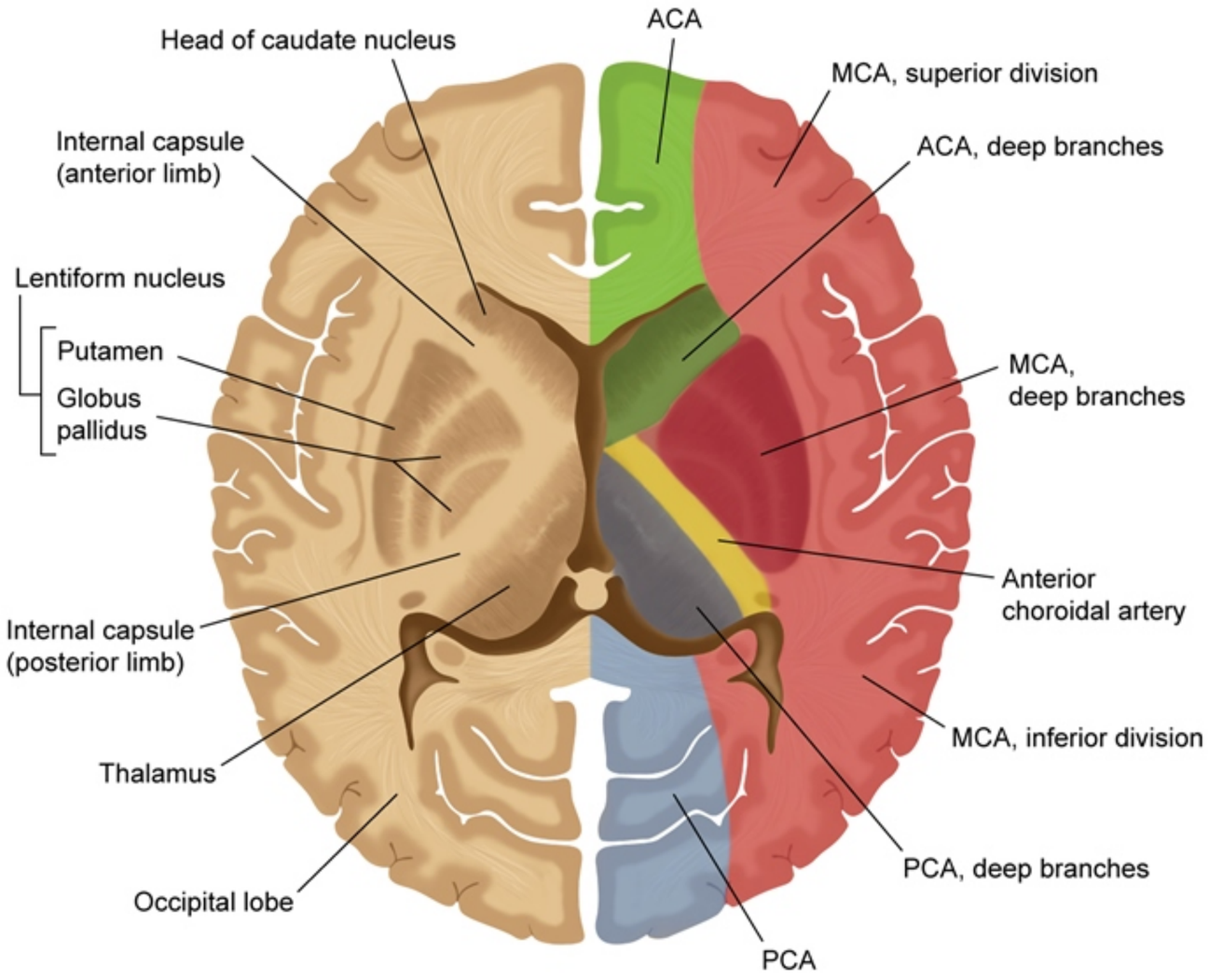

3
4
5
6
7
8
9
10
11
12
13
14
15
16
17
18
19
20
21
22
23
24
25
26
27
28
29
30
31
32
33

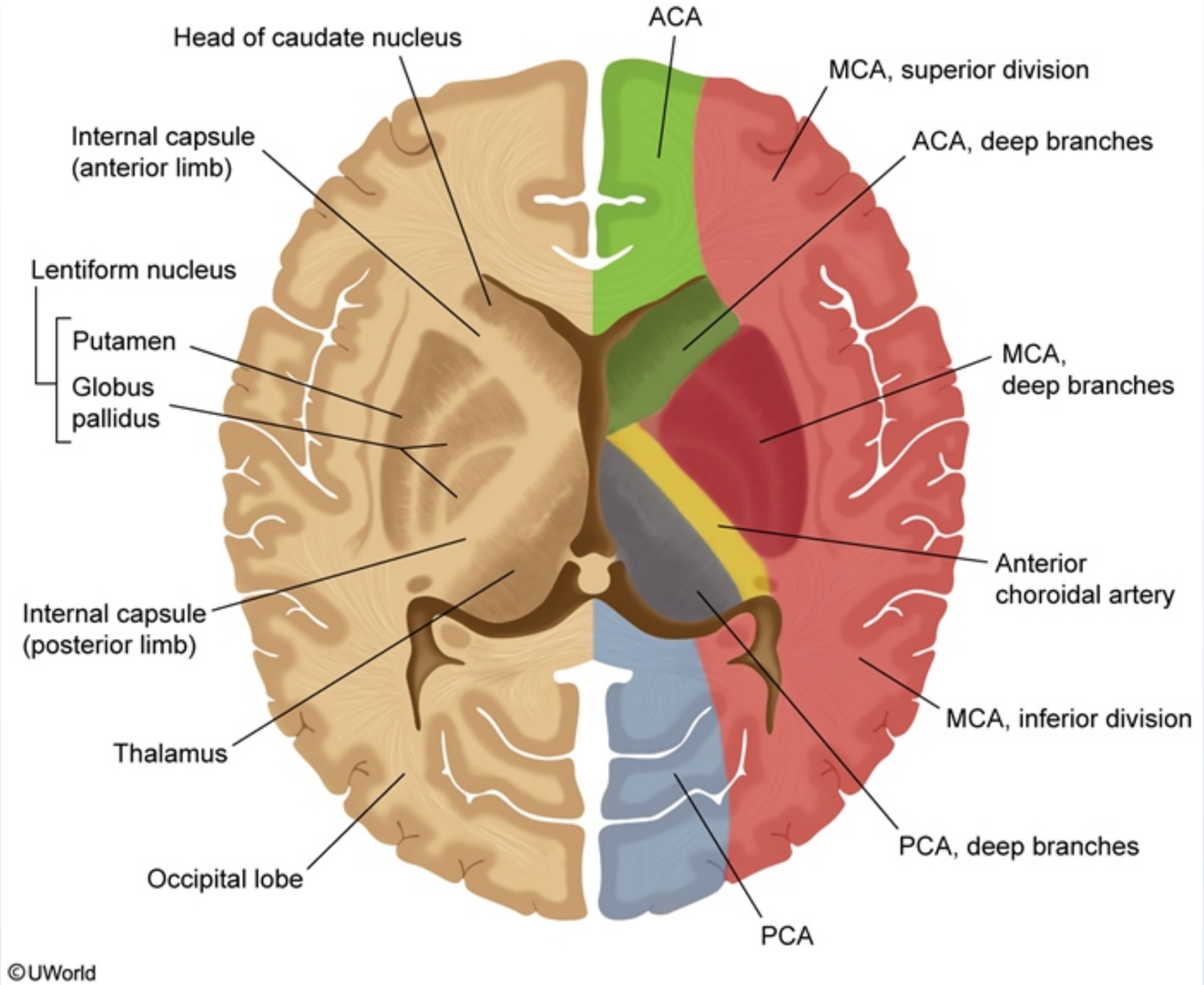

(Axial images are interpreted as if viewed from the patient's feet, so the patient's right side is shown on the left side of the image.)

This patient likely suffers from an embolic stroke due to her underlying atrial fibrillation. Non-contrast head CT demonstrates an area of focal

©UWorld

(Axial images are interpreted as if viewed from the patient's feet, so the patient's right side is shown on the left side of the image.)

This patient likely suffers from an embolic stroke due to her underlying atrial fibrillation. Non-contrast head CT demonstrates an area of focal parenchymal hypoattenuation and occipital horn effacement consistent with an evolving infarct in the distribution of the right **posterior cerebral artery** (PCA). The PCA branches off the basilar artery at the level of the pontomesencephalic junction and supplies cranial nerves III and IV and other structures in the midbrain. It also supplies the thalamus, medial temporal lobe, splenium of the corpus callosum, parahippocampal gyrus, fusiform gyrus, and occipital lobe.

The most common finding in PCA territory infarction is **contralateral hemianopia**, often with macular sparing due to collateral circulation from the middle cerebral artery. Involvement of the lateral thalamus frequently results in **contralateral paresthesias and numbness** affecting the face, trunk, and limbs. A variety of cortical symptoms can also occur, including dyslexia, visual agnosia (eg, impaired visual recognition of objects), and prosopagnosia (eg, inability to recognize faces).

(Choice A) The anterior cerebral artery distribution includes the inferior frontal, medial frontal, and superior medial parietal lobes; anterior 4/5 of the corpus callosum; olfactory bulb and tract; anterior portions of the basal ganglia; and internal capsule.

(Choice B) The anterior choroidal artery is the last branch off the internal carotid artery before it trifurcates. It supplies the posterior limb of the internal capsule, optic tract, lateral geniculate body, choroid plexus, uncus, hippocampus, and amygdala.

(Choice C) The artery of Percheron branches off either the right or left PCA and supplies the bilateral thalami and dorsal midbrain. It is considered to be a rare normal variant and can be seen in patients with bilateral thalamic or dorsal midbrain strokes.

(Choice D) The basilar artery supplies a large portion of the brain, including most of the brainstem and bilateral cerebellar hemispheres.

(Choice E) The middle cerebral artery distribution includes the lateral convexity of the frontal, parietal, and temporal lobes. It also supplies deep subcortical structures, such as the internal capsule and basal ganglia. Ischemic stroke occurs most frequently within this region, causing contralateral motor and sensory deficits involving the upper and lower extremities and face.

Educational objective:
The posterior cerebral artery branches off the basilar artery and supplies cranial nerves III and IV and other structures in the midbrain. It also supplies the thalamus, medial temporal lobe, splenium of the corpus callosum, and occipital lobe. The most common finding with posterior

3
4
5
6
7
8
9
10
11
12
13
14
15
16
17
18
19
20
21
22
23
24
25
26
27
28
29
30
31
32
33

other structures in the midbrain. It also supplies the thalamus, medial temporal lobe, splenium of the corpus callosum, parahippocampal gyrus, fusiform gyrus, and occipital lobe.

The most common finding in PCA territory infarction is **contralateral hemianopia**, often with macular sparing due to collateral circulation from the middle cerebral artery. Involvement of the lateral thalamus frequently results in **contralateral paresthesias and numbness** affecting the face, trunk, and limbs. A variety of cortical symptoms can also occur, including dyslexia, visual agnosia (eg, impaired visual recognition of objects), and prosopagnosia (eg, inability to recognize faces).

(Choice A) The anterior cerebral artery distribution includes the inferior frontal, medial frontal, and superior medial parietal lobes; anterior 4/5 of the corpus callosum; olfactory bulb and tract; anterior portions of the basal ganglia; and internal capsule.

(Choice B) The anterior choroidal artery is the last branch off the internal carotid artery before it trifurcates. It supplies the posterior limb of the internal capsule, optic tract, lateral geniculate body, choroid plexus, uncus, hippocampus, and amygdala.

(Choice C) The artery of Percheron branches off either the right or left PCA and supplies the bilateral thalami and dorsal midbrain. It is considered to be a rare normal variant and can be seen in patients with bilateral thalamic or dorsal midbrain strokes.

(Choice D) The basilar artery supplies a large portion of the brain, including most of the brainstem and bilateral cerebellar hemispheres.

(Choice E) The middle cerebral artery distribution includes the lateral convexity of the frontal, parietal, and temporal lobes. It also supplies deep subcortical structures, such as the internal capsule and basal ganglia. Ischemic stroke occurs most frequently within this region, causing contralateral motor and sensory deficits involving the upper and lower extremities and face.

Educational objective:
The posterior cerebral artery branches off the basilar artery and supplies cranial nerves III and IV and other structures in the midbrain. It also supplies the thalamus, medial temporal lobe, splenium of the corpus callosum, and occipital lobe. The most common finding with posterior cerebral artery stroke is contralateral homonymous hemianopia, often with macular sparing.

References

- Ischemic posterior circulation stroke: a review of anatomy, clinical presentations, diagnosis, and current management.

Anatomy Nervous System Ischemic stroke

3
4
5
6
7
8
9
10
11
12
13
14
15
16
17
18
19
20
21
22
23
24
25
26
27
28
29
30
31
32
33

other structures in the midbrain. It also supplies the thalamus, medial temporal lobe, splenium of the corpus callosum, parahippocampal gyrus

Exhibit Display

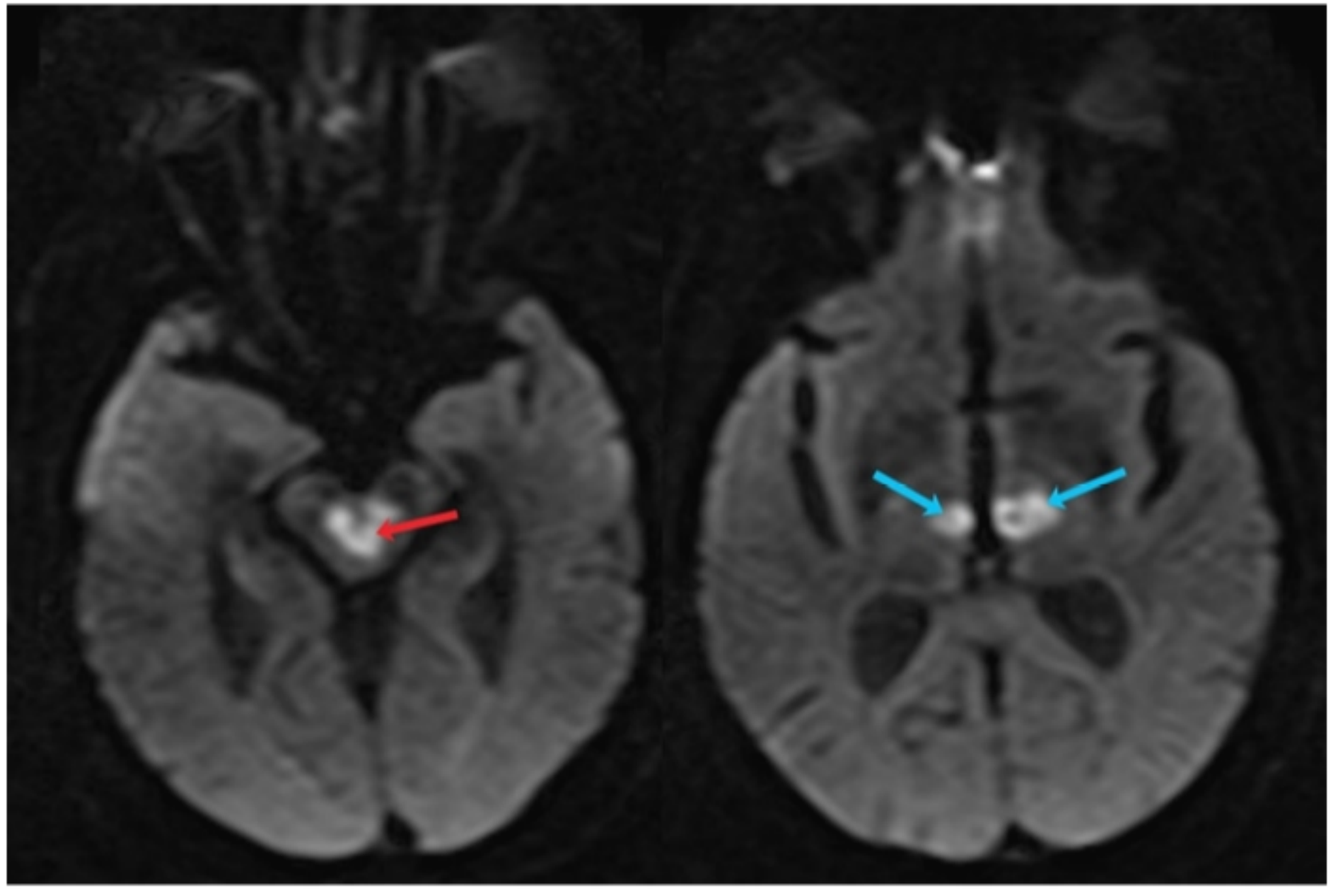

Zoom In | Zoom Out | Reset | Add To New Card | Existing Card

Anatomy | Nervous System | Ischemic stroke

fusiform gyrus, and occipital lobe.

Exhibit Display

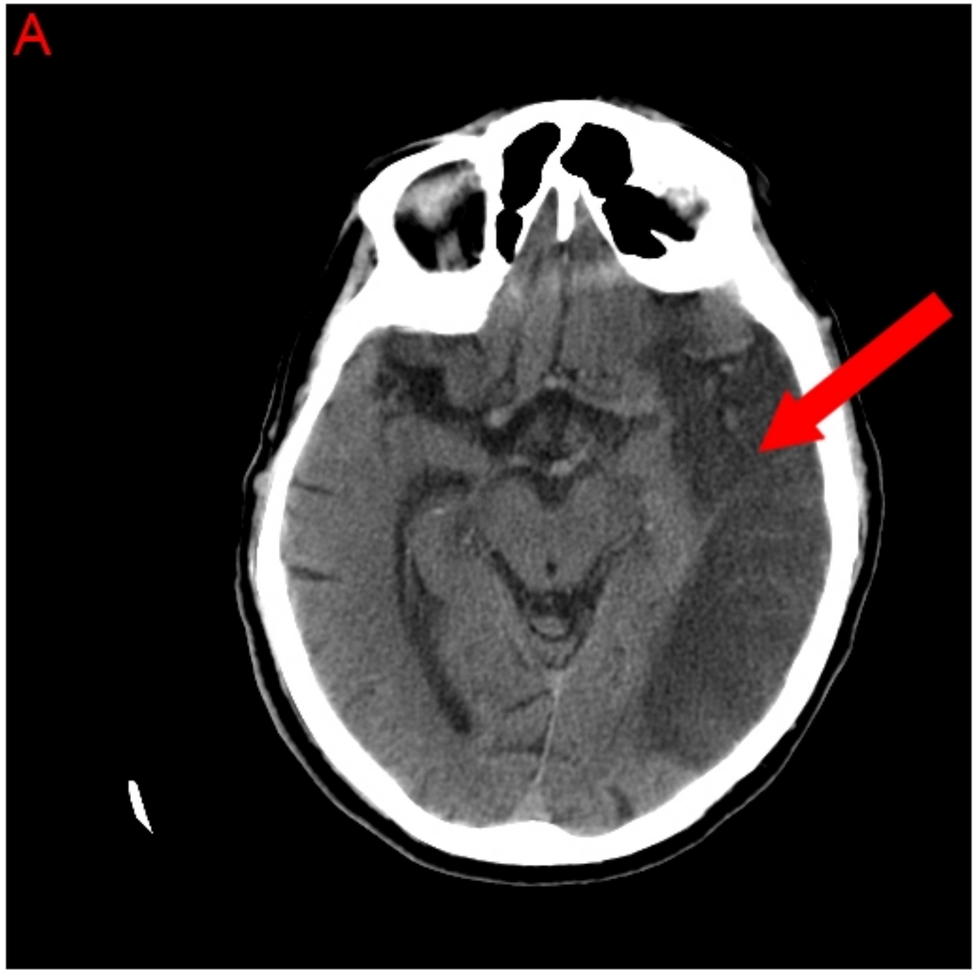

Zoom In | Zoom Out | Reset | Add To New Card | Existing Card

3
4
5
6
7
8
9
10
11
12
13
14
15
16
17
18
19
20
21
22
23
24
25
26
27
28
29
30
31
32
33

3
4
5
6
7
8
9
10
11
12
13
14
15
16
17
18
19
20
21
22
23
24
25
26
27
28
29
30
31
32
33

Exhibit Display

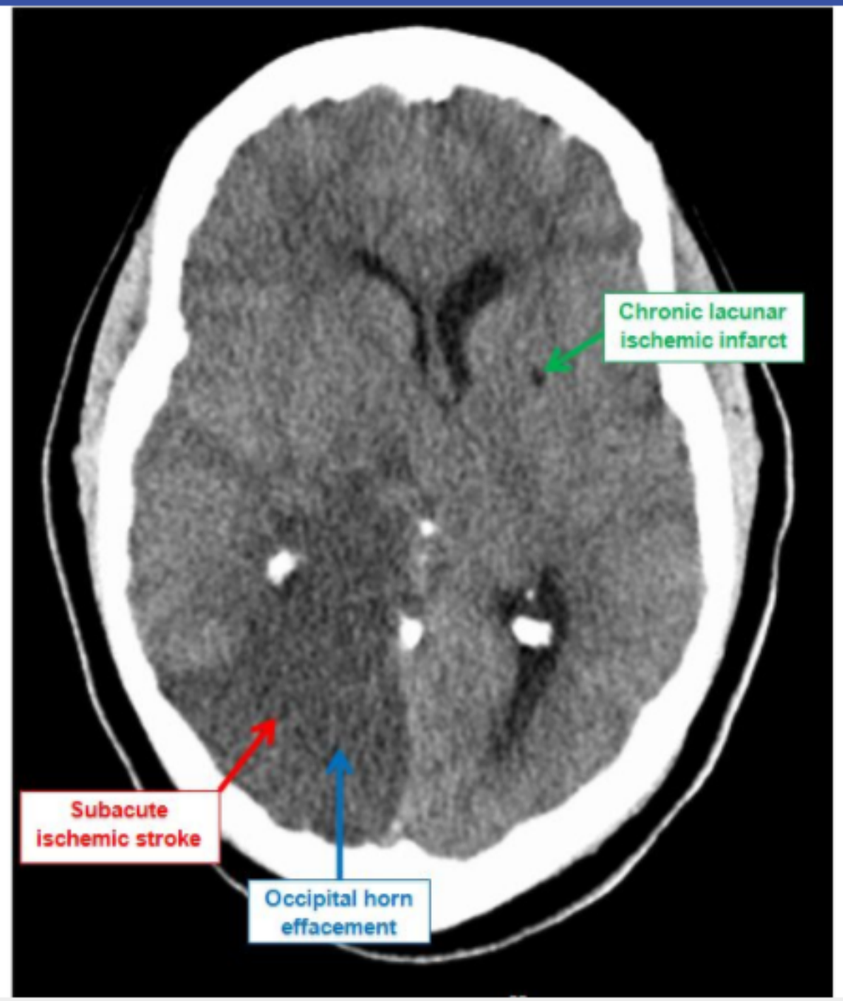

Zoom In | Zoom Out | Reset | Add To New Card | Existing Card

References

3
4
5
6
7
8
9
10
11
12
13
14
15
16
17
18
19
20
21
22
23
24
25
26
27
28
29
30
31
32
33

A 3-year-old girl is brought to the emergency department due to worsening fever and lethargy. Her parents report that she has had recurrent upper respiratory illness and recently had been irritable and pulling at her ears. She has also been eating poorly and vomiting, and has progressively become more lethargic. The patient has no chronic medical conditions and has received all recommended vaccinations. While being evaluated in the emergency department, she has a generalized tonic-clonic seizure. CT scan of the head shows a solitary 2-cm, ring-enhancing lesion in the left lateral temporal lobe. The pathogen responsible for this patient's current condition most likely gained access to the brain from which of the following structures?

A. Ethmoid air cells
B. Frontal sinus
C. Mastoid air cells
D. Maxillary sinus
E. Nose and upper lips
F. Peritonsillar space

Submit

3
4
5
6
7
8
9
10
11
12
13
14
15
16
17
18
19
20
21
22
23
24
25
26
27
28
29
30
31
32
33

A 3-year-old girl is brought to the emergency department due to worsening fever and lethargy. Her parents report that she has had recurrent upper respiratory illness and recently had been irritable and pulling at her ears. She has also been eating poorly and vomiting, and has progressively become more lethargic. The patient has no chronic medical conditions and has received all recommended vaccinations. While being evaluated in the emergency department, she has a generalized tonic-clonic seizure. CT scan of the head shows a solitary 2-cm, ring-enhancing lesion in the left lateral temporal lobe. The pathogen responsible for this patient's current condition most likely gained access to the brain from which of the following structures?

A. Ethmoid air cells (18%)
B. Frontal sinus (4%)
✓ C. Mastoid air cells (40%)
D. Maxillary sinus (13%)
E. Nose and upper lips (18%)
F. Peritonsillar space (5%)

Omitted
Correct answer
C

40%
Answered correctly

03 secs
Time Spent

01/24/2020
Last Updated

Explanation

Brain abscess is a contained area of liquefactive necrosis with a surrounding inflammatory capsule and marked vasogenic edema. It usually appears on imaging as a ring-enhancing lesion and often presents with headache, fever, and/or focal neurologic findings (eg, seizure). Most cases are **bacterial** in origin (eg, viridans streptococcus, *Staphylococcus aureus*) and stem from an underlying adjacent or distant infection.

3
4
5
6
7
8
9
10
11
12
13
14
15
16
17
18
19
20
21
22
23
24
25
26
27
28
29
30
31
32
33

Brain abscess is a contained area of liquefactive necrosis with a surrounding inflammatory capsule and marked vasogenic edema. It usually appears on imaging as a ring-enhancing lesion and often presents with headache, fever, and/or focal neurologic findings (eg, seizure). Most cases are **bacterial** in origin (eg, viridans streptococcus, *Staphylococcus aureus*) and stem from an underlying adjacent or distant infection.

The number and location of lesions helps differentiate the likely underlying source, as follows:

- **Single abscess** is usually due to the direct invasion of a contiguous infection. This patient who was pulling at her ears likely had otitis media that spread to the **mastoid air cells** and then invaded the adjacent temporal lobe leading to **temporal lobe abscess**. In contrast, frontal lobe abscess is generally due to direct spread of ethmoid or frontal sinusitis **(Choices A and B)**
- **Multiple abscesses** usually arise due to hematogenous dissemination of a distant infection, most commonly the heart (eg, endocarditis) or lungs (eg, abscess, empyema)

(Choice D) Maxillary sinusitis can spread contiguously to the orbit and cause periorbital or orbital cellulitis and abscess. Unlike the frontal and ethmoid sinus, the maxillary sinus is not adjacent to the brain.

(Choice E) Facial infections in the area around the eyes and nose drain into the opthalmic veins and can lead to cavernous sinus thrombosis, which usually presents with headache, fever, oculomotor deficits, and eye swelling.

(Choice F) Peritonsillar abscess usually presents with fever, sore throat, and a muffled voice. Complications include airway obstruction and spread of the infection to the deep neck spaces or mediastinum.

Educational objective:
A single brain abscess is usually caused by direct spread of a contiguous infection. Temporal lobe abscess is usually a result of otitis media that has spread to the mastoid air cells, while frontal lobe abscess is usually due to ethmoid or frontal sinusitis. Multiple brain abscesses typically indicate hematogenous dissemination of a distant infection (eg, endocarditis, empyema).

Anatomy	Nervous System	Brain abscess
Subject	System	Topic

Copyright © UWorld. All rights reserved.

3
4
5
6
7
8
9
10
11
12
13
14
15
16
17
18
19
20
21
22
23
24
25
26
27
28
29
30
31
32
33

Brain abscess is a contained area of liquefactive necrosis with a surrounding inflammatory capsule and marked vasogenic edema. It usually

Exhibit Display

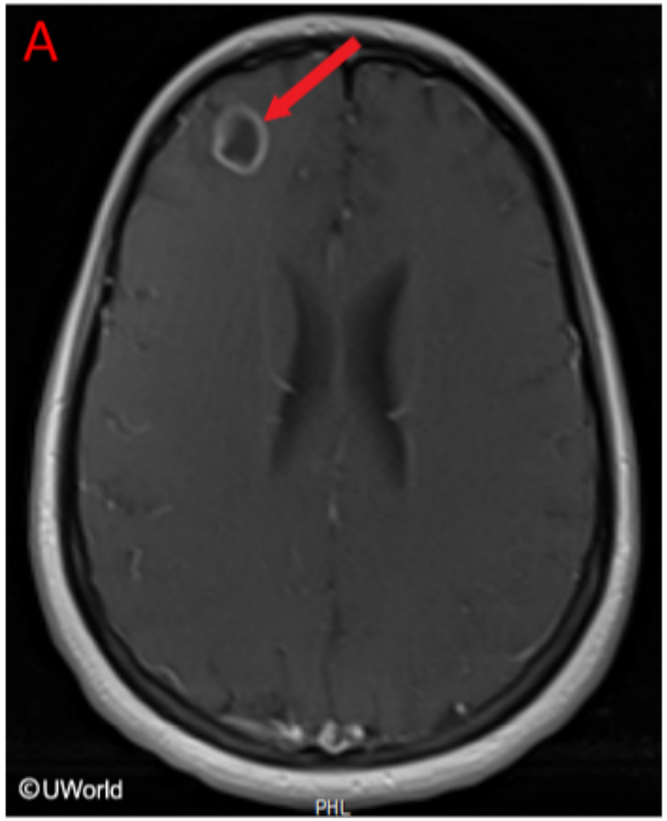

Zoom In | Zoom Out | Reset | Add To New Card | Existing Card

3
4
5
6
7
8
9
10
11
12
13
14
15
16
17
18
19
20
21
22
23
24
25
26
27
28
29
30
31
32
33

A 23-year-old woman has an acute attack of optic neuritis. She has a history of relapsing-remitting multiple sclerosis. An MRI of her brain reveals an area of demyelination involving the right optic nerve. Which of the following is most likely to be found on examination of both eyes?

	Light in the right eye		Light in the left eye	
	Right pupil constriction	Left pupil constriction	Right pupil constriction	Left pupil constriction
A.	Absent	Absent	Normal	Normal
B.	Absent	Normal	Absent	Normal
C.	Absent	Normal	Normal	Absent
D.	Normal	Absent	Normal	Absent
E.	Normal	Normal	Absent	Absent

Submit

3
4
5
6
7
8
9
10
11
12
13
14
15
16
17
18
19
20
21
22
23
24
25
26
27
28
29
30
31
32
33

A 23-year-old woman has an acute attack of optic neuritis. She has a history of relapsing-remitting multiple sclerosis. An MRI of her brain reveals an area of demyelination involving the right optic nerve. Which of the following is most likely to be found on examination of both eyes?

	Light in the right eye		Light in the left eye	
	Right pupil constriction	Left pupil constriction	Right pupil constriction	Left pupil constriction
✓ A. (75%)	Absent	Absent	Normal	Normal
B. (16%)	Absent	Normal	Absent	Normal
C. (3%)	Absent	Normal	Normal	Absent
D. (2%)	Normal	Absent	Normal	Absent
E. (2%)	Normal	Normal	Absent	Absent

Omitted
Correct answer
A

75%
Answered correctly

02 secs
Time Spent

03/22/2020
Last Updated

Explanation

3
4
5
6
7
8
9
10
11
12
13
14
15
16
17
18
19
20
21
22
23
24
25
26
27
28
29
30
31
32
33

Pupillary light reflex

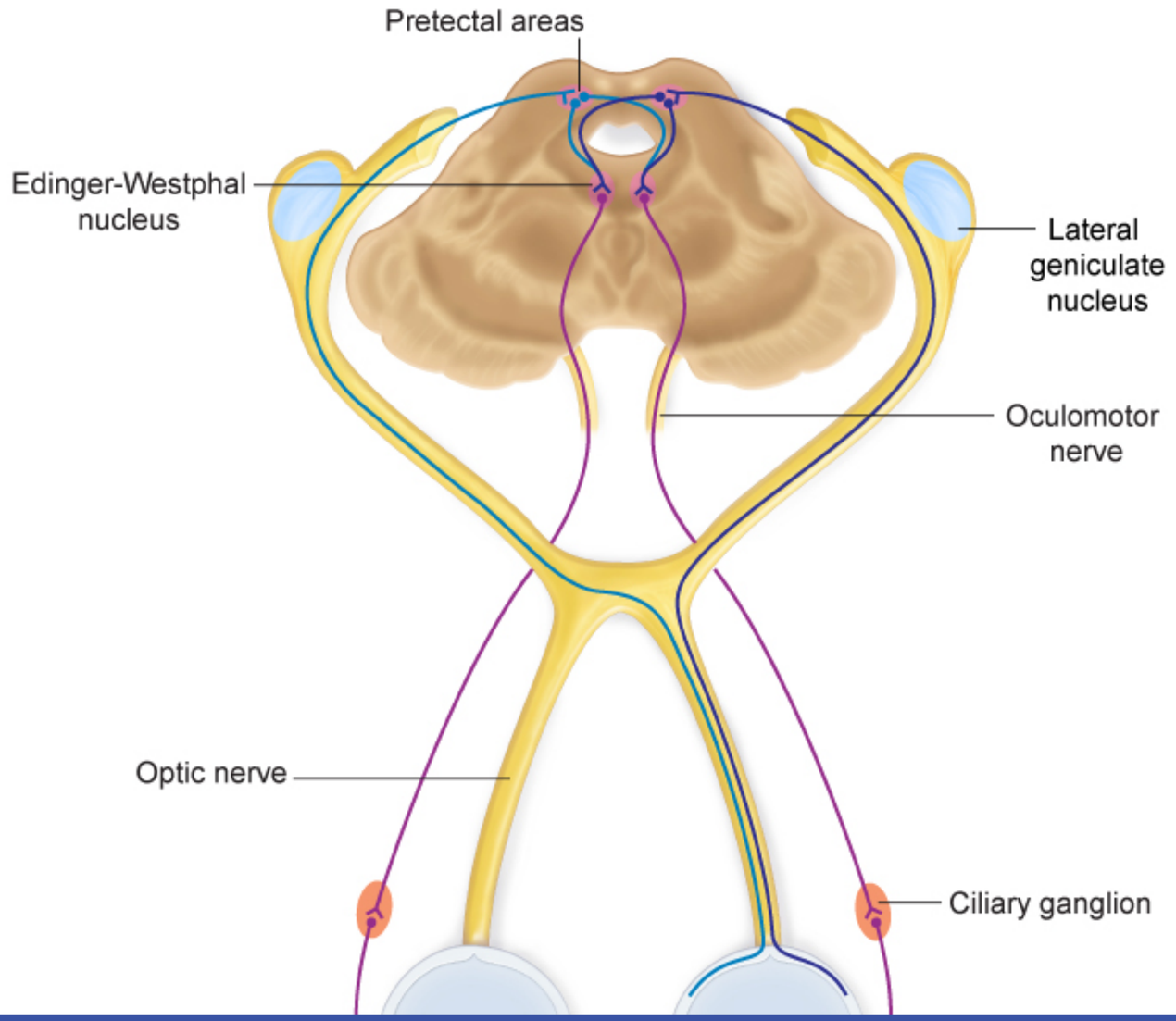

3
4
5
6
7
8
9
10
11
12
13
14
15
16
17
18
19
20
21
22
23
24
25
26
27
28
29
30
31
32
33

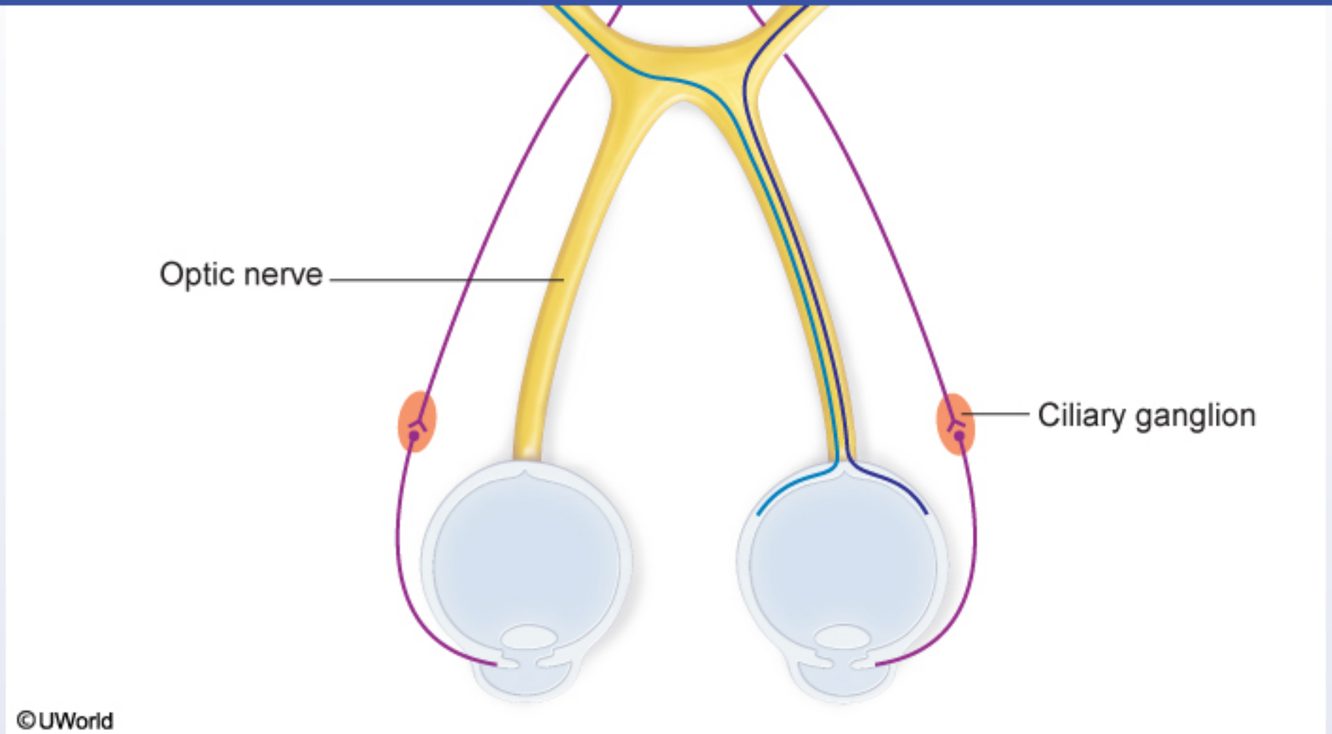

This patient with unilateral optic neuritis is most likely to demonstrate an **afferent pupillary defect** due to **demyelination** of the right optic nerve (CNII). The **optic nerve** carries the afferent limb of the pupillary light reflex, transmitting information about light entering the eye to the pretectal area in the midbrain. The pretectal area activates the Edinger-Westphal nuclei bilaterally which send parasympathetic efferent (motor) fibers down the oculomotor nerve (CN III) to innervate the pupillary sphincter muscle of each iris. The crossovers in this pathway allow light entering one eye to cause both direct pupillary constriction in the ipsilateral eye and consensual pupillary constriction in the contralateral eye.

Patients with an afferent pupillary defect (eg, optic neuritis, retinal detachment) have sluggish or **absent bilateral pupillary constriction** when shining a **light into the affected eye** (in this case, a right afferent pupillary defect). However, signals from the eye on the unaffected side (the left eye in this patient) bypass the damaged optic nerve, resulting in normal pupillary constriction of both eyes **(Choice E)**.

(Choices B and D) An absent pupillary response in one eye when light enters either eye could occur with a defect in the efferent portion of the pupillary light reflex pathway carried by the oculomotor nerve (CNIII). Pupillary constriction in the eye ipsilateral to the lesion is impaired when

3
4
5
6
7
8
9
10
11
12
13
14
15
16
17
18
19
20
21
22
23
24
25
26
27
28
29
30
31
32
33

©UWorld

This patient with unilateral optic neuritis is most likely to demonstrate an **afferent pupillary defect** due to **demyelination** of the right optic nerve (CNII). The **optic nerve** carries the afferent limb of the pupillary light reflex, transmitting information about light entering the eye to the pretectal area in the midbrain. The pretectal area activates the Edinger-Westphal nuclei bilaterally which send parasympathetic efferent (motor) fibers down the oculomotor nerve (CN III) to innervate the pupillary sphincter muscle of each iris. The crossovers in this pathway allow light entering one eye to cause both direct pupillary constriction in the ipsilateral eye and consensual pupillary constriction in the contralateral eye.

Patients with an afferent pupillary defect (eg, optic neuritis, retinal detachment) have sluggish or **absent bilateral pupillary constriction** when shining a **light into the affected eye** (in this case, a right afferent pupillary defect). However, signals from the eye on the unaffected side (the left eye in this patient) bypass the damaged optic nerve, resulting in normal pupillary constriction of both eyes **(Choice E)**.

(Choices B and D) An absent pupillary response in one eye when light enters either eye could occur with a defect in the efferent portion of the pupillary light reflex pathway carried by the oculomotor nerve (CNIII). Pupillary constriction in the eye ipsilateral to the lesion is impaired when light is shone in either eye; however, pupillary constriction in the contralateral eye occurs normally due to preserved afferent input bilaterally.

(Choice C) This constellation of findings is not consistent with any specific condition affecting the pupillary light reflex pathway.

Educational objective:
The optic nerve carries the afferent limb of the pupillary light reflex pathway, which activates the efferent limb bilaterally and causes both direct and consensual pupillary constriction. Unilateral optic nerve lesions (eg, demyelination due to optic neuritis) can result in impaired pupillary constriction bilaterally when light enters the eye ipsilateral to the lesion. When light enters the contralateral eye, pupillary constriction occurs normally in both eyes.

Anatomy	Nervous System	Visual pathway
Subject	System	Topic

Copyright © UWorld. All rights reserved.

3
4
5
6
7
8
9
10
11
12
13
14
15
16
17
18
19
20
21
22
23
24
25
26
27
28
29
30
31
32
33

©UWo

This patient with unilatera
(CNII). The **optic nerve** c
area in the midbrain. The
the oculomotor nerve (CN
to cause both direct pupill

Patients with an afferent p
shining a **light into the af**
eye in this patient) bypass

(Choices B and D) An ab
pupillary light reflex pathw
light is shone in either eye

(Choice C) This constella

Educational objective:
The optic nerve carries the
consensual pupillary cons
constriction bilaterally whe
normally in both eyes.

Anatomy
Subject

Nervous
System

Exhibit Display

0:00

Copyright © UWorld. All rights reserved.

3
4
5
6
7
8
9
10
11
12
13
14
15
16
17
18
19
20
21
22
23
24
25
26
27
28
29
30
31
32
33

A 68-year-old woman comes to the emergency department due to sudden-onset double vision that started immediately after she woke up. The patient notices that her vision worsens when looking to the right. She has no headache, weakness, or numbness. The patient has a prolonged history of hypertension, hyperlipidemia, and type 2 diabetes mellitus. Blood pressure is 160/90 mm Hg and pulse is 86/min and regular. Neurologic examination, including visual acuity, is normal with the exception of the ocular findings shown in the image below.

Rightward gaze

Neutral

Leftward gaze

6
7
8
9
10
11
12
13
14
15
16
17
18
19
20
21
22
23
24
25
26
27
28
29
30
31
32
33
34
35
36

Neutral

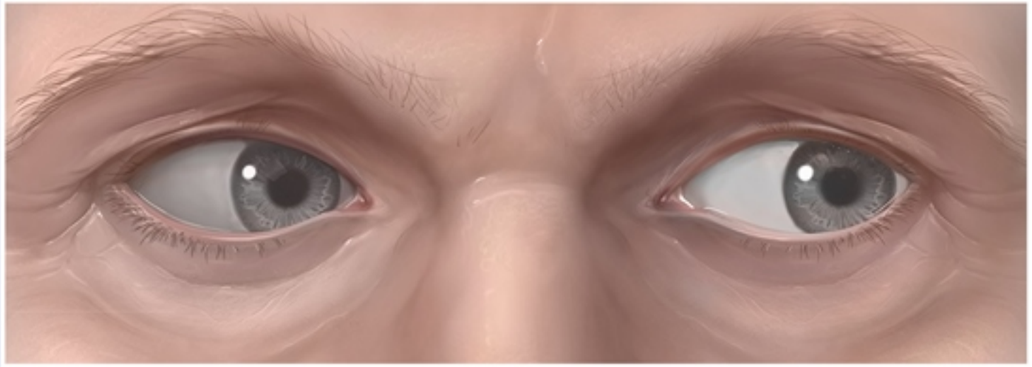

Leftward gaze

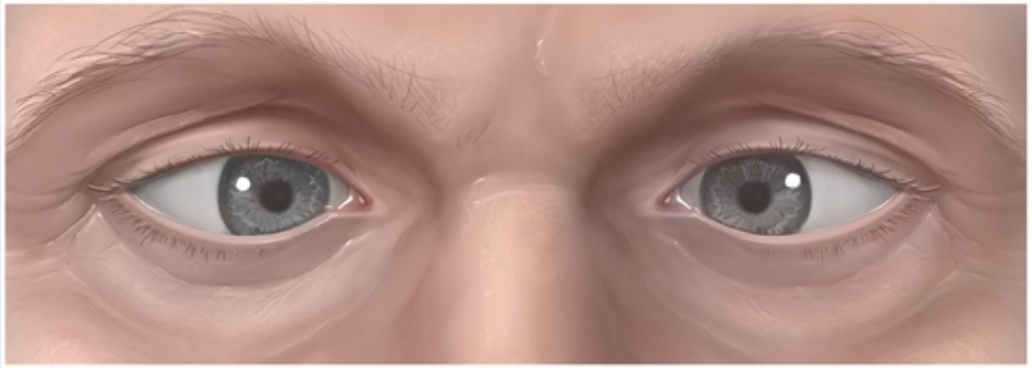

Convergence

©UWorld

6
7
8
9
10
11
12
13
14
15
16
17
18
19
20
21
22
23
24
25
26
27
28
29
30
31
32
33
34
35
36

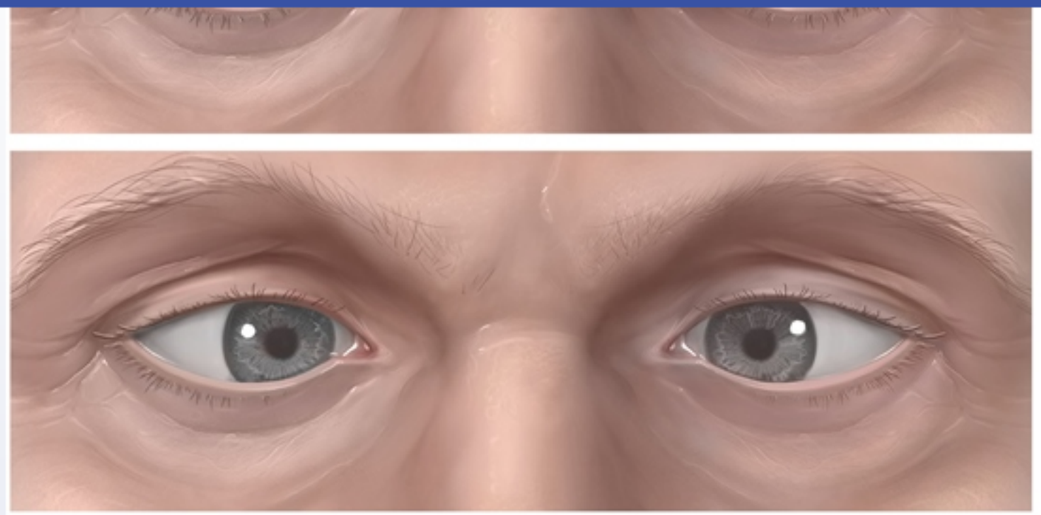

Convergence

©UWorld

A lesion involving which of the following structures is most likely causing the observed ocular findings in this patient?

- A. Abducens nerve
- B. Lateral geniculate nucleus
- C. Medial longitudinal fasciculus
- D. Occipital lobe
- E. Oculomotor nerve
- F. Superior colliculus

Submit

6
7
8
9
10
11
12
13
14
15
16
17
18
19
20
21
22
23
24
25
26
27
28
29
30
31
32
33
34
35
36

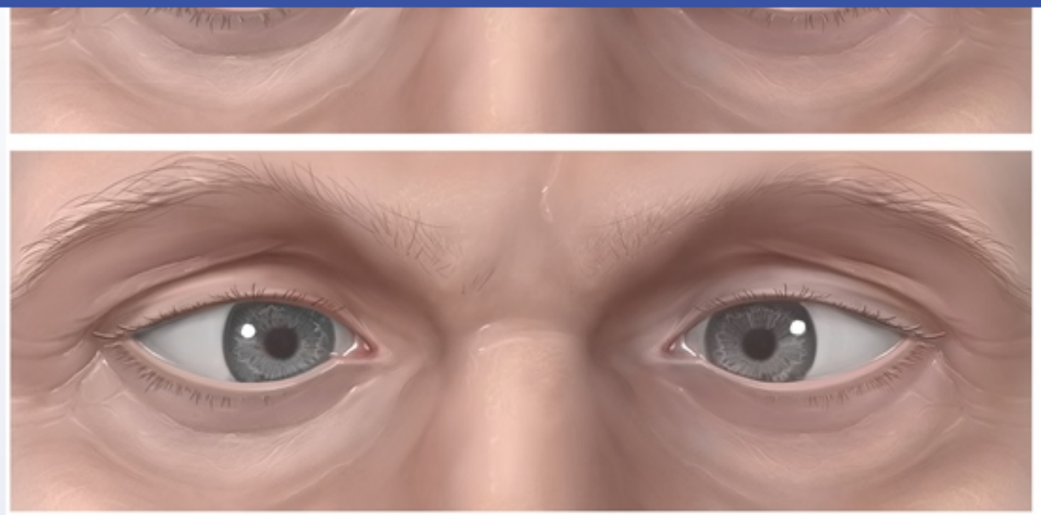

Convergence

©UWorld

A lesion involving which of the following structures is most likely causing the observed ocular findings in this patient?

- A. Abducens nerve (10%)
- B. Lateral geniculate nucleus (5%)
- ✓ C. Medial longitudinal fasciculus (67%)
- D. Occipital lobe (0%)
- E. Oculomotor nerve (14%)
- F. Superior colliculus (1%)

Omitted
Correct answer

67%
Answered correctly

09 secs
Time Spent

07/06/2020
Last Updated

6
7
8
9
10
11
12
13
14
15
16
17
18
19
20
21
22
23
24
25
26
27
28
29
30
31
32
33
34
35
36

Gaze palsy with left internuclear ophthalmoplegia

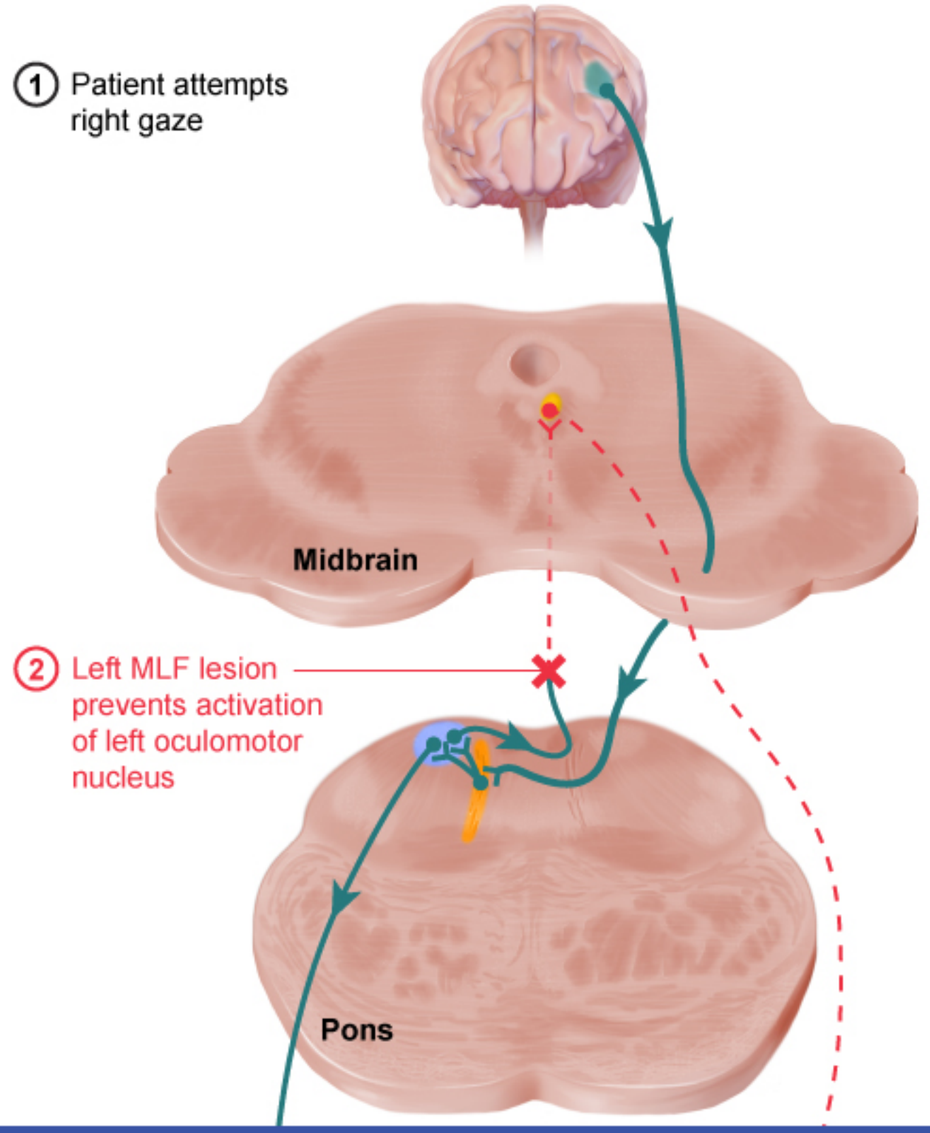

6
7
8
9
10
11
12
13
14
15
16
17
18
19
20
21
22
23
24
25
26
27
28
29
30
31
32
33
34
35
36

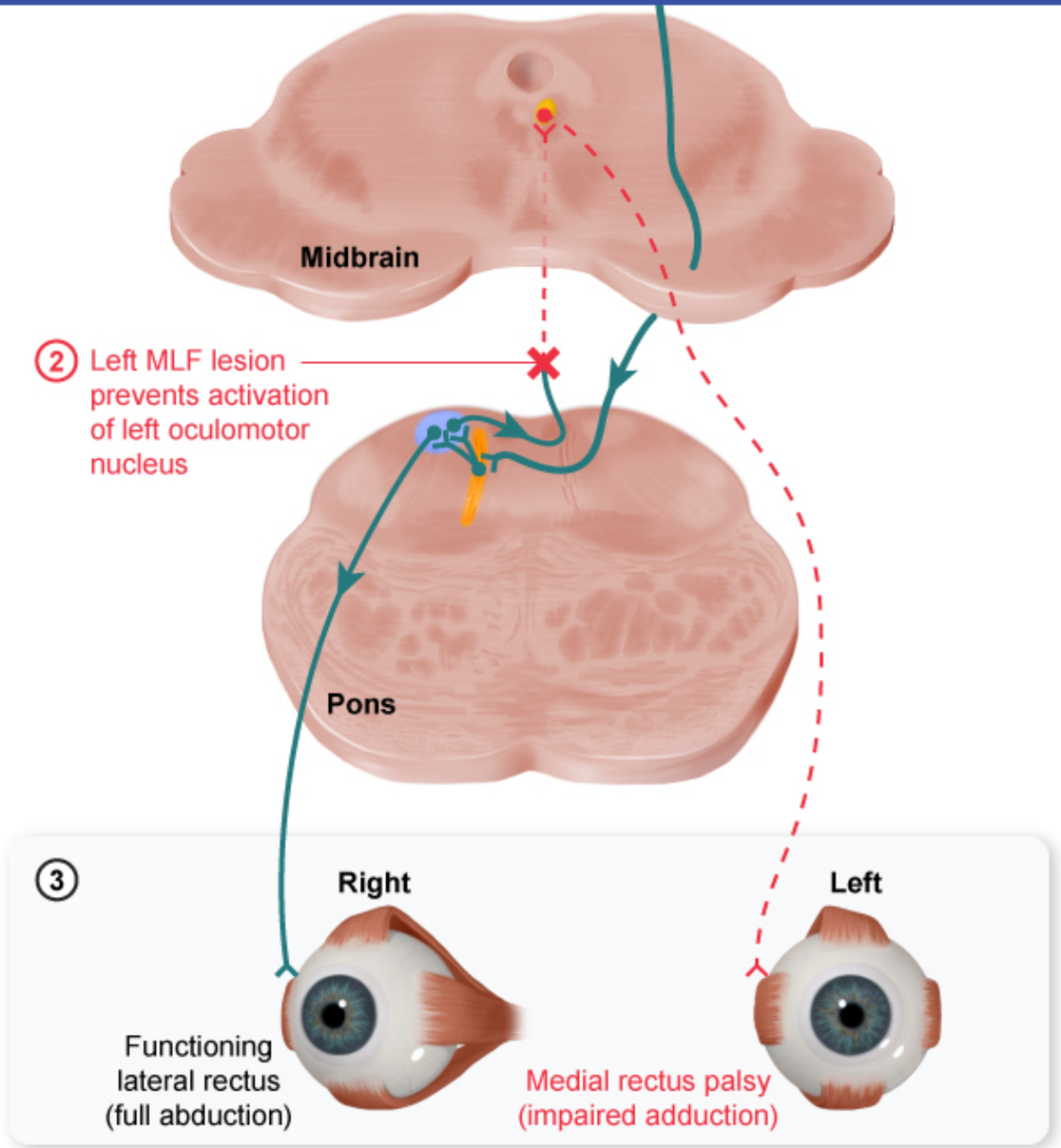

6
7
8
9
10
11
12
13
14
15
16
17
18
19
20
21
22
23
24
25
26
27
28
29
30
31
32
33
34
35
36

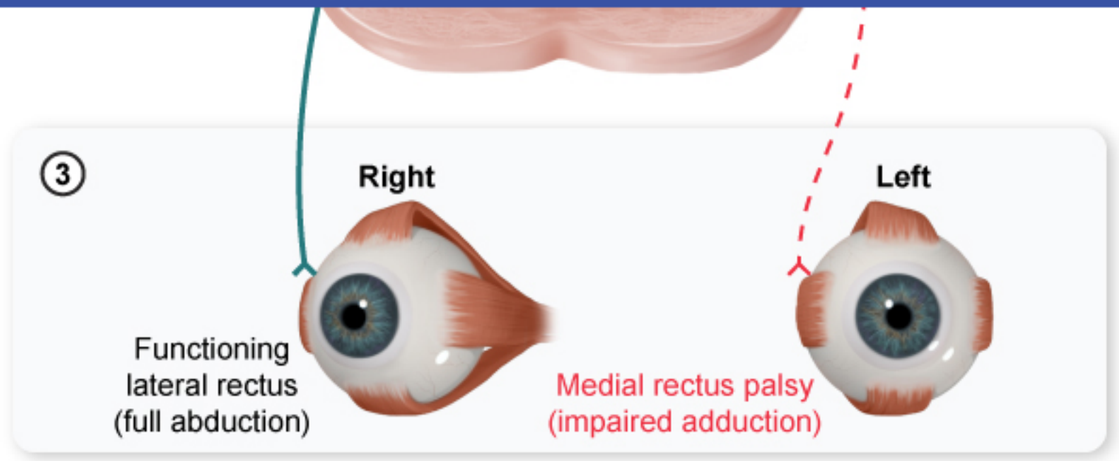

MLF = medial longitudinal fasciculus.
©UWorld

This patient has internuclear ophthalmoplegia, a disorder of impaired horizontal gaze caused by damage to the **medial longitudinal fasciculus** (MLF). The frontal eye field initiates horizontal gaze through the contralateral abducens (CN VI) nucleus, which communicates with the ipsilateral oculomotor (CN III) nucleus by way of the MLF. This allows for simultaneous activation of the lateral rectus muscle in the contralateral eye (abduction) and the medial rectus muscle in the ipsilateral eye (adduction), resulting in coordinated conjugate horizontal gaze.

Unilateral MLF lesions typically occur in older patients with lacunar strokes in the dorsal pons or midbrain (pontine artery distribution) and result in **impaired adduction** of the **ipsilateral eye** during horizontal gaze, causing **diplopia**. Abduction in the contralateral eye is preserved (but often with gaze-evoked nystagmus). The pathways for **convergence** and the pupillary light reflex bypass the MLF lesion, so these reflexes are generally **preserved**.

(Choice A) The abducens nerves innervate the lateral rectus muscles, which abduct the eyes. A lesion involving an abducens nerve would result in impaired abduction of the ipsilateral eye due to lateral rectus muscle palsy.

(Choice B) The lateral geniculate nucleus is located in the thalamus and relays visual information to the ipsilateral primary visual cortex. Damage to this structure would result in a contralateral homonymous hemianopia.

(Choice D) Unilateral infarction of the primary visual cortex in the occipital lobe (eg, posterior cerebral artery occlusion) typically results in

6
7
8
9
10
11
12
13
14
15
16
17
18
19
20
21
22
23
24
25
26
27
28
29
30
31
32
33
34
35
36

This patient has internuclear ophthalmoplegia, a disorder of impaired horizontal gaze caused by damage to the **medial longitudinal fasciculus** (MLF). The frontal eye field initiates horizontal gaze through the contralateral abducens (CN VI) nucleus, which communicates with the ipsilateral oculomotor (CN III) nucleus by way of the MLF. This allows for simultaneous activation of the lateral rectus muscle in the contralateral eye (abduction) and the medial rectus muscle in the ipsilateral eye (adduction), resulting in coordinated conjugate horizontal gaze.

Unilateral MLF lesions typically occur in older patients with lacunar strokes in the dorsal pons or midbrain (pontine artery distribution) and result in **impaired adduction** of the **ipsilateral eye** during horizontal gaze, causing **diplopia**. Abduction in the contralateral eye is preserved (but often with gaze-evoked nystagmus). The pathways for **convergence** and the pupillary light reflex bypass the MLF lesion, so these reflexes are generally **preserved**.

(Choice A) The abducens nerves innervate the lateral rectus muscles, which abduct the eyes. A lesion involving an abducens nerve would result in impaired abduction of the ipsilateral eye due to lateral rectus muscle palsy.

(Choice B) The lateral geniculate nucleus is located in the thalamus and relays visual information to the ipsilateral primary visual cortex. Damage to this structure would result in a contralateral homonymous hemianopia.

(Choice D) Unilateral infarction of the primary visual cortex in the occipital lobe (eg, posterior cerebral artery occlusion) typically results in contralateral homonymous hemianopia with macular sparing as the macula receives collateral circulation from the middle cerebral artery.

(Choice E) Oculomotor nerve palsy (eg, ipsilateral mydriasis, ptosis, "down and out" deviation of the eye) may occur with microvascular nerve ischemia (eg, diabetes mellitus) or nerve compression (eg, posterior communicating artery aneurysm).

(Choice F) The superior colliculus controls vertical gaze. Damage to the superior colliculus in the dorsal midbrain causes Parinaud syndrome (eg, upward gaze palsy, absent pupillary light reflex, impaired convergence).

Educational objective:
Internuclear ophthalmoplegia is a disorder of impaired horizontal gaze caused by a lesion in the medial longitudinal fasciculus (MLF). The affected eye (ipsilateral to the lesion) is unable to adduct while the contralateral eye is able to abduct (often with associated nystagmus). Convergence and the pupillary light reflex are preserved because these pathways bypass the MLF.

References

- Brainstem pathways for horizontal eye movement: pathologic correlation with MR imaging

6
7
8
9
10
11
12
13
14
15
16
17
18
19
20
21
22
23
24
25
26
27
28
29
30
31
32
33
34
35
36

Exhibit Display

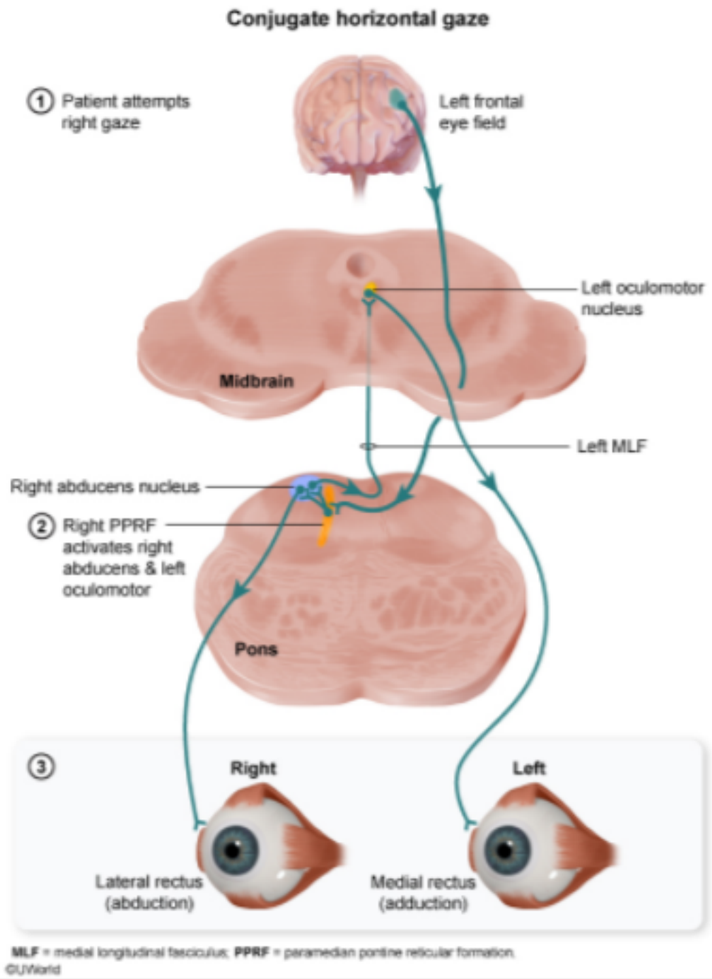

Zoom In | Zoom Out | Reset | Add To New Card | Existing Card

- Brainstem pathways for horizontal eye movement: pathologic correlation with MR imaging

6
7
8
9
10
11
12
13
14
15
16
17
18
19
20
21
22
23
24
25
26
27
28
29
30
31
32
33
34
35
36

Exhibit Display

Right abducens nerve palsy

Rightward gaze

Neutral

Leftward gaze

©UWorld

Zoom In | Zoom Out | Reset | Add To New Card | Existing Card

- Brainstem pathways for horizontal eye movement: pathologic correlation with MR imaging

6
7
8
9
10
11
12
13
14
15
16
17
18
19
20
21
22
23
24
25
26
27
28
29
30
31
32
33
34
35
36

in **impaired adduction** of the **ipsilateral eye** during horizontal gaze, causing **diplopia**. Abduction in the contralateral eye is preserved (but often with gaze-evoked nystagmus). The pathways for **convergence** and the pupillary light reflex bypass the MLF lesion, so these reflexes are generally **preserved**.

(Choice A) The abducens nerves innervate the lateral rectus muscles, which abduct the eyes. A lesion involving an abducens nerve would result in impaired abduction of the ipsilateral eye due to lateral rectus muscle palsy.

(Choice B) The lateral geniculate nucleus is located in the thalamus and relays visual information to the ipsilateral primary visual cortex. Damage to this structure would result in a contralateral homonymous hemianopia.

(Choice D) Unilateral infarction of the primary visual cortex in the occipital lobe (eg, posterior cerebral artery occlusion) typically results in contralateral homonymous hemianopia with macular sparing as the macula receives collateral circulation from the middle cerebral artery.

(Choice E) Oculomotor nerve palsy (eg, ipsilateral mydriasis, ptosis, "down and out" deviation of the eye) may occur with microvascular nerve ischemia (eg, diabetes mellitus) or nerve compression (eg, posterior communicating artery aneurysm).

(Choice F) The superior colliculus controls vertical gaze. Damage to the superior colliculus in the dorsal midbrain causes Parinaud syndrome (eg, upward gaze palsy, absent pupillary light reflex, impaired convergence).

Educational objective:
Internuclear ophthalmoplegia is a disorder of impaired horizontal gaze caused by a lesion in the medial longitudinal fasciculus (MLF). The affected eye (ipsilateral to the lesion) is unable to adduct while the contralateral eye is able to abduct (often with associated nystagmus). Convergence and the pupillary light reflex are preserved because these pathways bypass the MLF.

References

- Brainstem pathways for horizontal eye movement: pathologic correlation with MR imaging.

Anatomy	Nervous System	Internuclear ophthalmoplegia
Subject	System	Topic

Copyright © UWorld. All rights reserved.

6
7
8
9
10
11
12
13
14
15
16
17
18
19
20
21
22
23
24
25
26
27
28
29
30
31
32
33
34
35
36

A 54-year-old Caucasian male dies from a progressive neurological disorder. A brain section of the patient is shown below.

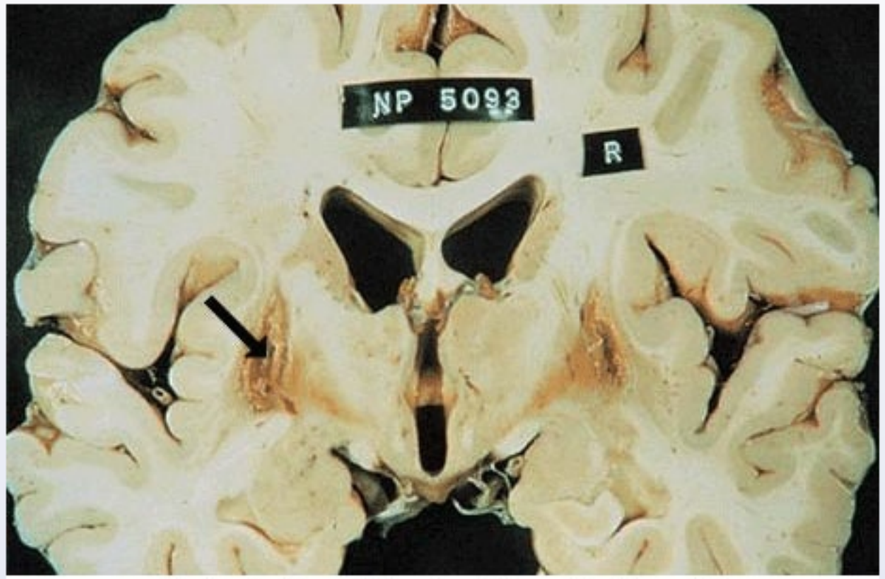

Displayed with permission from Springer Healthcare Ltd.
©Copyright 2002 by Current Medicine

Which of the following corresponds to the structure with cystic degeneration (black arrow)?

- A. Globus pallidus
- B. Putamen
- C. Internal capsule
- D. Caudate nucleus
- E. Amygdala

6
7
8
9
10
11
12
13
14
15
16
17
18
19
20
21
22
23
24
25
26
27
28
29
30
31
32
33
34
35
36

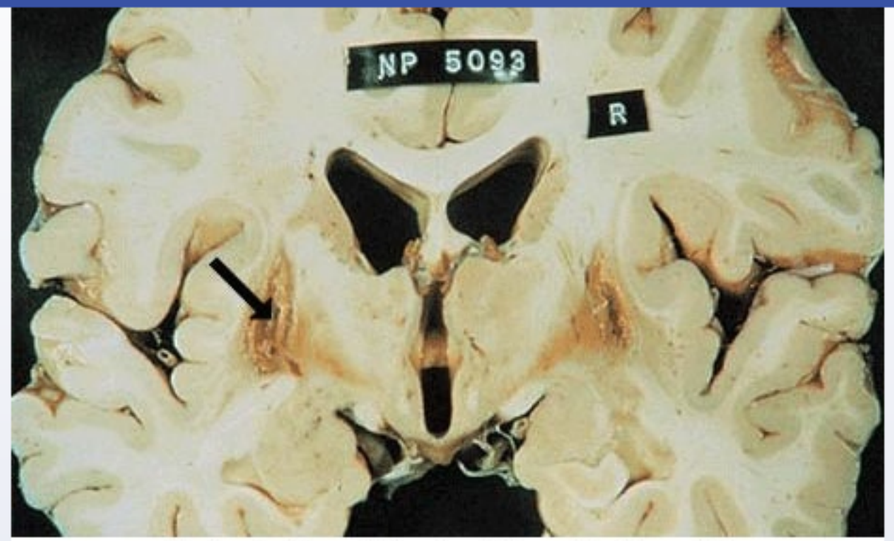

Displayed with permission from Springer Healthcare Ltd.

©Copyright 2002 by Current Medicine

Which of the following corresponds to the structure with cystic degeneration (black arrow)?

A. Globus pallidus

B. Putamen

C. Internal capsule

D. Caudate nucleus

E. Amygdala

Submit

6
7
8
9
10
11
12
13
14
15
16
17
18
19
20
21
22
23
24
25
26
27
28
29
30
31
32
33
34
35
36

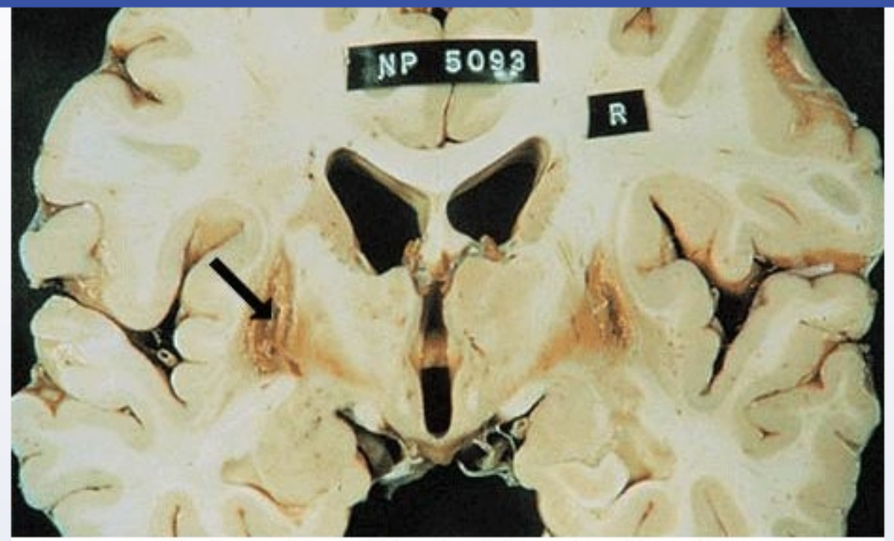

Displayed with permission from Springer Healthcare Ltd.
©Copyright 2002 by Current Medicine

Which of the following corresponds to the structure with cystic degeneration (black arrow)?

- A. Globus pallidus (18%)
- ✓ B. Putamen (54%)
- C. Internal capsule (8%)
- D. Caudate nucleus (15%)
- E. Amygdala (2%)

Omitted
Correct answer

54%
Answered correctly

05 secs
Time Spent

06/25/2020
Last Updated

6
7
8
9
10
11
12
13
14
15
16
17
18
19
20
21
22
23
24
25
26
27
28
29
30
31
32
33
34
35
36

Many progressive neurologic diseases may be associated with cystic degeneration of the putamen, but Wilson's disease is the most likely of these to be emphasized on the USMLE.

The putamen **(Choice B)** can be identified on coronal sections (either in gross specimens as above or on imaging studies) in a location immediately deep (medial) to the insula and lateral to the globus pallidus and internal capsule.

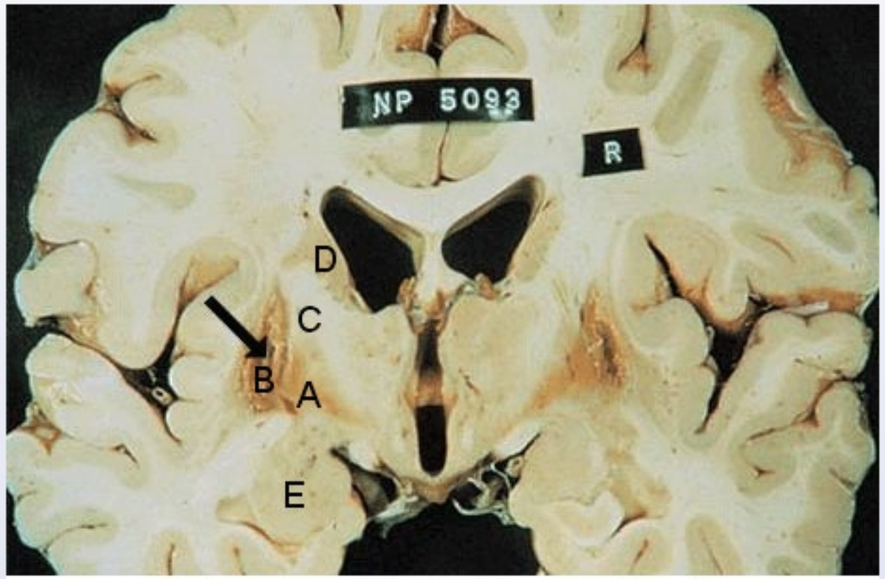

Displayed with permission from Springer Healthcare Ltd.
©Copyright 2002 by Current Medicine

(Choice A) The globus pallidus is the orange-colored structure on the above image immediately medial to the degenerated putamen. It is considered part of the basal ganglia along with the caudate and putamen.

(Choice C) The internal capsule is the white matter structure that separates the globus pallidus and putamen from the caudate nucleus anteriorly and from the thalamus posteriorly on coronal sections.

(Choice D) In its full three dimensional structure, the caudate nucleus is a curved or "C-shaped" structure that can be identified in the inferolateral walls of the anterior horns of the lateral ventricles. However, only a small cross-section is visible in the image above next to the lateral ventricles.

6
7
8
9
10
11
12
13
14
15
16
17
18
19
20
21
22
23
24
25
26
27
28
29
30
31
32
33
34
35
36

Displayed with permission from Springer Healthcare Ltd.
©Copyright 2002 by Current Medicine

(Choice A) The globus pallidus is the orange-colored structure on the above image immediately medial to the degenerated putamen. It is considered part of the basal ganglia along with the caudate and putamen.

(Choice C) The internal capsule is the white matter structure that separates the globus pallidus and putamen from the caudate nucleus anteriorly and from the thalamus posteriorly on coronal sections.

(Choice D) In its full three dimensional structure, the caudate nucleus is a curved or "C-shaped" structure that can be identified in the inferolateral walls of the anterior horns of the lateral ventricles. However, only a small cross-section is visible in the image above next to the lateral ventricles. This structure is affected in Huntington's disease.

(Choice E) The amygdala is a group of neurons in the medial temporal lobe located adjacent to the hippocampus that plays a role in the limbic system. The amygdala can be identified on the image above as the circular grey matter structures in the medial temporal lobe immediately inferior to the globus pallidus and putamen. The amygdala mediates fear and some sympathetic stimulation in humans.

Educational Objective:
Wilson's disease can cause cystic degeneration of the putamen as well as damage to other basal ganglia structures. The putamen is located medial to the insula and lateral to the globus pallidus on coronal sections.

Anatomy	Nervous System	Wilson disease
Subject	System	Topic

Copyright © UWorld. All rights reserved.

6
7
8
9
10
11
12
13
14
15
16
17
18
19
20
21
22
23
24
25
26
27
28
29
30
31
32
33
34
35
36

A highly agitated 54-year-old man is brought to the emergency department by his family because he is unable to effectively communicate. He speaks clearly and with conviction but his sentences are incomprehensible. He does not appear to understand the doctor's questions, does not follow oral or written instructions, and cannot repeat simple phrases. Branch occlusion of which of the following arteries is most likely responsible for this patient's condition?

A. Anterior cerebral artery
B. Anterior inferior cerebellar artery
C. Middle cerebral artery
D. Posterior cerebral artery
E. Posterior inferior cerebellar artery

Submit

6
7
8
9
10
11
12
13
14
15
16
17
18
19
20
21
22
23
24
25
26
27
28
29
30
31
32
33
34
35
36

A highly agitated 54-year-old man is brought to the emergency department by his family because he is unable to effectively communicate. He speaks clearly and with conviction but his sentences are incomprehensible. He does not appear to understand the doctor's questions, does not follow oral or written instructions, and cannot repeat simple phrases. Branch occlusion of which of the following arteries is most likely responsible for this patient's condition?

A. Anterior cerebral artery (4%)

B. Anterior inferior cerebellar artery (1%)

✓ C. Middle cerebral artery (88%)

D. Posterior cerebral artery (4%)

E. Posterior inferior cerebellar artery (1%)

Omitted
Correct answer
C

88%
Answered correctly

02 secs
Time Spent

04/30/2020
Last Updated

Explanation

This patient has fluent aphasia, a form of receptive aphasia characterized by speech that is fluent, well articulated, and melodic - but meaningless. Individuals stricken with fluent aphasia cannot understand verbal or written language. Repetition is usually affected to the same degree as the impairment in comprehension. Typically, patients will have no awareness of their cognitive deficit. Fluent aphasia is often produced by a lesion in Wernicke's area, which is located in the auditory association cortex within the posterior portion of the superior temporal gyrus in the dominant (usually left) temporal lobe.

The regions of the cerebral cortex supplied by the middle cerebral artery (MCA) are approximated by the red oval in the image below. The inferior

This patient has fluent aphasia, a form of receptive aphasia characterized by speech that is fluent, well articulated, and melodic - but meaningless. Individuals stricken with fluent aphasia cannot understand verbal or written language. Repetition is usually affected to the same degree as the impairment in comprehension. Typically, patients will have no awareness of their cognitive deficit. Fluent aphasia is often produced by a lesion in Wernicke's area, which is located in the auditory association cortex within the posterior portion of the superior temporal gyrus in the dominant (usually left) temporal lobe.

The regions of the cerebral cortex supplied by the middle cerebral artery (MCA) are approximated by the red oval in the image below. The inferior terminal MCA branches supply Wernicke's area.

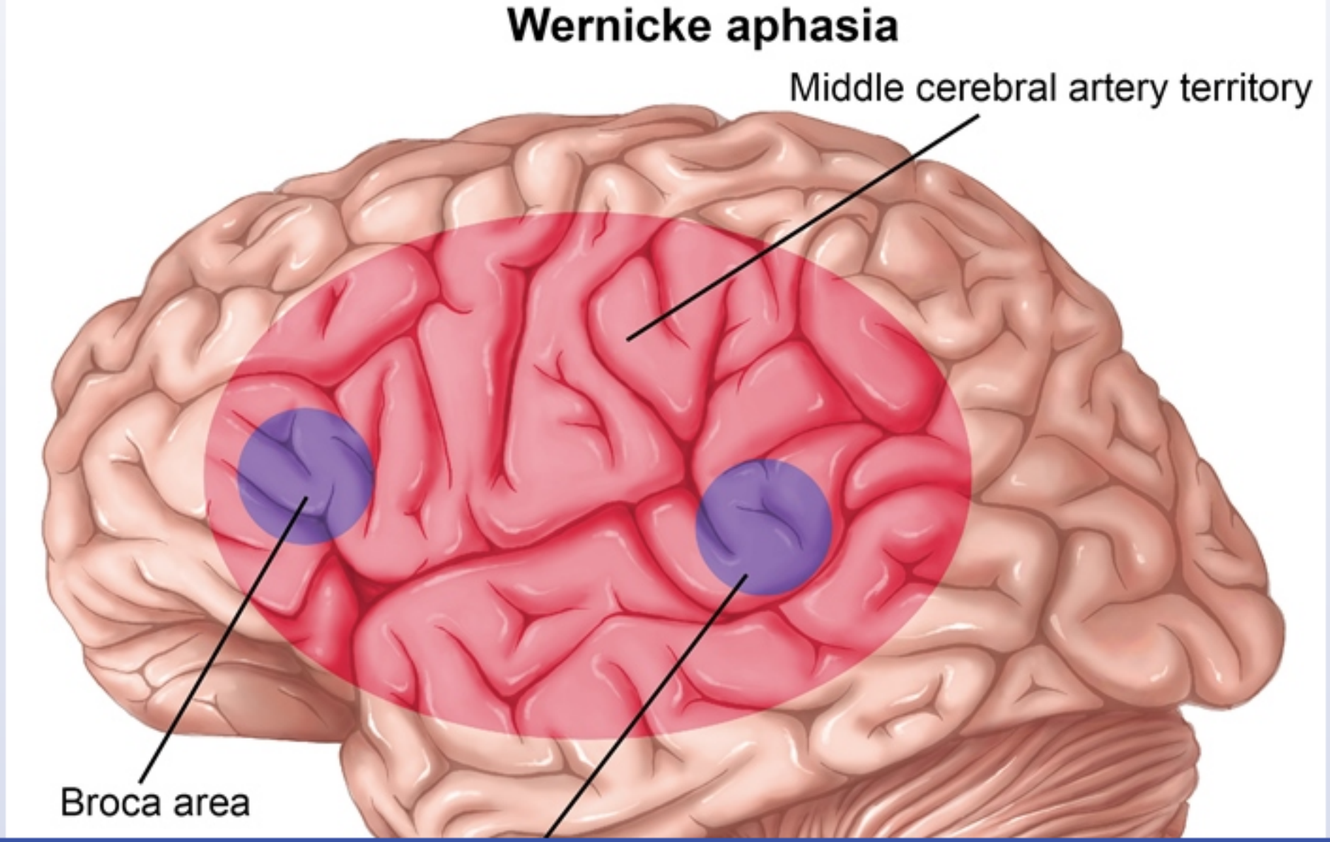

6
7
8
9
10
11
12
13
14
15
16
17
18
19
20
21
22
23
24
25
26
27
28
29
30
31
32
33
34
35
36

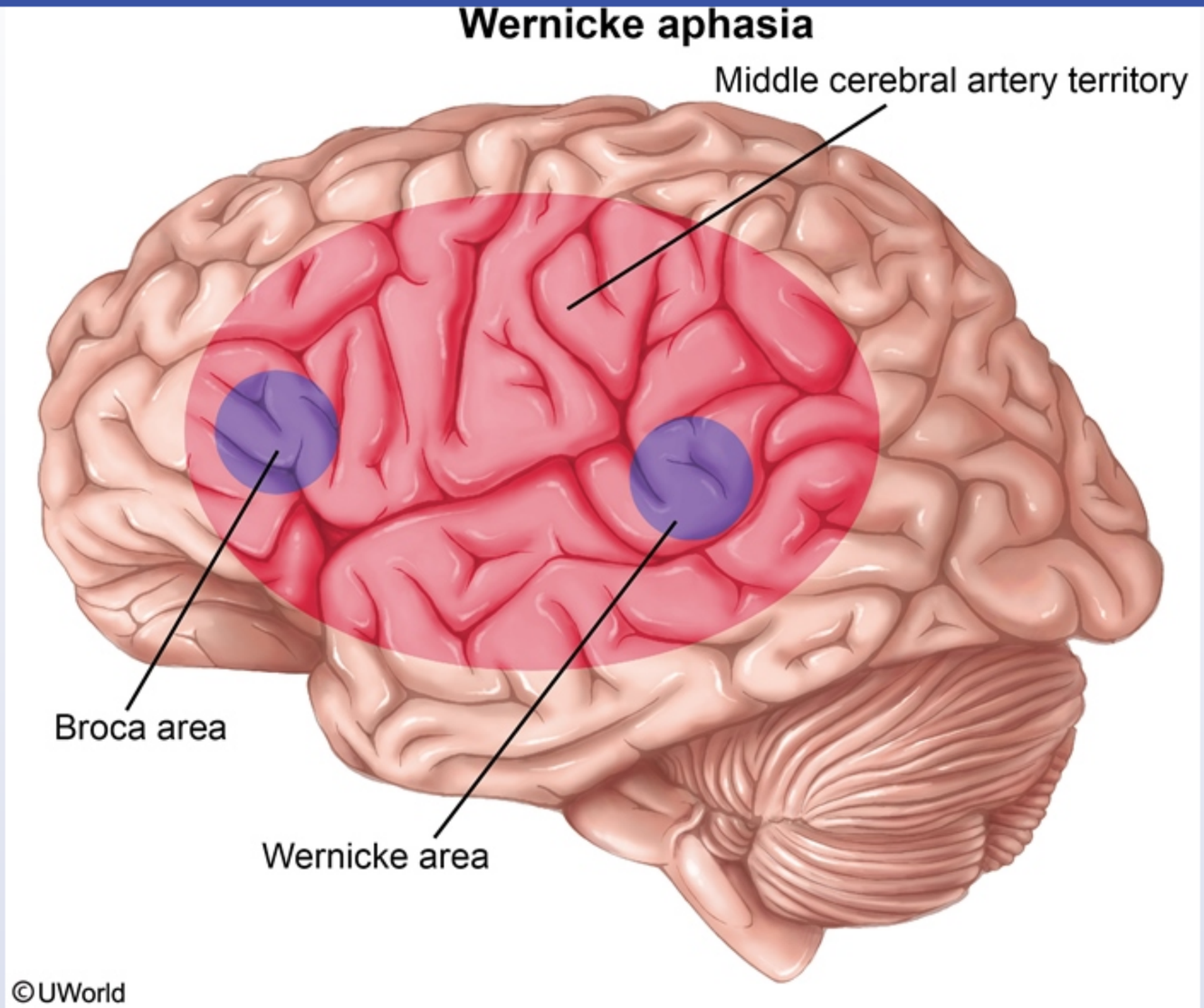

(Choices A, B, D, and E) The anterior cerebral artery, anterior inferior cerebellar artery, posterior cerebral artery, and posterior inferior cerebellar artery do not typically service Wernicke's area. Consequently, occlusions of these arteries would not be associated with Wernicke's aphasia.

6
7
8
9
10
11
12
13
14
15
16
17
18
19
20
21
22
23
24
25
26
27
28
29
30
31
32
33
34
35
36

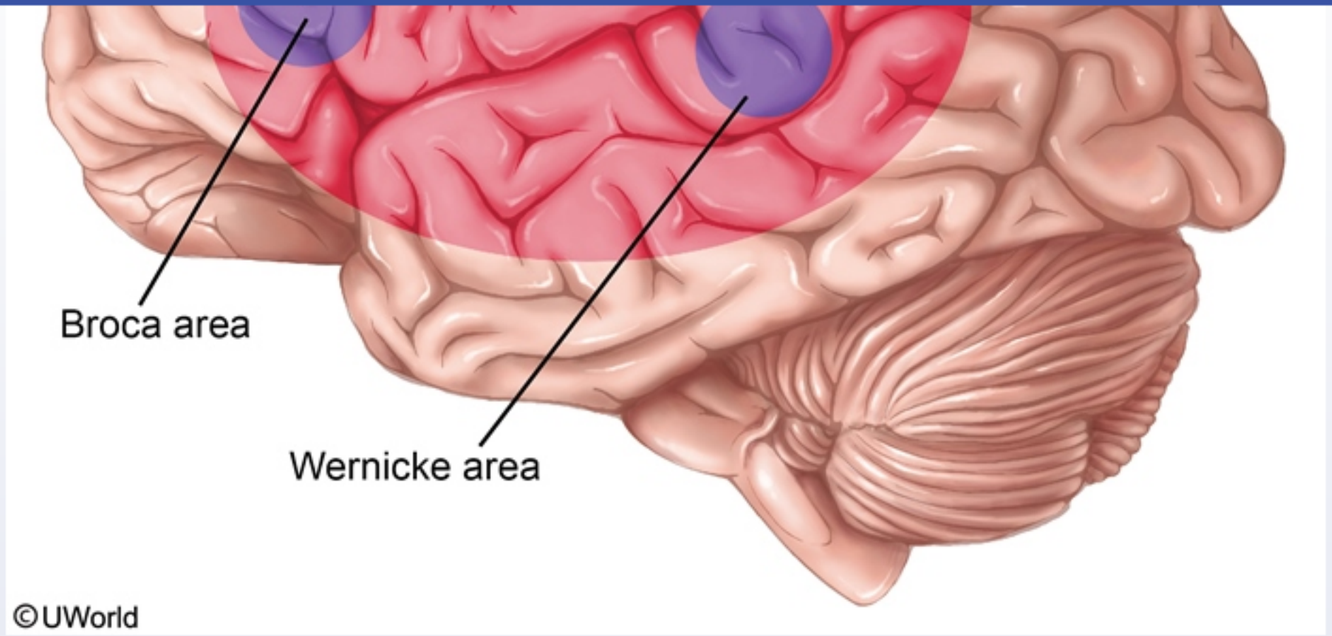

(Choices A, B, D, and E) The anterior cerebral artery, anterior inferior cerebellar artery, posterior cerebral artery, and posterior inferior cerebellar artery do not typically service Wernicke's area. Consequently, occlusions of these arteries would not be associated with Wernicke's aphasia.

Educational objective:
A lesion in Wernicke's area can cause receptive aphasia, which is characterized by well-articulated, nonsensical speech paired with a lack of language comprehension (**W**ernicke-**W**ord salad). Wernicke's area is located in the auditory association cortex within the posterior portion of the superior temporal gyrus in the dominant temporal lobe. The middle cerebral artery supplies Broca's area (superior division) and Wernicke's area (inferior division).

Anatomy	Nervous System	Aphasia
Subject	System	Topic

Copyright © UWorld. All rights reserved.

6
7
8
9
10
11
12
13
14
15
16
17
18
19
20
21
22
23
24
25
26
27
28
29
30
31
32
33
34
35
36

A 54-year-old woman is evaluated in the clinic due to easy fatigability. The patient has had no weight gain or cold intolerance, and has no history of thyroid problems. Her medical history is significant for gastrectomy due to a nonhealing gastric ulcer. Physical examination shows a shiny tongue and pale palmar creases. Her gait is unstable when her eyes are closed, and vibration sense is markedly decreased over the lower extremities. There is mild symmetrical loss of strength affecting the proximal lower extremity muscles. Blood hemoglobin level is 7.2 g/dL and white blood cell count is 3,600/mm^3. Stool tests for occult blood are repeatedly negative. Which of the following spinal cord lesions is most likely present in this patient?

A.

B.

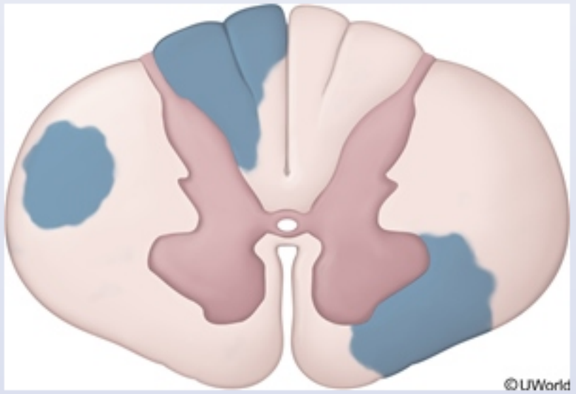

C.

6
7
8
9
10
11
12
13
14
15
16
17
18
19
20
21
22
23
24
25
26
27
28
29
30
31
32
33
34
35
36

B.

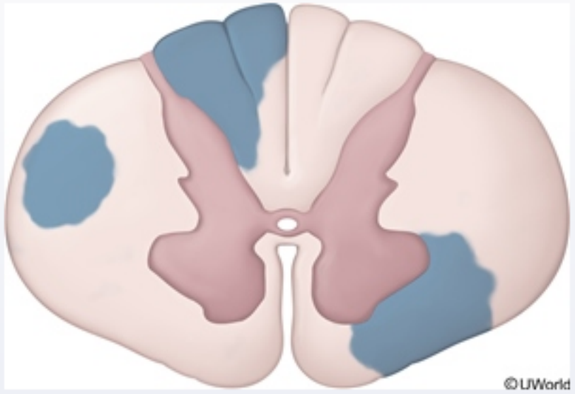

C.

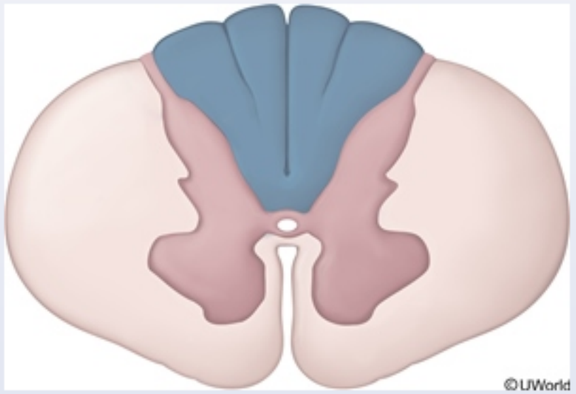

D.

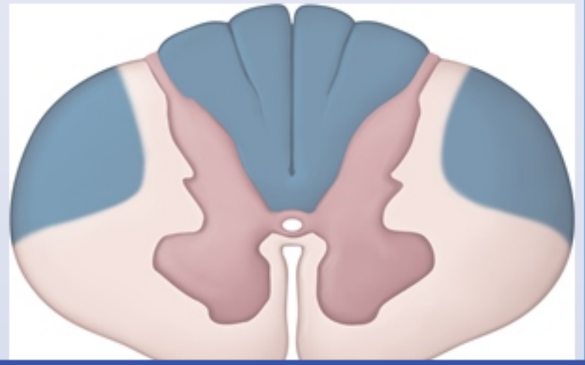

6
7
8
9
10
11
12
13
14
15
16
17
18
19
20
21
22
23
24
25
26
27
28
29
30
31
32
33
34
35
36

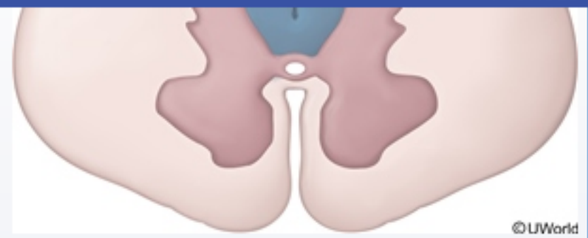

D.

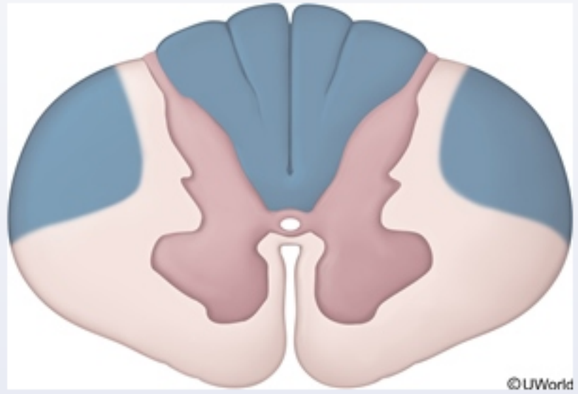

E.

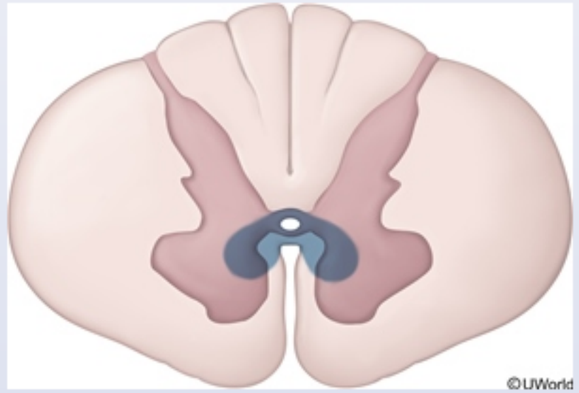

Submit

6
7
8
9
10
11
12
13
14
15
16
17
18
19
20
21
22
23
24
25
26
27
28
29
30
31
32
33
34
35
36

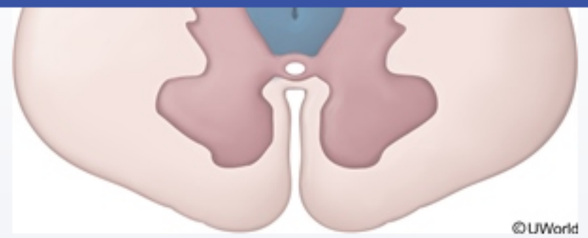

D. (70%)

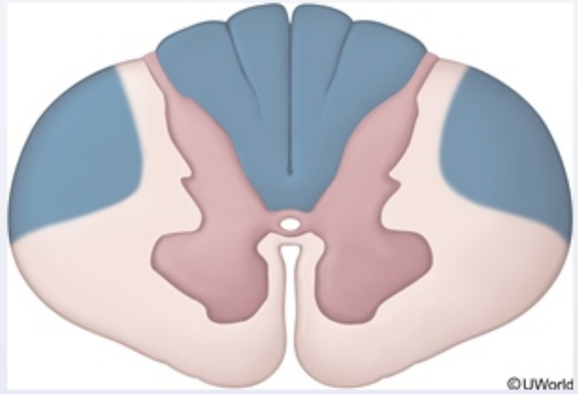

E. (3%)

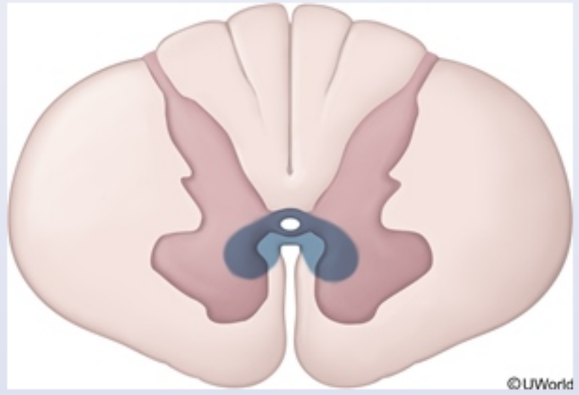

Omitted
Correct answer

70%
Answered correctly

08 secs
Time Spent

01/15/2020
Last Updated

6
7
8
9
10
11
12
13
14
15
16
17
18
19
20
21
22
23
24
25
26
27
28
29
30
31
32
33
34
35
36

Subacute combined degeneration (B_{12} deficiency)

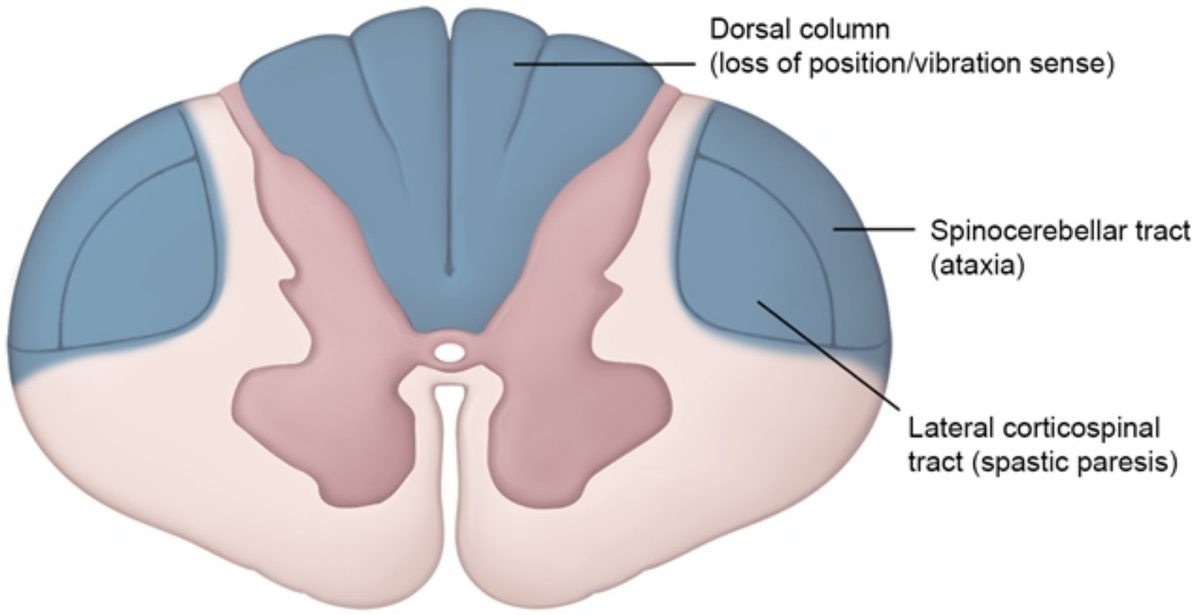

©UWorld

This patient is most likely suffering from **subacute combined degeneration** of the spinal cord, a condition that results from chronically low levels of vitamin B_{12} (cobalamin). Low cobalamin levels may occur due to pernicious anemia (autoimmune gastritis with deficient intrinsic factor), **gastrectomy**, ileal resections, infection by the tapeworm *Diphyllobothrium latum*, and strict vegan diets containing no animal products for a prolonged period (4-5 years).

Anemia along with neurologic abnormalities is typical of **vitamin B_{12} deficiency**. Vitamin B_{12} is an important cofactor in DNA synthesis; therefore, hematologic manifestations of vitamin B_{12} deficiency include megaloblastic anemia and pancytopenia. Elevated levels of methylmalonic acid also result in myelin synthesis abnormalities. Neurologic damage associated with vitamin B_{12} deficiency classically includes subacute combined degeneration of the **dorsal columns** (loss of position and vibration sensation, sensory ataxia [positive Romberg sign]), **lateral corticospinal tracts** (spastic paresis), and spinocerebellar tracts (contributes to ataxia). Patients may also develop atrophic glossitis, which appears as a

6
7
8
9
10
11
12
13
14
15
16
17
18
19
20
21
22
23
24
25
26
27
28
29
30
31
32
33
34
35
36

gastrectomy, ileal resections, infection by the tapeworm *Diphyllobothrium latum*, and strict vegan diets containing no animal products for a prolonged period (4-5 years).

Anemia along with neurologic abnormalities is typical of **vitamin B_{12} deficiency**. Vitamin B_{12} is an important cofactor in DNA synthesis; therefore, hematologic manifestations of vitamin B_{12} deficiency include megaloblastic anemia and pancytopenia. Elevated levels of methylmalonic acid also result in myelin synthesis abnormalities. Neurologic damage associated with vitamin B_{12} deficiency classically includes subacute combined degeneration of the **dorsal columns** (loss of position and vibration sensation, sensory ataxia [positive Romberg sign]), **lateral corticospinal tracts** (spastic paresis), and spinocerebellar tracts (contributes to ataxia). Patients may also develop atrophic glossitis, which appears as a smooth, shiny, erythematous tongue.

(Choice A) Poliomyelitis and Werdnig-Hoffmann disease are associated with destruction of lower motor neurons in the anterior horn, which causes flaccid paralysis, muscle atrophy, and fasciculations.

(Choice B) Multiple sclerosis is an inflammatory demyelinating disorder affecting the white matter of the central nervous system in a random and asymmetric pattern. Patients typically present with neurologic deficits disseminated in space and time.

(Choice C) Tabes dorsalis (tertiary neurosyphilis) is characterized by degeneration of the dorsal root ganglia and dorsal columns. Although patients may have impaired vibratory sensation and proprioception, pancytopenia and atrophic glossitis are not characteristic. In addition, tabes dorsalis does not typically affect the lateral corticospinal tracts.

(Choice E) Syringomyelia is a central cavitation of the cervical spinal cord that is associated with damage to the anterior white commissure of the spinothalamic tract. Patients typically have bilateral loss of pain/temperature in the upper extremities. Expansion into the ventral horns may result in flaccid paralysis of the hand muscles.

Educational objective:
Neurologic damage associated with vitamin B_{12} deficiency classically includes subacute combined degeneration of the dorsal columns (loss of position and vibration sensation, positive Romberg sign) and lateral corticospinal tracts (spastic paresis).

References

- Reversible myelopathy with vitamin B12 deficiency.

Anatomy Nervous System Vitamin b12 deficiency

6
7
8
9
10
11
12
13
14
15
16
17
18
19
20
21
22
23
24
25
26
27
28
29
30
31
32
33
34
35
36

A 55-year-old, right-handed man comes to the emergency department due to recent onset of severe, throbbing, right-sided headache and double vision. His medical history includes poorly controlled hypertension and chronic tobacco use. Neurologic examination shows that he is awake, alert, and oriented and can follow commands. Visual fields and optic fundi are normal. The position of the right eye is down and out with ipsilateral ptosis, and the right pupil is dilated and nonreactive to both light and accommodation. Left eye examination is normal. Based on this patient's neurologic deficits, CT angiography of the head is most likely to reveal an aneurysm arising from which of the following locations in the image below?

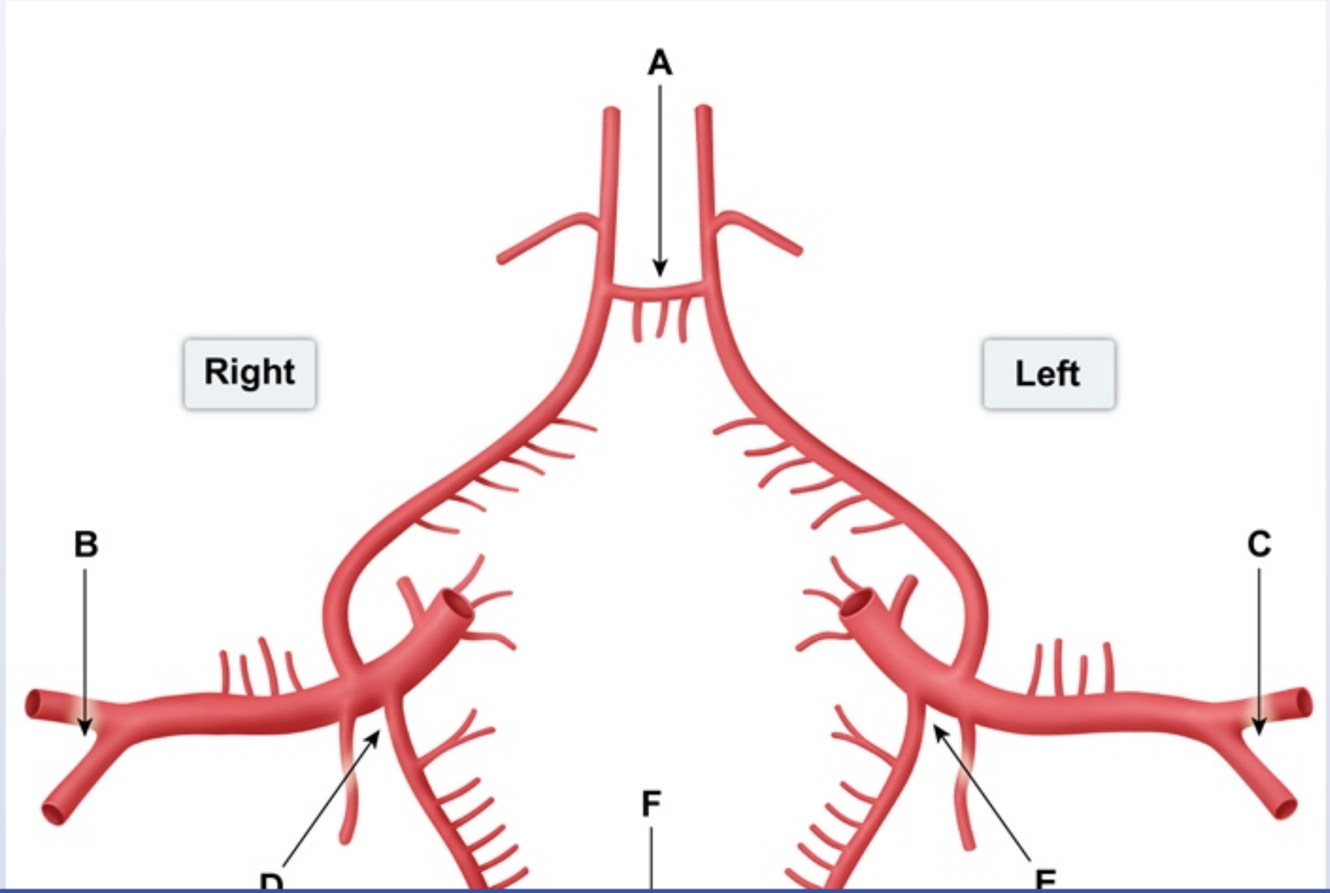

6
7
8
9
10
11
12
13
14
15
16
17
18
19
20
21
22
23
24
25
26
27
28
29
30
31
32
33
34
35
36

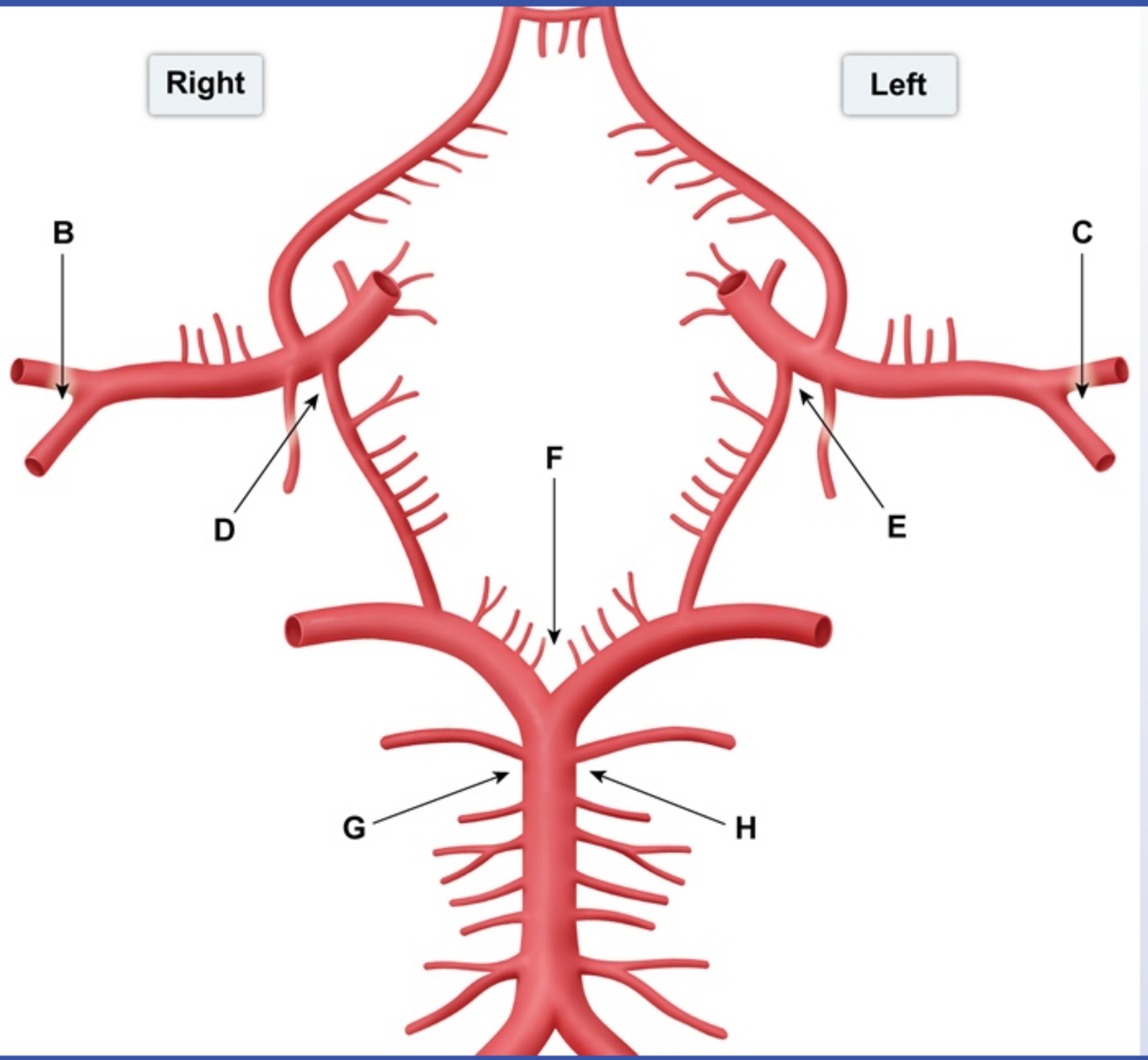

6
7
8
9
10
11
12
13
14
15
16
17
18
19
20
21
22
23
24
25
26
27
28
29
30
31
32
33
34
35
36

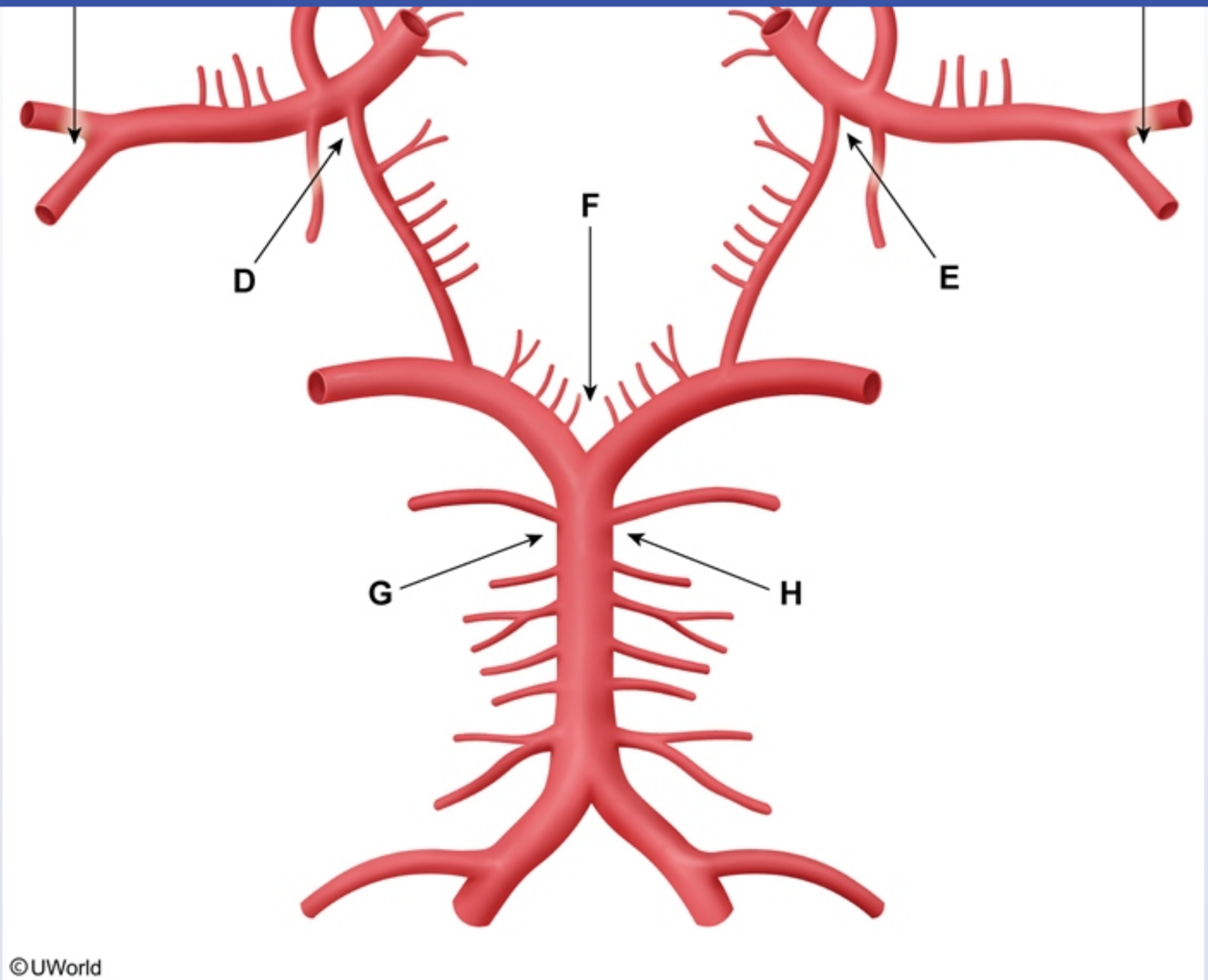

A. A

B. B

6
7
8
9
10
11
12
13
14
15
16
17
18
19
20
21
22
23
24
25
26
27
28
29
30
31
32
33
34
35
36

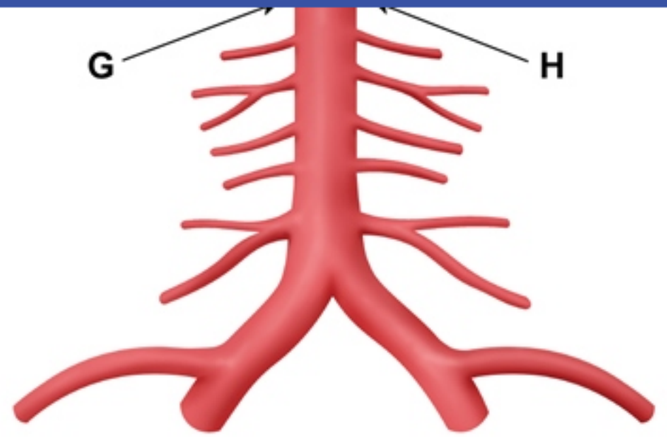

©UWorld

A. A

B. B

C. C

D. D

E. E

F. F

G. G

H. H

Submit

6
7
8
9
10
11
12
13
14
15
16
17
18
19
20
21
22
23
24
25
26
27
28
29
30
31
32
33
34
35
36

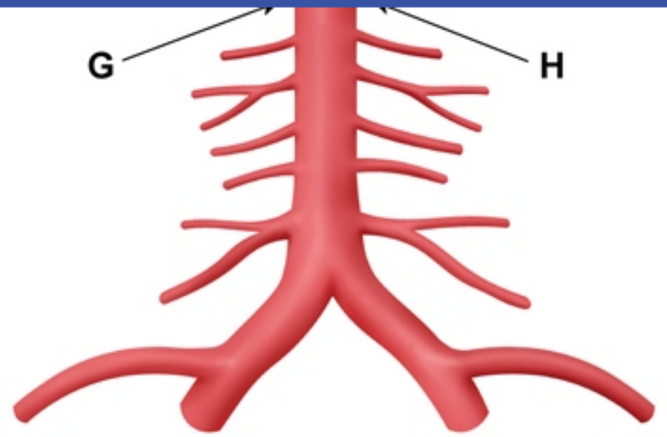

©UWorld

A. A (10%)
B. B (6%)
C. C (2%)
✓ D. D (45%)
E. E (10%)
F. F (6%)
G. G (14%)
H. H (4%)

Omitted
Correct answer

45%
Answered correctly

12 secs
Time Spent

05/25/2020
Last Updated

6
7
8
9
10
11
12
13
14
15
16
17
18
19
20
21
22
23
24
25
26
27
28
29
30
31
32
33
34
35
36

Berry (saccular) aneurysms

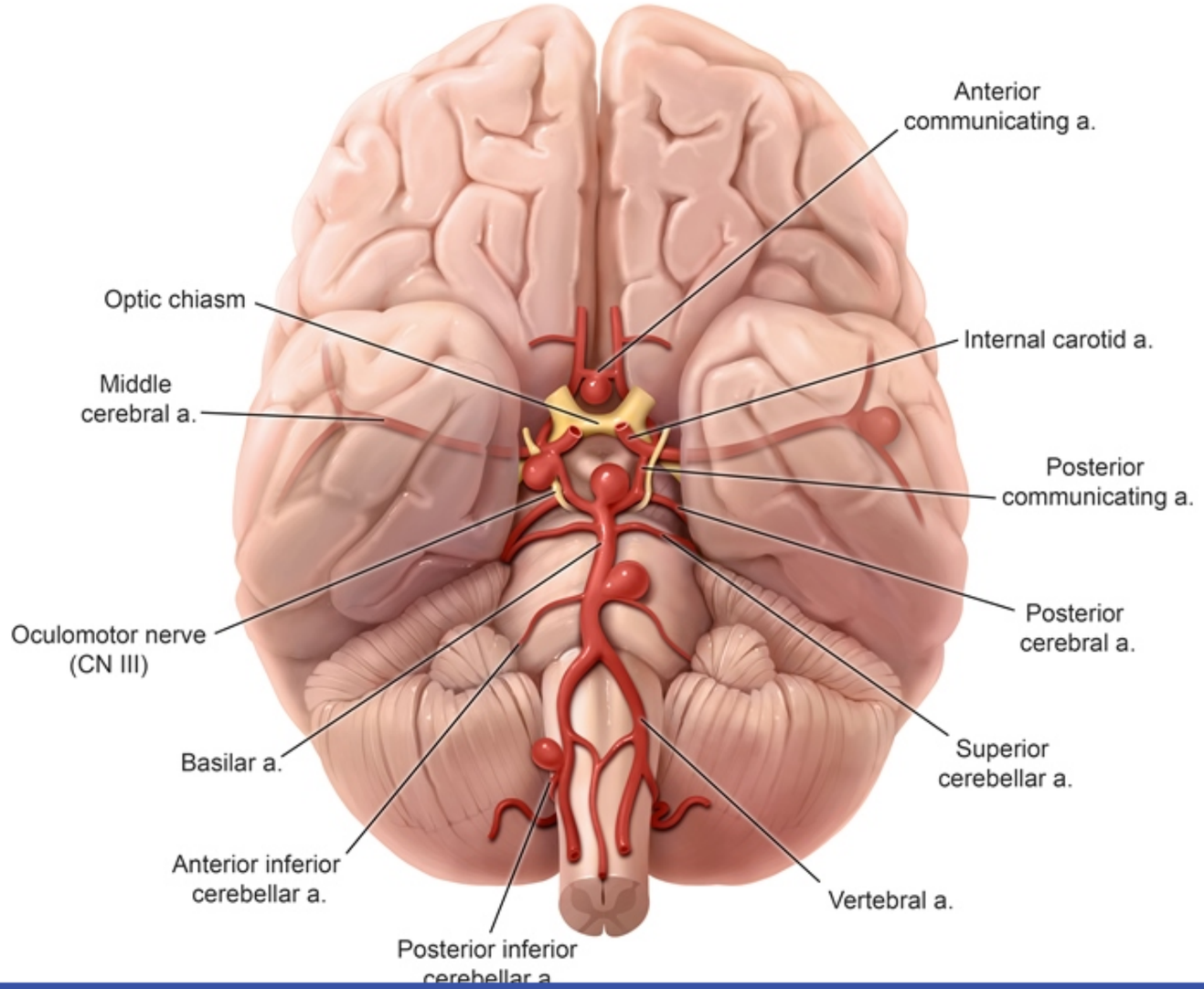

6
7
8
9
10
11
12
13
14
15
16
17
18
19
20
21
22
23
24
25
26
27
28
29
30
31
32
33
34
35
36

This patient has right **oculomotor nerve (CN III) palsy** secondary to a compressive **aneurysm** arising from the junction of the right **posterior communicating artery** with the internal carotid artery. Saccular aneurysms typically arise from branch points on the circle of Willis, and most (85%) affect the anterior circulation (eg, anterior communicating, posterior communicating, and middle cerebral arteries). Chronic smoking and poorly controlled hypertension are risk factors. Unruptured aneurysms are usually asymptomatic, but patients may experience headache and cranial neuropathies due to mass effect.

CN III is a pure motor nerve that exits the midbrain between the posterior cerebral and superior cerebellar arteries and courses along the posterior communicating artery, making it particularly susceptible to injury from posterior communicating artery aneurysms. It carries general visceral efferent fibers on its surface (for the pupillary light and near-reflex pathways) and general somatic efferent fibers within its interior (innervating superior rectus, inferior rectus, medial rectus, inferior oblique, and levator palpebrae superioris muscles). Consequently, aneurysmal compression of CN III produces **mydriasis** (due to superficial parasympathetic fiber damage) with diplopia, **ptosis**, and **down and out deviation** of the ipsilateral eye (due to somatic efferent fiber injury).

(Choice A) The junction of the anterior communicating artery and anterior cerebral artery is the most common location for saccular aneurysms; however, aneurysms in this region typically compress the central optic chiasm, causing bitemporal hemianopia.

(Choices B and C) Saccular aneurysms of the middle cerebral artery typically occur at its distal bifurcation and do not usually affect the oculomotor nerve.

(Choice E) Posterior communicating artery aneurysms cause symptoms on the same side as the lesion due to damage to the ipsilateral oculomotor nerve. A left posterior communicating artery aneurysm would cause left-sided mydriasis, ptosis, and eye deviation.

(Choices F, G, and H) Approximately 15% of saccular aneurysms arise from the posterior circulation (eg, branches of the basilar and vertebral arteries). Although these aneurysms could potentially cause oculomotor palsy by compressing the oculomotor nerve as it exits the midbrain, this presentation is rare and usually associated only with very large aneurysms that cause multiple neurologic deficits.

Educational objective:
The oculomotor nerve (CN III) is most susceptible to injury from ipsilateral posterior communicating artery aneurysms. Aneurysmal compression of CN III produces mydriasis (due to superficial parasympathetic fiber damage) with diplopia, ptosis, and down and out deviation of the ipsilateral eye (due to somatic efferent fiber injury).

References

6
7
8
9
10
11
12
13
14
15
16
17
18
19
20
21
22
23
24
25
26
27
28
29
30
31
32
33
34
35
36

superior rectus, inferior rectus, medial rectus, inferior oblique, and levator palpebrae superioris muscles). Consequently, aneurysmal compression of CN III produces **mydriasis** (due to superficial parasympathetic fiber damage) with diplopia, **ptosis**, and **down and out deviation** of the ipsilateral eye (due to somatic efferent fiber injury).

(Choice A) The junction of the anterior communicating artery and anterior cerebral artery is the most common location for saccular aneurysms; however, aneurysms in this region typically compress the central optic chiasm, causing bitemporal hemianopia.

(Choices B and C) Saccular aneurysms of the middle cerebral artery typically occur at its distal bifurcation and do not usually affect the oculomotor nerve.

(Choice E) Posterior communicating artery aneurysms cause symptoms on the same side as the lesion due to damage to the ipsilateral oculomotor nerve. A left posterior communicating artery aneurysm would cause left-sided mydriasis, ptosis, and eye deviation.

(Choices F, G, and H) Approximately 15% of saccular aneurysms arise from the posterior circulation (eg, branches of the basilar and vertebral arteries). Although these aneurysms could potentially cause oculomotor palsy by compressing the oculomotor nerve as it exits the midbrain, this presentation is rare and usually associated only with very large aneurysms that cause multiple neurologic deficits.

Educational objective:
The oculomotor nerve (CN III) is most susceptible to injury from ipsilateral posterior communicating artery aneurysms. Aneurysmal compression of CN III produces mydriasis (due to superficial parasympathetic fiber damage) with diplopia, ptosis, and down and out deviation of the ipsilateral eye (due to somatic efferent fiber injury).

References

- Aneurysms of the posterior communicating artery and oculomotor paresis.
- Intracranial aneurysms: current evidence and clinical practice.

Anatomy	Nervous System	Cranial nerve palsy
Subject	System	Topic

Copyright © UWorld. All rights reserved.

6
7
8
9
10
11
12
13
14
15
16
17
18
19
20
21
22
23
24
25
26
27
28
29
30
31
32
33
34
35
36

Oculomotor nerve

Posterior cerebral a

Exhibit Display

Aneurysmal compression of oculomotor nerve

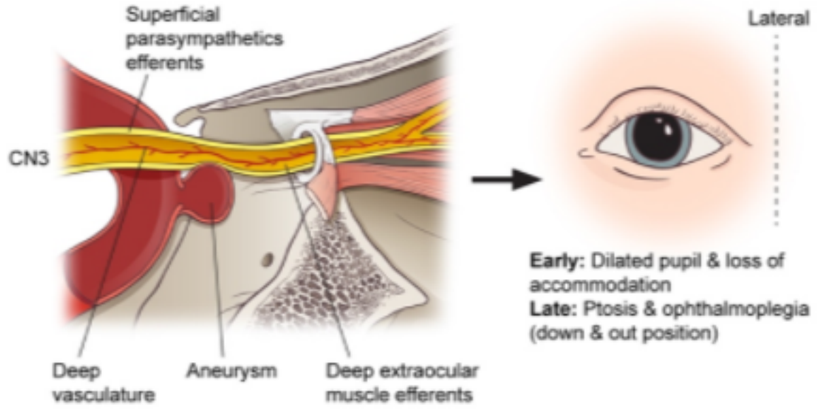

Diabetic ophthalmoplegia

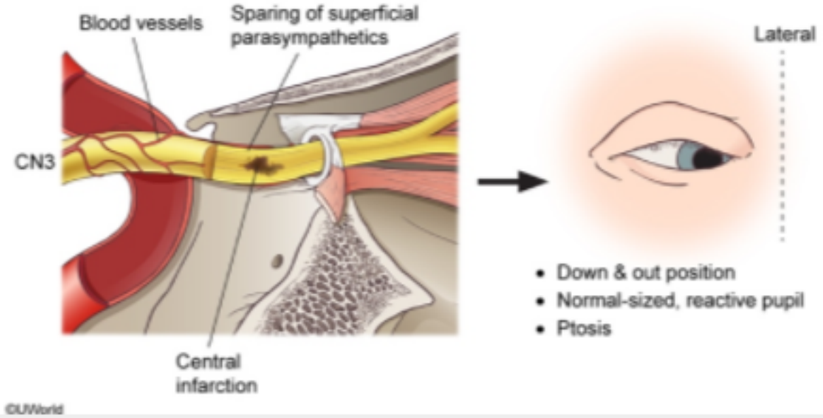

Zoom In | Zoom Out | Reset | Add To New Card | Existing Card

6
7
8
9
10
11
12
13
14
15
16
17
18
19
20
21
22
23
24
25
26
27
28
29
30
31
32
33
34
35
36

A 65-year-old man is brought to the emergency department due to acute mental status changes. The patient was having dinner with his family when he suddenly had difficulty using his fork and appeared confused. His medical problems include type 2 diabetes mellitus, hyperlipidemia, and hypertension. He is a school teacher and has a 40-pack-year smoking history. His blood pressure is 180/98 mm Hg and pulse is 98/min and regular. On physical examination, the patient is well oriented, answers questions appropriately, and has no motor, sensory, or visual deficits. Further evaluation shows that he has left-right disorientation and is unable to carry out simple calculations, read, or write. Noncontrast CT scan of the head reveals no acute intracranial hemorrhage. Which of the following brain areas is most likely affected in this patient?

A. Bilateral occipital lobes
B. Dominant parietal lobe
C. Dorsolateral medulla
D. Dorsolateral thalamus
E. Medial medulla
F. Midbrain at level of superior colliculus

Submit

6
7
8
9
10
11
12
13
14
15
16
17
18
19
20
21
22
23
24
25
26
27
28
29
30
31
32
33
34
35
36

A 65-year-old man is brought to the emergency department due to acute mental status changes. The patient was having dinner with his family when he suddenly had difficulty using his fork and appeared confused. His medical problems include type 2 diabetes mellitus, hyperlipidemia, and hypertension. He is a school teacher and has a 40-pack-year smoking history. His blood pressure is 180/98 mm Hg and pulse is 98/min and regular. On physical examination, the patient is well oriented, answers questions appropriately, and has no motor, sensory, or visual deficits. Further evaluation shows that he has left-right disorientation and is unable to carry out simple calculations, read, or write. Noncontrast CT scan of the head reveals no acute intracranial hemorrhage. Which of the following brain areas is most likely affected in this patient?

- A. Bilateral occipital lobes (1%)
- ✓ B. Dominant parietal lobe (87%)
- C. Dorsolateral medulla (1%)
- D. Dorsolateral thalamus (5%)
- E. Medial medulla (0%)
- F. Midbrain at level of superior colliculus (3%)

Omitted
Correct answer
B

87%
Answered correctly

02 secs
Time Spent

05/10/2020
Last Updated

Explanation

Gerstmann syndrome

6
7
8
9
10
11
12
13
14
15
16
17
18
19
20
21
22
23
24
25
26
27
28
29
30
31
32
33
34
35
36

Gerstmann syndrome

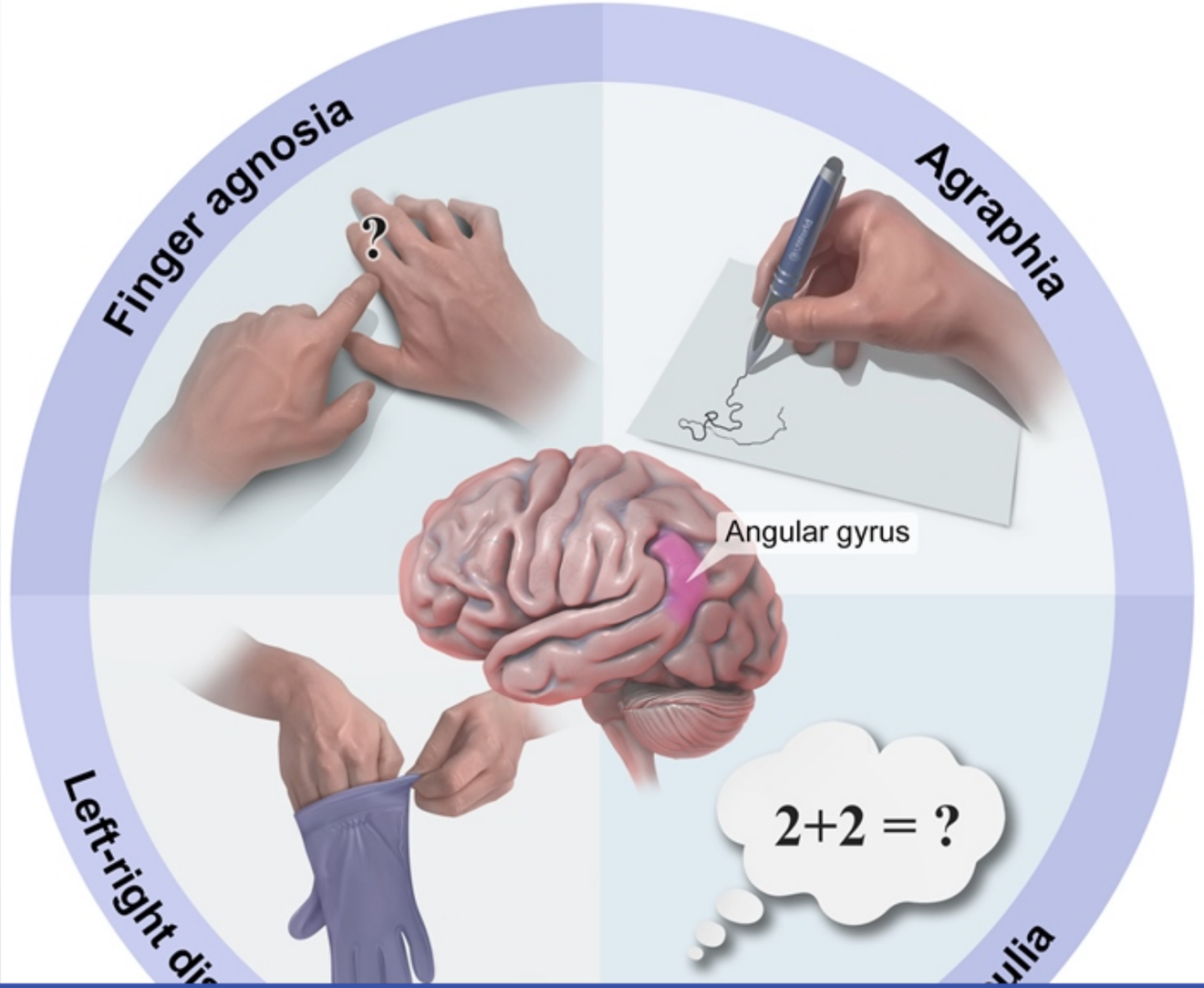

6
7
8
9
10
11
12
13
14
15
16
17
18
19
20
21
22
23
24
25
26
27
28
29
30
31
32
33
34
35
36

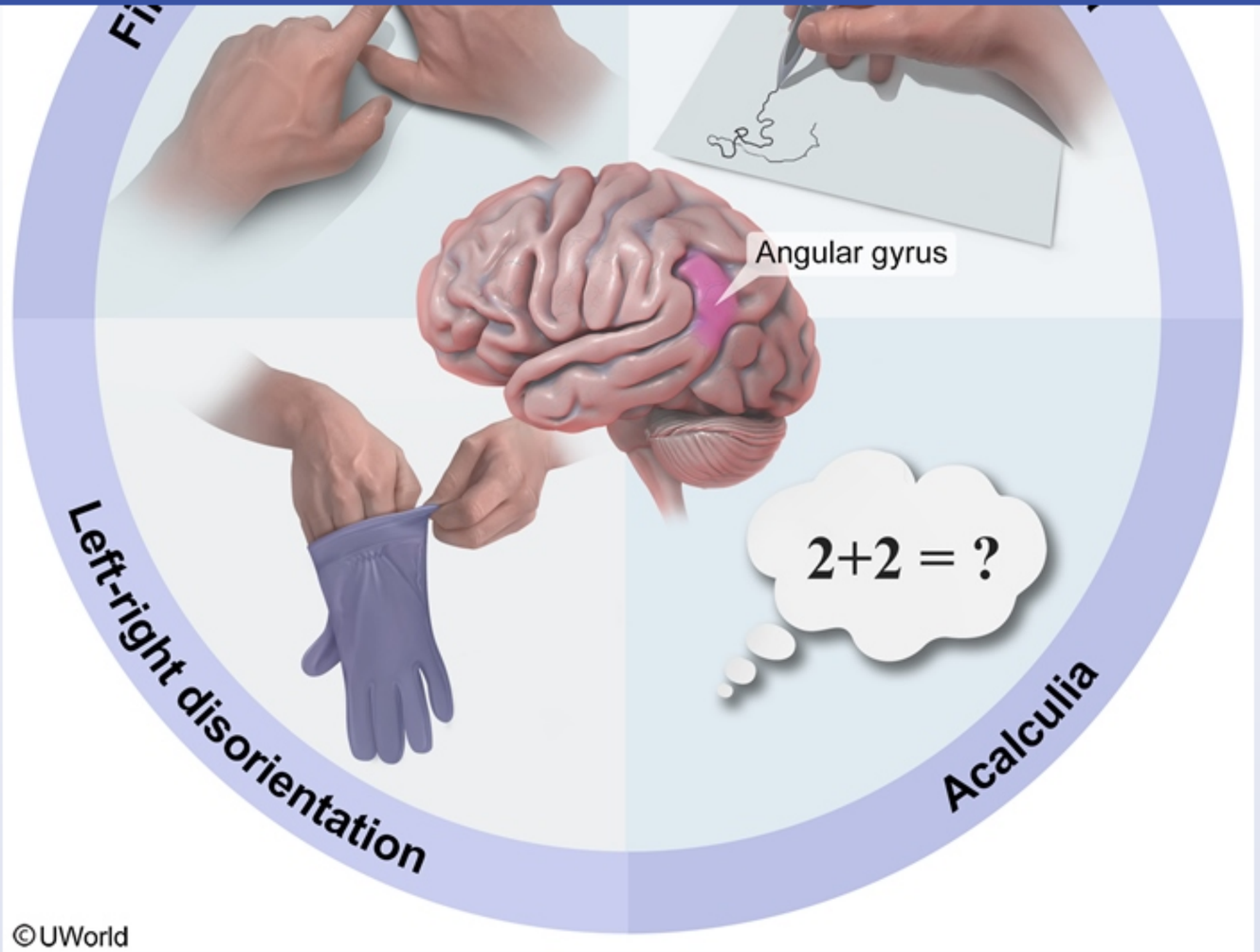

This patient's presentation is consistent with an acute ischemic stroke affecting the **angular gyrus** of the **dominant parietal lobe**, a brain region supplied by the middle cerebral artery. The angular gyrus is part of the parietal association cortex, an area that integrates multisensory (eg, visual, tactile, verbal) information to comprehend events and solve problems. Specifically, it is important for semantic processing, word reading and comprehension, and number processing. Damage to this area classically results in **Gerstmann syndrome**, a neurologic disorder characterized

6
7
8
9
10
11
12
13
14
15
16
17
18
19
20
21
22
23
24
25
26
27
28
29
30
31
32
33
34
35
36

This patient's presentation is consistent with an acute ischemic stroke affecting the **angular gyrus** of the **dominant parietal lobe**, a brain region supplied by the middle cerebral artery. The angular gyrus is part of the parietal association cortex, an area that integrates multisensory (eg, visual, tactile, verbal) information to comprehend events and solve problems. Specifically, it is important for semantic processing, word reading and comprehension, and number processing. Damage to this area classically results in **Gerstmann syndrome**, a neurologic disorder characterized by a constellation of the following signs:

1. Agraphia (inability to write)
2. Acalculia (inability to carry out mathematical calculations)
3. Finger agnosia (inability to identify individual fingers on the hand)
4. Left-right disorientation

Although Gerstmann syndrome may occur as an isolated syndrome, lesions to the angular gyrus may also be associated with alexia (inability to read) and aphasia (impaired speech).

(Choice A) Damage to the bilateral occipital lobes can result in cortical blindness. Despite their obvious deficits, patients with this condition may confabulate and deny blindness.

(Choice C) Ischemic injury to the dorsolateral medulla, which is supplied by the posterior inferior cerebellar artery, can result in Wallenberg syndrome. Patients typically present with loss of pain/temperature over the ipsilateral face and contralateral body (due to damage of the spinal trigeminal and spinothalamic tracts), ipsilateral bulbar muscle weakness (nucleus ambiguus), vertigo (vestibular nuclei), ipsilateral limb ataxia (inferior cerebellar peduncle), and Horner syndrome (descending sympathetic fibers).

(Choice D) Acute strokes in the dorsolateral thalamus typically present with contralateral hemisensory loss. Weeks to months later, patients can develop excruciating pain on the side of their deficits (thalamic pain syndrome).

(Choice E) Medial medullary syndrome is an ischemic stroke syndrome caused by occlusion of the anterior spinal artery. Patients typically present with contralateral hemiparesis (due to damage of the lateral corticospinal tract), contralateral hemisensory loss (dorsal column medial lemniscal pathway), and ipsilateral tongue paralysis (hypoglossal nucleus).

(Choice F) Midbrain strokes at the level of the superior colliculus can result in upward gaze palsy, absent pupillary light reflex, and impaired convergence (Parinaud syndrome).

6
7
8
9
10
11
12
13
14
15
16
17
18
19
20
21
22
23
24
25
26
27
28
29
30
31
32
33
34
35
36

confabulate and deny blindness.

(Choice C) Ischemic injury to the dorsolateral medulla, which is supplied by the posterior inferior cerebellar artery, can result in Wallenberg syndrome. Patients typically present with loss of pain/temperature over the ipsilateral face and contralateral body (due to damage of the spinal trigeminal and spinothalamic tracts), ipsilateral bulbar muscle weakness (nucleus ambiguus), vertigo (vestibular nuclei), ipsilateral limb ataxia (inferior cerebellar peduncle), and Horner syndrome (descending sympathetic fibers).

(Choice D) Acute strokes in the dorsolateral thalamus typically present with contralateral hemisensory loss. Weeks to months later, patients can develop excruciating pain on the side of their deficits (thalamic pain syndrome).

(Choice E) Medial medullary syndrome is an ischemic stroke syndrome caused by occlusion of the anterior spinal artery. Patients typically present with contralateral hemiparesis (due to damage of the lateral corticospinal tract), contralateral hemisensory loss (dorsal column medial lemniscal pathway), and ipsilateral tongue paralysis (hypoglossal nucleus).

(Choice F) Midbrain strokes at the level of the superior colliculus can result in upward gaze palsy, absent pupillary light reflex, and impaired convergence (Parinaud syndrome).

Educational objective:
Gerstmann syndrome results from damage to the angular gyrus of the dominant parietal lobe and is characterized by agraphia (inability to write), acalculia (inability to carry out mathematical calculations), finger agnosia (inability to identify individual fingers on the hand), and left-right disorientation.

References

- Gerstmann'S syndrome in acute stroke patients.
- A proposed reinterpretation of Gerstmann's syndrome.

Anatomy	Nervous System	Ischemic stroke
Subject	System	Topic

Copyright © UWorld. All rights reserved.

6
7
8
9
10
11
12
13
14
15
16
17
18
19
20
21
22
23
24
25
26
27
28
29
30
31
32
33
34
35
36

A 36-year-old woman comes to the office due to firm, nontender swelling of her right cheek for the past 4 months. The patient has had no fever, runny nose, sore throat, or cough. She drinks a glass of wine with dinner on most nights but does not use tobacco. Physical examination shows fullness of the preauricular space on the right side. An MRI of the region identifies a 2.2-cm mass in the right parotid gland, and a follow-up core needle biopsy shows the lesion to be neoplastic. If left untreated, this patient is most likely to develop which of the following?

A. Bitemporal hemianopsia
B. Facial droop
C. Facial numbness
D. Hoarseness
E. Horner syndrome
F. Strabismus

Submit

6
7
8
9
10
11
12
13
14
15
16
17
18
19
20
21
22
23
24
25
26
27
28
29
30
31
32
33
34
35
36

A 36-year-old woman comes to the office due to firm, nontender swelling of her right cheek for the past 4 months. The patient has had no fever, runny nose, sore throat, or cough. She drinks a glass of wine with dinner on most nights but does not use tobacco. Physical examination shows fullness of the preauricular space on the right side. An MRI of the region identifies a 2.2-cm mass in the right parotid gland, and a follow-up core needle biopsy shows the lesion to be neoplastic. If left untreated, this patient is most likely to develop which of the following?

- A. Bitemporal hemianopsia (0%)
- ✓ B. Facial droop (69%)
- C. Facial numbness (19%)
- D. Hoarseness (4%)
- E. Horner syndrome (4%)
- F. Strabismus (0%)

Omitted
Correct answer
B

69%
Answered correctly

02 secs
Time Spent

05/25/2020
Last Updated

Explanation

Peripheral facial palsy



6
7
8
9
10
11
12
13
14
15
16
17
18
19
20
21
22
23
24
25
26
27
28
29
30
31
32
33
34
35
36

Peripheral facial palsy

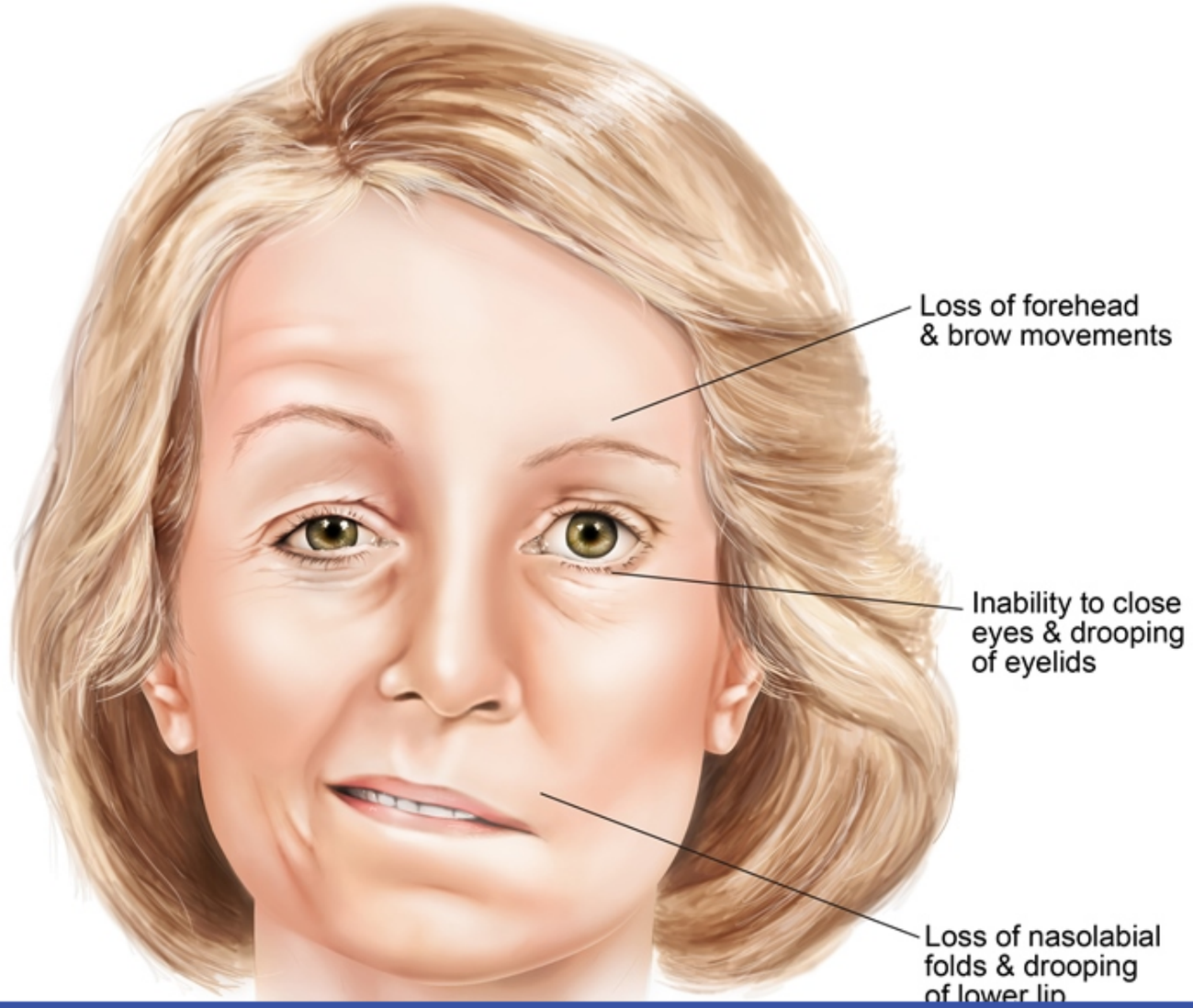

6
7
8
9
10
11
12
13
14
15
16
17
18
19
20
21
22
23
24
25
26
27
28
29
30
31
32
33
34
35
36

The **extracranial** portion of the **facial nerve (CN VII)** carries motor innervation to the muscles of facial expression. This nerve exits the skull through the **stylomastoid foramen** and courses within the substance of the parotid gland. Within this gland, the facial nerve divides into its 5 terminal branches (temporal, zygomatic, buccal, mandibular, and cervical). Parotid gland tumors can compress and disrupt the ipsilateral facial nerve and its branches, causing **facial droop**. In fact, most parotid gland tumors causing facial nerve paralysis are **malignant** neoplasms.

(Choice A) Bitemporal hemianopsia typically results from tumors (eg, craniopharyngioma, pituitary adenoma) within the sella turcica that compress the optic chiasm.

(Choice C) The trigeminal nerve (via its 3 branches) provides sensation to the face and motor innervation to the muscles of mastication. This nerve follows a deep course and is unlikely to be damaged by a tumor of the parotid gland.

(Choice D) The recurrent laryngeal nerve is a branch of the vagus nerve that loops below the aortic arch on the left and below the subclavian artery on the right to provide motor innervation to the laryngeal muscles. During **thyroid surgery**, this nerve may be damaged due to its proximity to the inferior thyroid artery. Unilateral nerve injury often causes hoarseness, whereas bilateral injury may cause inspiratory stridor and respiratory distress due to complete **vocal cord paralysis**.

(Choice E) Horner syndrome presents with partial ptosis, miosis, and anhidrosis due to interruption of the sympathetic innervation to the head. This can occur with lesions affecting the lateral hypothalamus, hypothalamospinal tract, paravertebral sympathetic chain/stellate ganglion (eg, Pancoast tumor), or internal carotid artery (eg, carotid dissection).

(Choice F) Strabismus (improper alignment of the eyes) can result from disorders of the extraocular muscles or the nerves that innervate them (CN III, IV, or VI).

Educational objective:
The facial nerve (CN VII) exits the stylomastoid foramen and courses through the substance of the parotid gland, where it divides into its 5 terminal branches that innervate the muscles of facial expression. Malignant tumors of the parotid gland often compress and disrupt the facial nerve and its branches, causing ipsilateral facial droop.

References

- The presence of facial nerve weakness on diagnosis of a parotid gland malignant process.
- Parotid gland tumors and the facial nerve.

6
7
8
9
10
11
12
13
14
15
16
17
18
19
20
21
22
23
24
25
26
27
28
29
30
31
32
33
34
35
36

compress the optic chiasm.

(Choice C) The trigeminal nerve (via its 3 branches) provides sensation to the face and motor innervation to the muscles of mastication. This nerve follows a deep course and is unlikely to be damaged by a tumor of the parotid gland.

(Choice D) The recurrent laryngeal nerve is a branch of the vagus nerve that loops below the aortic arch on the left and below the subclavian artery on the right to provide motor innervation to the laryngeal muscles. During **thyroid surgery**, this nerve may be damaged due to its proximity to the inferior thyroid artery. Unilateral nerve injury often causes hoarseness, whereas bilateral injury may cause inspiratory stridor and respiratory distress due to complete **vocal cord paralysis**.

(Choice E) Horner syndrome presents with partial ptosis, miosis, and anhidrosis due to interruption of the sympathetic innervation to the head. This can occur with lesions affecting the lateral hypothalamus, hypothalamospinal tract, paravertebral sympathetic chain/stellate ganglion (eg, Pancoast tumor), or internal carotid artery (eg, carotid dissection).

(Choice F) Strabismus (improper alignment of the eyes) can result from disorders of the extraocular muscles or the nerves that innervate them (CN III, IV, or VI).

Educational objective:
The facial nerve (CN VII) exits the stylomastoid foramen and courses through the substance of the parotid gland, where it divides into its 5 terminal branches that innervate the muscles of facial expression. Malignant tumors of the parotid gland often compress and disrupt the facial nerve and its branches, causing ipsilateral facial droop.

References

- The presence of facial nerve weakness on diagnosis of a parotid gland malignant process.
- Parotid gland tumors and the facial nerve.

Anatomy	Nervous System	Facial nerve
Subject	System	Topic

Copyright © UWorld. All rights reserved.

Inability to close

Exhibit Display

Parotid tumor compressing facial nerve

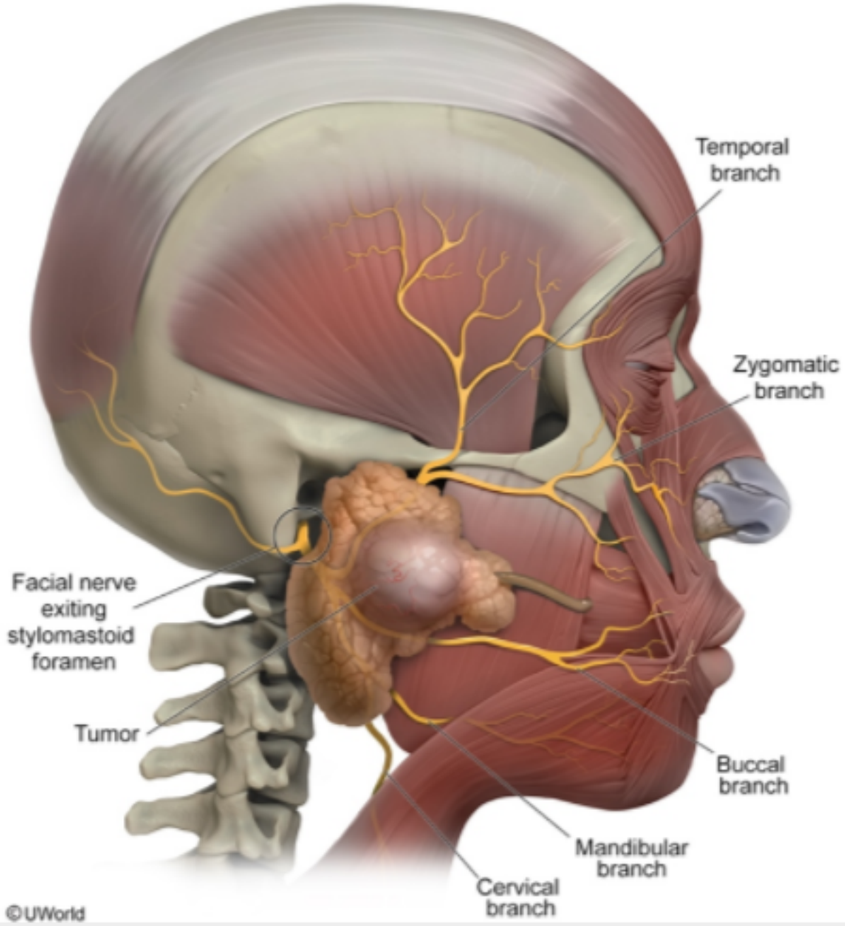

Zoom In | Zoom Out | Reset | Add To New Card | Existing Card

6
7
8
9
10
11
12
13
14
15
16
17
18
19
20
21
22
23
24
25
26
27
28
29
30
31
32
33
34
35
36

A 53-year-old man is evaluated for right hand discomfort. A month ago, he started to intermittently experience a "pins and needles" sensation in his right hand that is worse at night. He has no neck pain or history of trauma to the right upper extremity. The patient has smoked a pack of cigarettes daily for 20 years and has worked as an accountant for the past 30 years. On physical examination, there is loss of sensation over the right fifth digit. There is no swelling, redness, or warmth of the hand. The patient is most likely to have weakness of which of the following movements?

A. Elbow extension

B. Shoulder abduction

C. Wrist abduction

D. Wrist adduction

E. Wrist extension

Submit

6
7
8
9
10
11
12
13
14
15
16
17
18
19
20
21
22
23
24
25
26
27
28
29
30
31
32
33
34
35
36

A 53-year-old man is evaluated for right hand discomfort. A month ago, he started to intermittently experience a "pins and needles" sensation in his right hand that is worse at night. He has no neck pain or history of trauma to the right upper extremity. The patient has smoked a pack of cigarettes daily for 20 years and has worked as an accountant for the past 30 years. On physical examination, there is loss of sensation over the right fifth digit. There is no swelling, redness, or warmth of the hand. The patient is most likely to have weakness of which of the following movements?

- A. Elbow extension (4%)
- B. Shoulder abduction (0%)
- C. Wrist abduction (16%)
- ✓ D. Wrist adduction (63%)
- E. Wrist extension (14%)

Omitted
Correct answer
D

63%
Answered correctly

02 secs
Time Spent

02/13/2020
Last Updated

Explanation

Ulnar nerve
(anterior view)



6
7
8
9
10
11
12
13
14
15
16
17
18
19
20
21
22
23
24
25
26
27
28
29
30
31
32
33
34
35
36

Ulnar nerve
(anterior view)

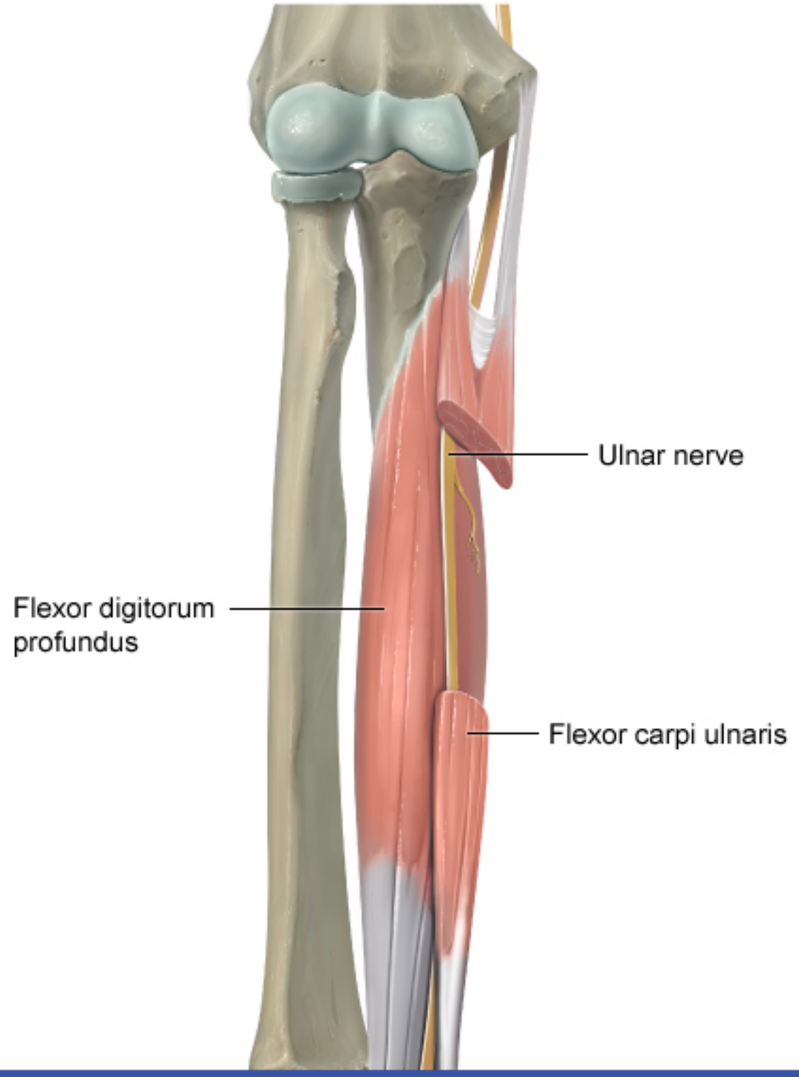

6
7
8
9
10
11
12
13
14
15
16
17
18
19
20
21
22
23
24
25
26
27
28
29
30
31
32
33
34
35
36

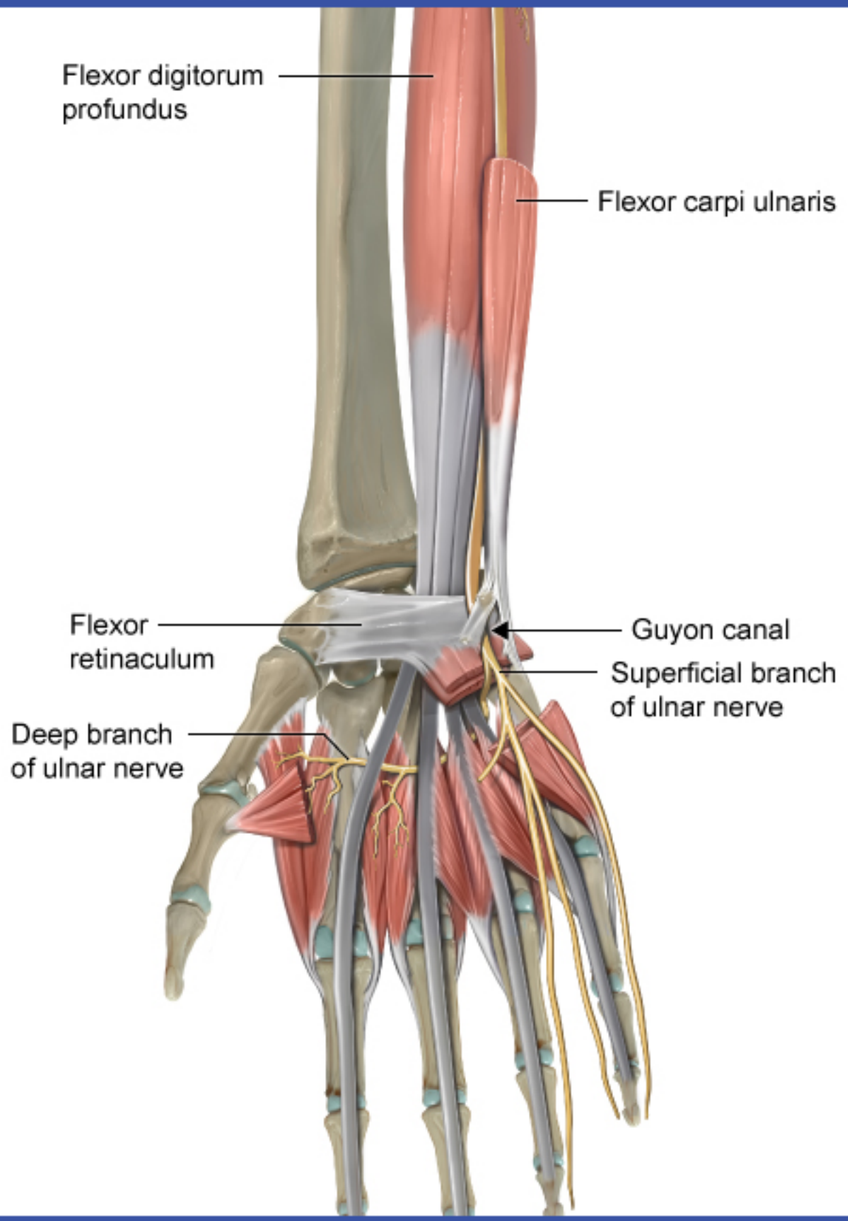

©UWorld

The **ulnar nerve** originates from the medial cord of the brachial plexus, courses with the brachial artery in the upper arm, and enters the forearm after passing posterior to the **medial epicondyle** of the humerus (cubital tunnel). It innervates flexor carpi ulnaris (wrist flexion and adduction) and the medial portion of flexor digitorum profundus before entering the wrist through Guyon canal (between the hook of the hamate and pisiform). In the hand, the superficial branch of the ulnar nerve provides cutaneous innervation to the **fifth digit**, medial half of the fourth digit, and the **hypothenar eminence**. The deep motor branch supplies most of the intrinsic muscles of the hand.

The ulnar nerve is most commonly injured at the elbow due to trauma (eg, medial epicondyle fracture) or **compression** (eg, resting on a hard surface while using a computer). Ulnar neuropathy at the elbow usually presents with discomfort and loss of sensation/paresthesia in the ulnar distribution. Severe cases can also result in **impaired wrist flexion and adduction** (ie, ulnar deviation) along with **finger weakness/clumsiness**. The nerve can also be injured more distally at the wrist as it runs through Guyon canal, resulting in more pronounced clawing of the 4th and 5th digits (ulnar claw) due to sparing of the flexor digitorum profundus.

(Choices A and E) Radial nerve injury (eg, C6/C7 disc herniation, humerus fracture) can result in weakness in elbow and/or wrist extension in addition to sensory loss over the posterior arm, dorsolateral hand, and dorsal thumb.

(Choice B) Axillary nerve injury (eg, shoulder dislocation, humeral fracture) can present with loss of sensation over the lateral upper arm and weakness in shoulder abduction (eg, deltoid weakness).

(Choice C) Proximal median nerve injury (eg, trauma) can result in weakness on wrist flexion and abduction (ie, radial deviation), flexion of the second/third digits, and flexion/opposition of the thumb along with palmar sensory loss involving the majority of the first through third digits.

Educational objective:
Ulnar nerve injury most commonly occurs at the elbow (eg, compression due to resting arm on a hard surface while using a computer) and usually presents with discomfort and sensory loss/paresthesia in the fifth digit, medial half of the fourth digit, and the hypothenar eminence. In severe cases, patients can also have weakness on wrist flexion and adduction (ie, ulnar deviation) along with finger weakness/clumsiness.

References

- Entrapment neuropathies I: upper limb (carpal tunnel excluded).
- Peripheral nerve entrapment and injury in the upper extremity.

6
7
8
9
10
11
12
13
14
15
16
17
18
19
20
21
22
23
24
25
26
27
28
29
30
31
32
33
34
35
36

the medial portion of flexor digitorum profundus before entering the wrist through Guyon canal (between the hook of the hamate and pisiform). In the hand, the superficial branch of the ulnar nerve provides cutaneous innervation to the **fifth digit**, medial half of the fourth digit, and the **hypothenar eminence**. The deep motor branch supplies most of the intrinsic muscles of the hand.

The ulnar nerve is most commonly injured at the elbow due to trauma (eg, medial epicondyle fracture) or **compression** (eg, resting on a hard surface while using a computer). Ulnar neuropathy at the elbow usually presents with discomfort and loss of sensation/paresthesia in the ulnar distribution. Severe cases can also result in **impaired wrist flexion and adduction** (ie, ulnar deviation) along with **finger weakness/clumsiness**. The nerve can also be injured more distally at the wrist as it runs through Guyon canal, resulting in more pronounced clawing of the 4th and 5th digits (ulnar claw) due to sparing of the flexor digitorum profundus.

(Choices A and E) Radial nerve injury (eg, C6/C7 disc herniation, humerus fracture) can result in weakness in elbow and/or wrist extension in addition to sensory loss over the posterior arm, dorsolateral hand, and dorsal thumb.

(Choice B) Axillary nerve injury (eg, shoulder dislocation, humeral fracture) can present with loss of sensation over the lateral upper arm and weakness in shoulder abduction (eg, deltoid weakness).

(Choice C) Proximal median nerve injury (eg, trauma) can result in weakness on wrist flexion and abduction (ie, radial deviation), flexion of the second/third digits, and flexion/opposition of the thumb along with palmar sensory loss involving the majority of the first through third digits.

Educational objective:
Ulnar nerve injury most commonly occurs at the elbow (eg, compression due to resting arm on a hard surface while using a computer) and usually presents with discomfort and sensory loss/paresthesia in the fifth digit, medial half of the fourth digit, and the hypothenar eminence. In severe cases, patients can also have weakness on wrist flexion and adduction (ie, ulnar deviation) along with finger weakness/clumsiness.

References

- Entrapment neuropathies I: upper limb (carpal tunnel excluded).
- Peripheral nerve entrapment and injury in the upper extremity.

Anatomy	Nervous System	Ulnar nerve neuropathy
Subject	System	Topic

the medial portion of flexor digitorum profundus before entering the wrist through Guyon canal (between the hook of the hamate and pisiform). In

Exhibit Display

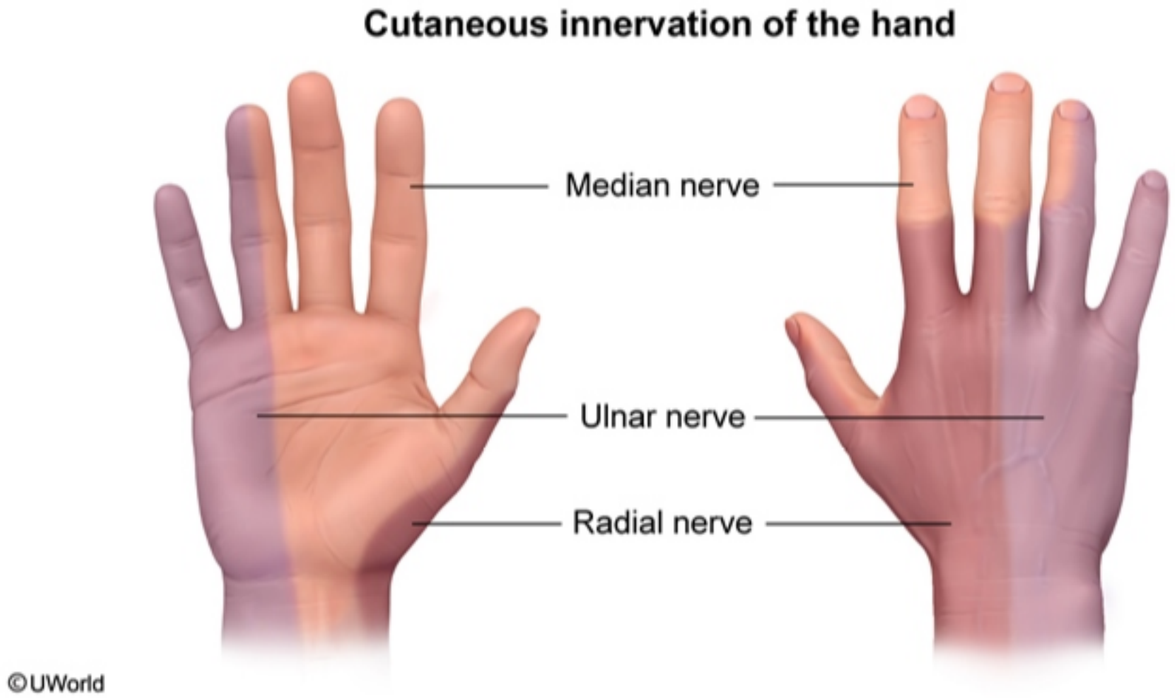

Zoom In | Zoom Out | Reset | Add To New Card | Existing Card

the medial portion of flexor digitorum profundus before entering the wrist through Guyon canal (between the hook of the hamate and pisiform). In

Exhibit Display

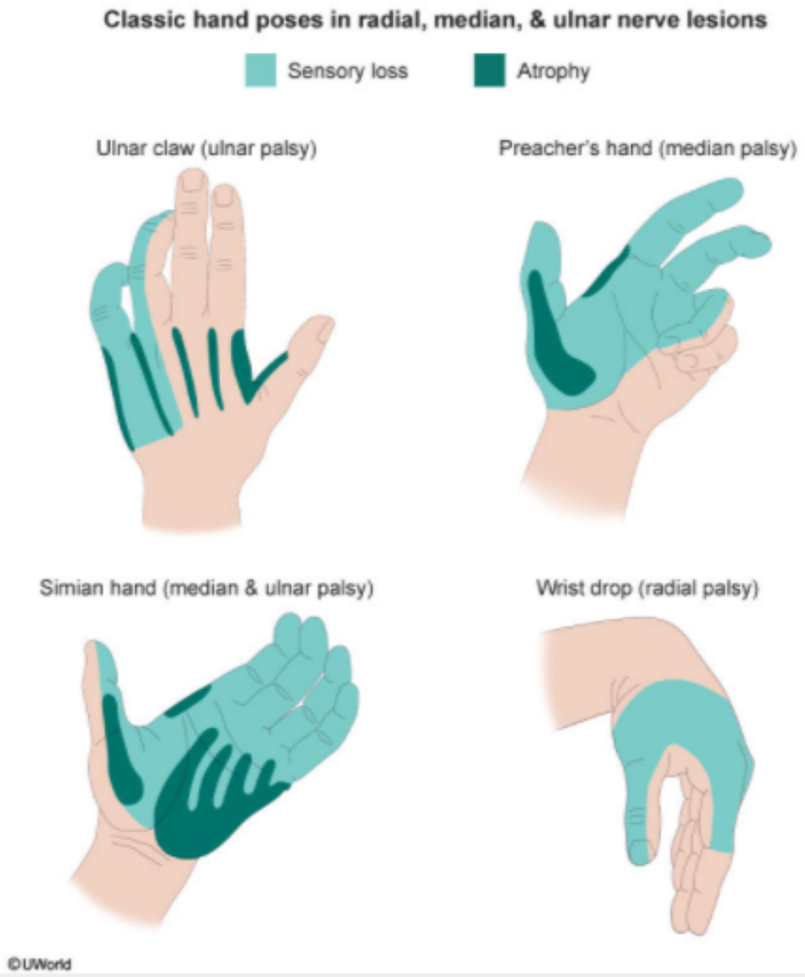

Zoom In | Zoom Out | Reset | Add To New Card | Existing Card

6
7
8
9
10
11
12
13
14
15
16
17
18
19
20
21
22
23
24
25
26
27
28
29
30
31
32
33
34
35
36

A 13-year-old boy comes to the office for a postoperative follow-up visit. He was seen in the emergency department 3 weeks earlier with acute abdominal pain and was found to have acute appendicitis. The patient underwent urgent appendectomy without any apparent immediate complications and was released home. Several days later, he started having burning pain at the surgical scar radiating to the suprapubic region but otherwise feels well. Examination shows a healed surgical incision centered over McBurney point. There is a loss of sensation over the right suprapubic area. The cremasteric reflex is normal. Which of the following nerves is most likely injured in this patient?

A. Femoral
B. Genitofemoral
C. Iliohypogastric
D. Ilioinguinal
E. Lateral femoral cutaneous
F. Obturator

Submit

A 13-year-old boy comes to the office for a postoperative follow-up visit. He was seen in the emergency department 3 weeks earlier with acute abdominal pain and was found to have acute appendicitis. The patient underwent urgent appendectomy without any apparent immediate complications and was released home. Several days later, he started having burning pain at the surgical scar radiating to the suprapubic region but otherwise feels well. Examination shows a healed surgical incision centered over McBurney point. There is a loss of sensation over the right suprapubic area. The cremasteric reflex is normal. Which of the following nerves is most likely injured in this patient?

- A. Femoral (1%)
- B. Genitofemoral (8%)
- ✓ C. Iliohypogastric (49%)
- D. Ilioinguinal (31%)
- E. Lateral femoral cutaneous (7%)
- F. Obturator (2%)

Omitted
Correct answer
C

49%
Answered correctly

02 secs
Time Spent

05/03/2020
Last Updated

Explanation

Abdominal and pelvic surgery can damage nerves innervating the abdominal wall skin and muscles due to transection from the incision, entrapment from fascia closure, or compression/stretching from tissue retraction or patient positioning. Transection may cause loss of skin sensation or muscle paralysis. Entrapment can cause burning/sharp pain due to continuous stimulation of pain fibers.

The iliohypogastric nerve arises from the L1 nerve root, emerges from the lateral border of the upper psoas major, and passes behind the kidney

6
7
8
9
10
11
12
13
14
15
16
17
18
19
20
21
22
23
24
25
26
27
28
29
30
31
32
33
34
35
36

Abdominal and pelvic surgery can damage nerves innervating the abdominal wall skin and muscles due to transection from the incision, entrapment from fascia closure, or compression/stretching from tissue retraction or patient positioning. Transection may cause loss of skin sensation or muscle paralysis. Entrapment can cause burning/sharp pain due to continuous stimulation of pain fibers.

The iliohypogastric nerve arises from the L1 nerve root, emerges from the lateral border of the upper psoas major, and passes behind the kidney anterior to the quadratus lumborum. The nerve provides motor function to the anterolateral abdominal wall muscles. Its anterior branch emerges above the superficial inguinal ring to innervate the skin above the pubic region; the lateral branch descends over the iliac crest to innervate the gluteal region. Injury to the anterior branch during **appendectomy** causes decreased sensation at the suprapubic region.

(Choice A) The femoral nerve arises from the L2-L4 nerve roots. It provides sensation to the upper thigh and inner leg and innervates muscles that extend the knee.

(Choice B) The genitofemoral nerve arises from the L1-L2 nerve roots and provides sensation to the upper anterior thigh and motor function to parts of the genitalia (eg, cremasteric reflex in men, mons pubis in women).

(Choice D) The ilioinguinal nerve originates from the L1 nerve root and accompanies the spermatic cord through the superficial inguinal ring. It provides sensation to the upper and medial thigh and parts of the external genitalia.

(Choice E) The lateral femoral cutaneous nerve arises from the L2-L3 nerve roots and provides sensation to the skin on the lateral thigh.

(Choice F) The obturator nerve arises from the L2-L4 nerve roots. It innervates the skin of the medial thigh and provides motor function for the adductor muscles of the lower extremity.

Educational objective:
The iliohypogastric nerve provides sensation to the suprapubic and gluteal regions and motor function to the anterolateral abdominal wall muscles. Abdominal surgery (eg, appendectomy) can damage the nerve and cause decreased sensation and/or burning pain at the suprapubic region.

References

- Abdominal wall paresis as a complication of laparoscopic surgery.
- Anatomy of the ilioinguinal and iliohypogastric nerves with observations of their spinal nerve contributions.

6
7
8
9
10
11
12
13
14
15
16
17
18
19
20
21
22
23
24
25
26
27
28
29
30
31
32
33
34
35
36

Exhibit Display

Major nerves of the lumbar plexus

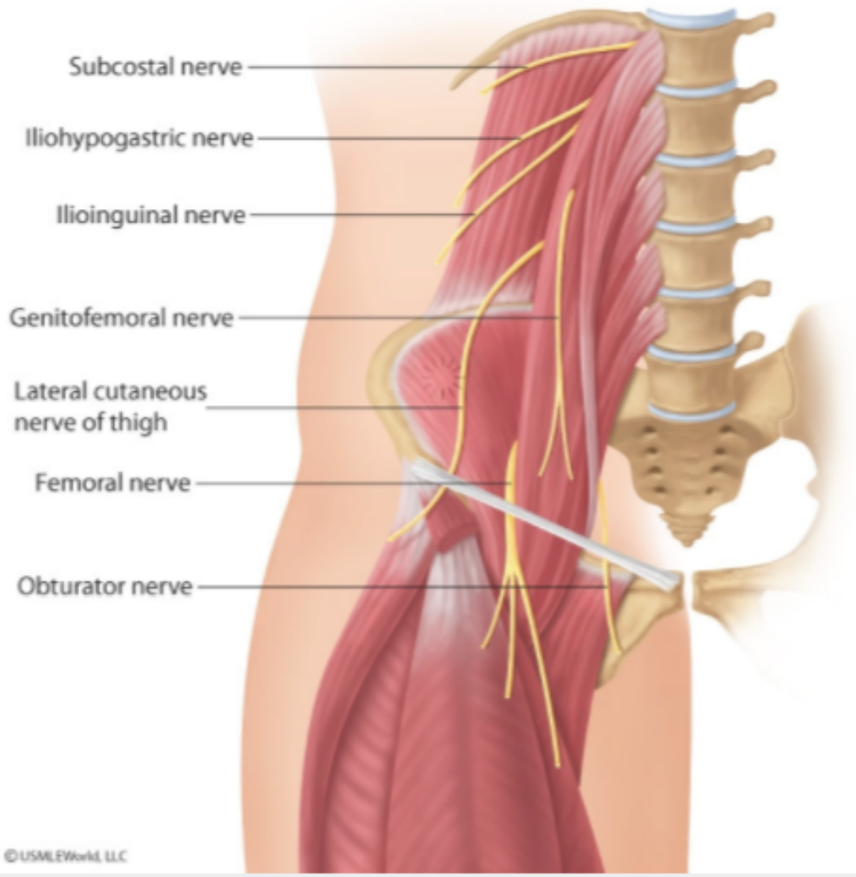

Zoom In | Zoom Out | Reset | Add To New Card | Existing Card

- Anatomy of the ilioinguinal and iliohypogastric nerves with observations of their spinal nerve contributions

6
7
8
9
10
11
12
13
14
15
16
17
18
19
20
21
22
23
24
25
26
27
28
29
30
31
32
33
34
35
36

Exhibit Display

Femoral nerve

Motor function	Cutaneous innervation
Leg flexion at the hip, leg extension at the knee	

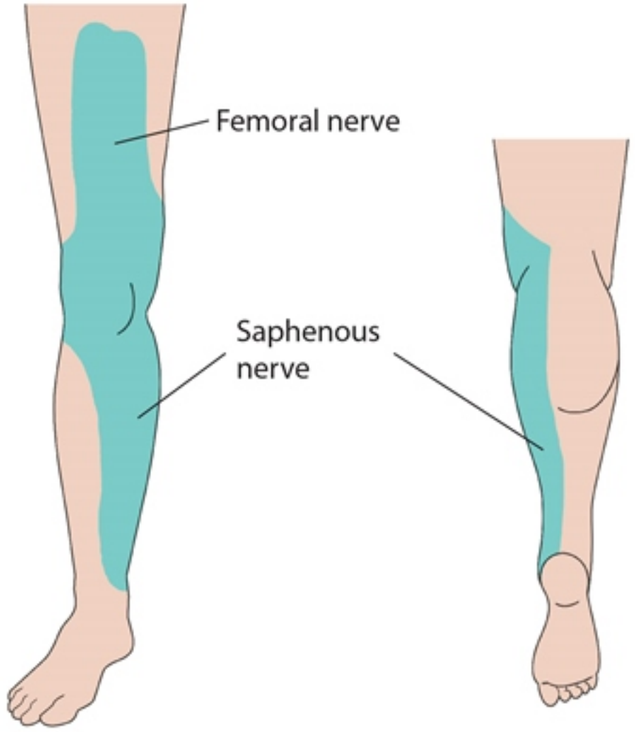

©UWorld

Zoom In | Zoom Out | Reset | Add To New Card | Existing Card

Anatomy of the ilioinguinal and iliohypogastric nerves with observations of their spinal nerve contributions

6
7
8
9
10
11
12
13
14
15
16
17
18
19
20
21
22
23
24
25
26
27
28
29
30
31
32
33
34
35
36

Exhibit Display

Obturator nerve

Motor function	Cutaneous innervation
Adduction of the thigh	

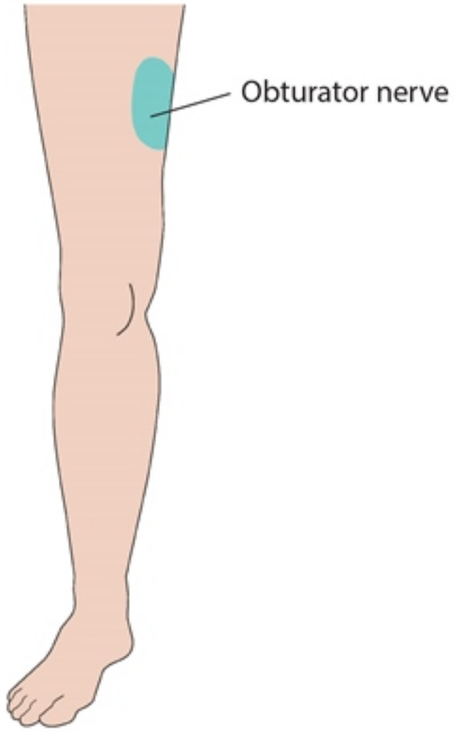

©UWorld

Zoom In | Zoom Out | Reset | Add To New Card | Existing Card

- Anatomy of the ilioinguinal and iliohypogastric nerves with observations of their spinal nerve contributions

6
7
8
9
10
11
12
13
14
15
16
17
18
19
20
21
22
23
24
25
26
27
28
29
30
31
32
33
34
35
36

anterior to the quadratus lumborum. The nerve provides motor function to the anterolateral abdominal wall muscles. Its anterior branch emerges above the superficial inguinal ring to innervate the skin above the pubic region; the lateral branch descends over the iliac crest to innervate the gluteal region. Injury to the anterior branch during **appendectomy** causes decreased sensation at the suprapubic region.

(Choice A) The femoral nerve arises from the L2-L4 nerve roots. It provides sensation to the upper thigh and inner leg and innervates muscles that extend the knee.

(Choice B) The genitofemoral nerve arises from the L1-L2 nerve roots and provides sensation to the upper anterior thigh and motor function to parts of the genitalia (eg, cremasteric reflex in men, mons pubis in women).

(Choice D) The ilioinguinal nerve originates from the L1 nerve root and accompanies the spermatic cord through the superficial inguinal ring. It provides sensation to the upper and medial thigh and parts of the external genitalia.

(Choice E) The lateral femoral cutaneous nerve arises from the L2-L3 nerve roots and provides sensation to the skin on the lateral thigh.

(Choice F) The obturator nerve arises from the L2-L4 nerve roots. It innervates the skin of the medial thigh and provides motor function for the adductor muscles of the lower extremity.

Educational objective:
The iliohypogastric nerve provides sensation to the suprapubic and gluteal regions and motor function to the anterolateral abdominal wall muscles. Abdominal surgery (eg, appendectomy) can damage the nerve and cause decreased sensation and/or burning pain at the suprapubic region.

References

- Abdominal wall paresis as a complication of laparoscopic surgery.
- Anatomy of the ilioinguinal and iliohypogastric nerves with observations of their spinal nerve contributions.

Anatomy	Nervous System	Appendicitis
Subject	System	Topic

Copyright © UWorld. All rights reserved.

6
7
8
9
10
11
12
13
14
15
16
17
18
19
20
21
22
23
24
25
26
27
28
29
30
31
32
33
34
35
36

A 22-year-old man is brought to the emergency department after a bar fight during which he received a knife wound to his neck. The patient is in moderate distress but is alert and can follow commands. Vital signs are stable. Neurologic examination shows right-sided hemiplegia. Loss of proprioception and vibratory sensation is present below the C8 dermatome on the right side. On the left side, there is loss of pain and temperature sensation below the T2 dermatome. MRI of this patient's spine will most likely reveal which of the following?

A. Complete transection of the spinal cord

B. Damage to the cervical dorsal roots on the right side

C. Lesion of the dorsal columns on the right side

D. Lesion of the medial longitudinal fasciculus on the right side

E. Right-sided hemisection of the spinal cord

Submit

6
7
8
9
10
11
12
13
14
15
16
17
18
19
20
21
22
23
24
25
26
27
28
29
30
31
32
33
34
35
36

A 22-year-old man is brought to the emergency department after a bar fight during which he received a knife wound to his neck. The patient is in moderate distress but is alert and can follow commands. Vital signs are stable. Neurologic examination shows right-sided hemiplegia. Loss of proprioception and vibratory sensation is present below the C8 dermatome on the right side. On the left side, there is loss of pain and temperature sensation below the T2 dermatome. MRI of this patient's spine will most likely reveal which of the following?

A. Complete transection of the spinal cord (1%)

B. Damage to the cervical dorsal roots on the right side (2%)

C. Lesion of the dorsal columns on the right side (5%)

D. Lesion of the medial longitudinal fasciculus on the right side (2%)

✓ E. Right-sided hemisection of the spinal cord (88%)

Omitted
Correct answer
E

88%
Answered correctly

02 secs
Time Spent

03/11/2020
Last Updated

Explanation

Brown-Séquard syndrome

6
7
8
9
10
11
12
13
14
15
16
17
18
19
20
21
22
23
24
25
26
27
28
29
30
31
32
33
34
35
36

Brown-Séquard syndrome

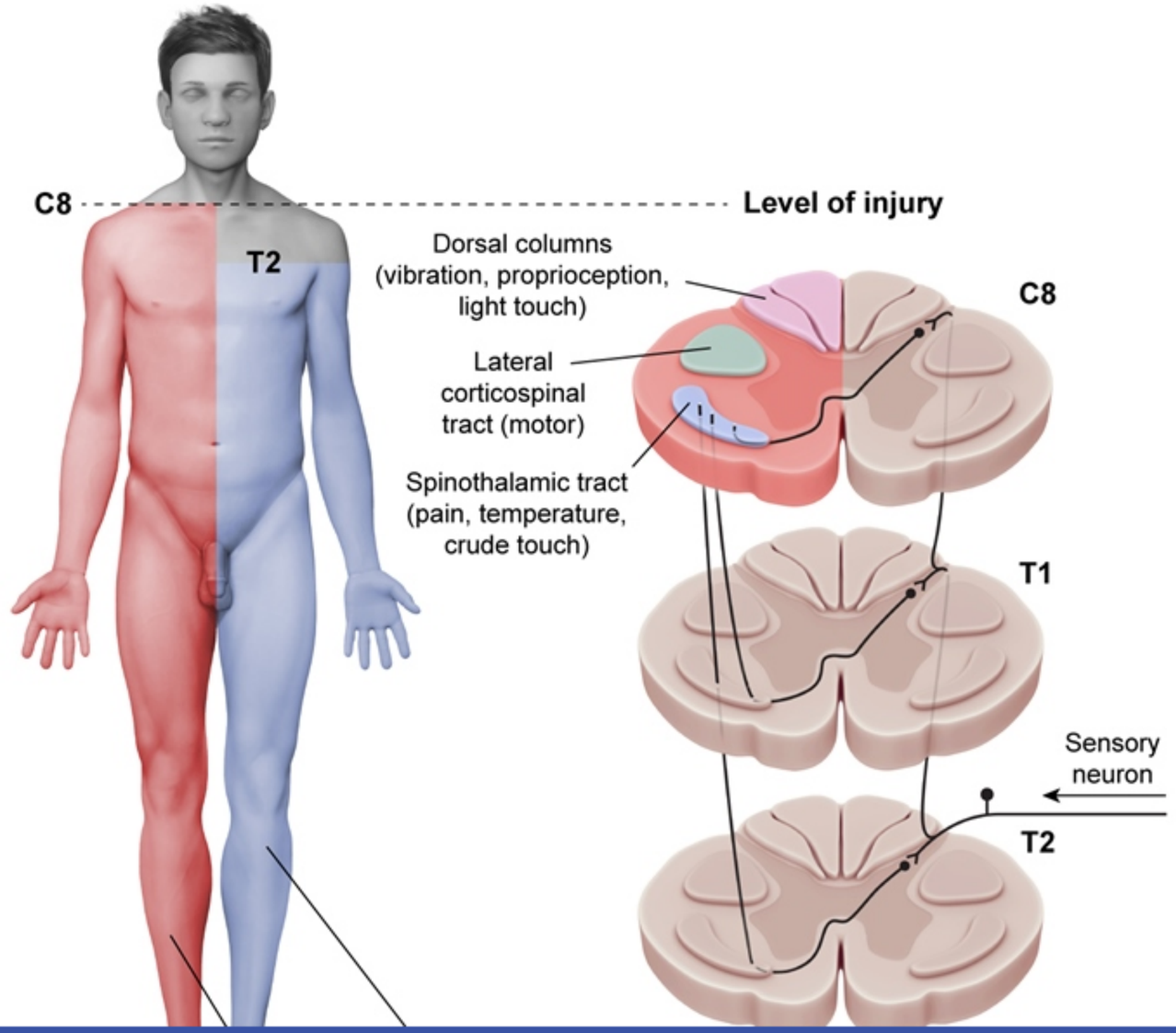

6
7
8
9
10
11
12
13
14
15
16
17
18
19
20
21
22
23
24
25
26
27
28
29
30
31
32
33
34
35
36

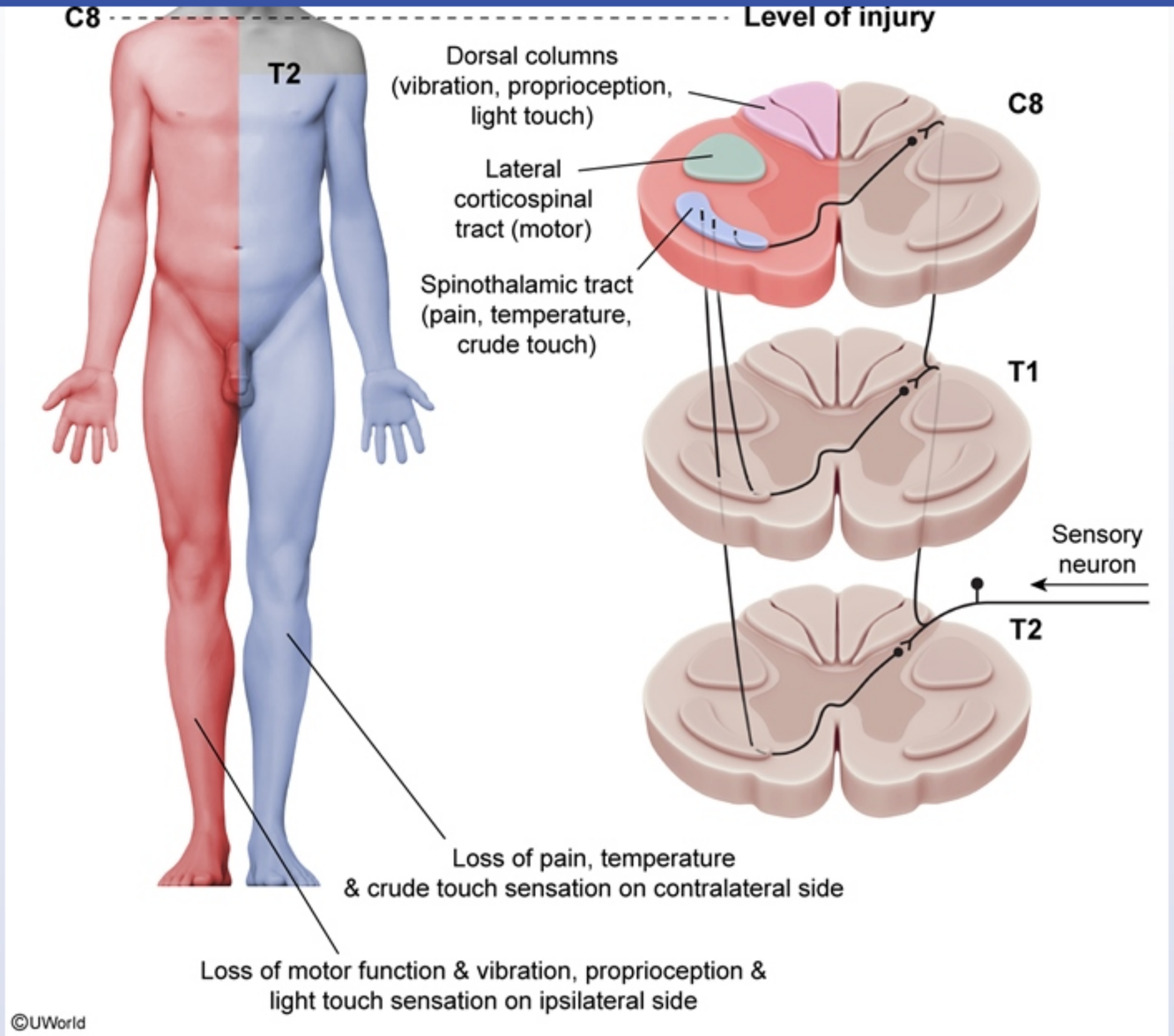

This patient has a penetrating injury resulting in right-sided **hemisection** of the **spinal cord** at the C8 level. Spinal cord hemisection classically

©UWorld

This patient has a penetrating injury resulting in right-sided **hemisection** of the **spinal cord** at the C8 level. Spinal cord hemisection classically causes Brown-Séquard syndrome, which is characterized by the following tract lesions and clinical signs:

- **Anterior horn** (lower motor neuron) injury produces ipsilateral paralysis at the level of the lesion.
- Lateral **corticospinal tract** (upper motor neuron) injury results in ipsilateral paralysis below the level of the lesion.
- **Dorsal column** (gracile and cuneate fasciculi) involvement causes ipsilateral loss of vibration, proprioception, and light touch (ie, 2-point discrimination) sensation below the level of the lesion.
- **Spinothalamic tract** injury causes contralateral loss of pain and temperature (lateral spinothalamic) and crude touch (anterior spinothalamic) sensation 1-2 levels below the lesion.

Spinal cord injury above T1 can also cause ipsilateral Horner syndrome (ie, ptosis, miosis, anhidrosis) if there is concurrent damage to the oculosympathetic pathway.

(Choice A) Complete transection of the spinal cord would result in bilateral loss of all sensation and voluntary movement below the level of the lesion.

(Choice B) A lesion of the dorsal sensory roots would lead to ipsilateral loss of sensation and areflexia from the specific dermatome(s) affected.

(Choice C) A lesion of the dorsal columns on the right side would result only in ipsilateral loss of vibratory, proprioceptive, and light touch (ie, 2-point discrimination) sensation below the level of the lesion.

(Choice D) A lesion of the medial longitudinal fasciculus is associated with internuclear ophthalmoplegia, which is commonly seen in multiple sclerosis; it presents with impaired horizontal eye movement and weak adduction of the ipsilateral eye with simultaneous abduction nystagmus of the contralateral eye.

Educational objective:
Brown-Séquard syndrome results from hemisection of the spinal cord. It is characterized by ipsilateral paralysis due to corticospinal tract injury; ipsilateral loss of vibratory, proprioceptive, and light touch sensation (dorsal columns); and contralateral loss of pain, temperature, and crude touch sensation (spinothalamic tract) below the level of the injury.

References

6 7 8 9 10 11 12 13 14 15 16 17 18 19 20 21 22 23 24 25 26 27 28 29 30 31 32 33 34 35 36

- **Spinothalamic tract** injury causes contralateral loss of pain and temperature (lateral spinothalamic) and crude touch (anterior spinothalamic) sensation 1-2 levels below the lesion.

Spinal cord injury above T1 can also cause ipsilateral Horner syndrome (ie, ptosis, miosis, anhidrosis) if there is concurrent damage to the oculosympathetic pathway.

(Choice A) Complete transection of the spinal cord would result in bilateral loss of all sensation and voluntary movement below the level of the lesion.

(Choice B) A lesion of the dorsal sensory roots would lead to ipsilateral loss of sensation and areflexia from the specific dermatome(s) affected.

(Choice C) A lesion of the dorsal columns on the right side would result only in ipsilateral loss of vibratory, proprioceptive, and light touch (ie, 2-point discrimination) sensation below the level of the lesion.

(Choice D) A lesion of the medial longitudinal fasciculus is associated with internuclear ophthalmoplegia, which is commonly seen in multiple sclerosis; it presents with impaired horizontal eye movement and weak adduction of the ipsilateral eye with simultaneous abduction nystagmus of the contralateral eye.

Educational objective:
Brown-Séquard syndrome results from hemisection of the spinal cord. It is characterized by ipsilateral paralysis due to corticospinal tract injury; ipsilateral loss of vibratory, proprioceptive, and light touch sensation (dorsal columns); and contralateral loss of pain, temperature, and crude touch sensation (spinothalamic tract) below the level of the injury.

References

- Brown-Sequard syndrome.
- Incomplete cord syndromes: clinical and imaging review.

Anatomy	Nervous System	Spinal cord injury
Subject	System	Topic

Copyright © UWorld. All rights reserved.

- **Spinothalamic tract** injury causes contralateral loss of pain and temperature (lateral spinothalamic) and crude touch (anterior spinothalamic) sensation 1-2 levels below the lesion.

Spinal cord injury above T
oculosympathetic pathway

(Choice A) Complete tra
lesion.

(Choice B) A lesion of th

(Choice C) A lesion of th
point discrimination) sens

(Choice D) A lesion of th
sclerosis; it presents with
the contralateral eye.

Educational objective:
Brown-Séquard syndrome
ipsilateral loss of vibratory
sensation (spinothalamic

References

- Brown-Sequard syndr
- Incomplete cord syndr

Anatomy
Subject

Nervous
System

Exhibit Display



Copyright © UWorld. All rights reserved.

6
7
8
9
10
11
12
13
14
15
16
17
18
19
20
21
22
23
24
25
26
27
28
29
30
31
32
33
34
35
36

A 60-year-old man comes to the office due to difficulties in tasting food. He says, "All food now tastes bland," and he is unable to enjoy different flavors during meals. Two months ago, the patient had a traumatic brain injury after a head-on motor vehicle collision. He was in a coma for several days and, after regaining consciousness, began having severe headaches and impaired taste. The headaches have improved, but he continues to have difficulty tasting food. The patient has no visual concerns, slurred speech, trouble swallowing, vertigo, or extremity weakness or numbness. He is a truck driver and has a history of heavy tobacco use for many years. Vital signs are within normal limits. Physical examination shows no focal motor deficits. Which of the following is the most likely cause of this patient's current symptoms?

A. Anterior temporal lobe contusion

B. Avulsion of olfactory nerve rootlets

C. Ischemic stroke of the dorsolateral medulla

D. Lingual nerve injury

E. Sphenoid bone fracture

Submit

6
7
8
9
10
11
12
13
14
15
16
17
18
19
20
21
22
23
24
25
26
27
28
29
30
31
32
33
34
35
36

A 60-year-old man comes to the office due to difficulties in tasting food. He says, "All food now tastes bland," and he is unable to enjoy different flavors during meals. Two months ago, the patient had a traumatic brain injury after a head-on motor vehicle collision. He was in a coma for several days and, after regaining consciousness, began having severe headaches and impaired taste. The headaches have improved, but he continues to have difficulty tasting food. The patient has no visual concerns, slurred speech, trouble swallowing, vertigo, or extremity weakness or numbness. He is a truck driver and has a history of heavy tobacco use for many years. Vital signs are within normal limits. Physical examination shows no focal motor deficits. Which of the following is the most likely cause of this patient's current symptoms?

A. Anterior temporal lobe contusion (6%)
✓ B. Avulsion of olfactory nerve rootlets (69%)
C. Ischemic stroke of the dorsolateral medulla (4%)
D. Lingual nerve injury (9%)
E. Sphenoid bone fracture (8%)

Omitted
Correct answer
B

69%
Answered correctly

02 secs
Time Spent

04/17/2020
Last Updated

Explanation

Olfactory nerve rootlet avulsion with TBI

6
7
8
9
10
11
12
13
14
15
16
17
18
19
20
21
22
23
24
25
26
27
28
29
30
31
32
33
34
35
36

Explanation

Olfactory nerve rootlet avulsion with TBI

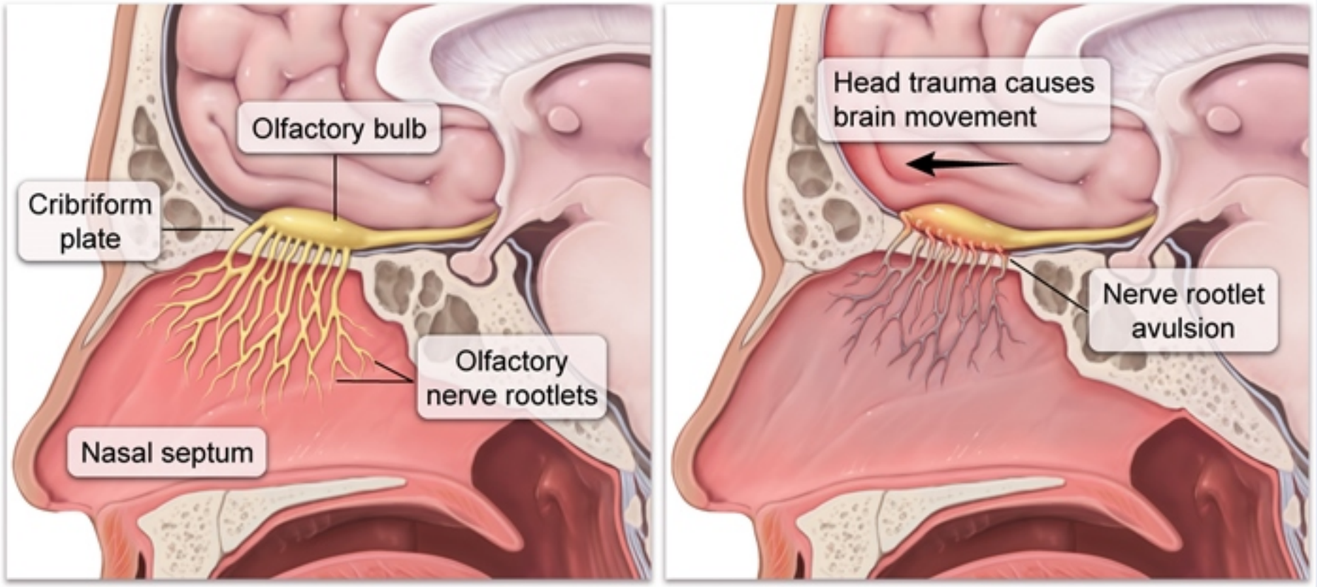

TBI = traumatic brain injury.
©UWorld

This patient has a decreased perception of flavors after **traumatic brain injury**. The perception of flavor is dependent on both smell and taste, with smell being more important. Patients with **anosmia (loss of smell)** often describe difficulties with taste, even if taste sensation is intact.

The perception of smell is mediated by odorant molecules that bind to olfactory chemoreceptor cells in the nasal mucosa. Axons of the chemoreceptor cells make up the olfactory nerve (CN I) rootlets, which project through the **cribriform plate** of the ethmoid bone to synapse on the glomeruli of the olfactory bulb. The olfactory bulb then projects second-order axons to the primary olfactory cortex in the medial temporal lobe via the olfactory tract.

6
7
8
9
10
11
12
13
14
15
16
17
18
19
20
21
22
23
24
25
26
27
28
29
30
31
32
33
34
35
36

TBI = traumatic brain injury.
©UWorld

This patient has a decreased perception of flavors after **traumatic brain injury**. The perception of flavor is dependent on both smell and taste, with smell being more important. Patients with **anosmia (loss of smell)** often describe difficulties with taste, even if taste sensation is intact.

The perception of smell is mediated by odorant molecules that bind to olfactory chemoreceptor cells in the nasal mucosa. Axons of the chemoreceptor cells make up the olfactory nerve (CN I) rootlets, which project through the **cribriform plate** of the ethmoid bone to synapse on the glomeruli of the olfactory bulb. The olfactory bulb then projects second-order axons to the primary olfactory cortex in the medial temporal lobe via the olfactory tract.

Head trauma can cause anosmia when acceleration-deceleration forces lead to **avulsion** of the **olfactory nerve rootlets** as they transverse the cribriform plate.

(Choice A) The anterior temporal lobe is important for semantic memory; as a result, injury to this brain region typically results in impaired comprehension about the meaning of words, pictures, and objects.

(Choice C) Dorsolateral medulla infarction causes Wallenberg syndrome. This condition is characterized by vertigo/nystagmus, ipsilateral cerebellar signs (eg, ataxia, dysmetria), loss of pain/temperature sensation in the ipsilateral face and contralateral body, bulbar weakness (eg, dysphagia), and ipsilateral Horner syndrome (miosis, ptosis, anhidrosis).

(Choice D) The lingual nerve is a branch of the mandibular division of the trigeminal nerve (CN V3) that provides somatic sensation to the anterior two-thirds of the tongue. Fibers of the chorda tympani nerve, a branch of the facial nerve (CN VII), also travel with the lingual nerve to relay taste from the anterior two-thirds of the tongue. If taste disturbances were due to injury of the lingual nerve, tongue numbness would also be present.

(Choice E) Sphenoid bone fractures are associated with damage to the optic nerve (CN II), pituitary gland injury, and leakage of cerebrospinal fluid into the sphenoid sinus.

Educational objective:
Olfactory signals are relayed via the olfactory nerve (CN I) through the cribriform plate to the olfactory bulb, which then projects to the primary olfactory cortex in the medial temporal lobe. Head trauma can tear olfactory nerve (CNI) rootlets as they cross the cribriform plate, causing anosmia. Anosmia is often interpreted by patients as loss of taste.

6
7
8
9
10
11
12
13
14
15
16
17
18
19
20
21
22
23
24
25
26
27
28
29
30
31
32
33
34
35
36

The perception of smell is mediated by odorant molecules that bind to olfactory chemoreceptor cells in the nasal mucosa. Axons of the chemoreceptor cells make up the olfactory nerve (CN I) rootlets, which project through the **cribriform plate** of the ethmoid bone to synapse on the glomeruli of the olfactory bulb. The olfactory bulb then projects second-order axons to the primary olfactory cortex in the medial temporal lobe via the olfactory tract.

Head trauma can cause anosmia when acceleration-deceleration forces lead to **avulsion** of the **olfactory nerve rootlets** as they transverse the cribriform plate.

(Choice A) The anterior temporal lobe is important for semantic memory; as a result, injury to this brain region typically results in impaired comprehension about the meaning of words, pictures, and objects.

(Choice C) Dorsolateral medulla infarction causes Wallenberg syndrome. This condition is characterized by vertigo/nystagmus, ipsilateral cerebellar signs (eg, ataxia, dysmetria), loss of pain/temperature sensation in the ipsilateral face and contralateral body, bulbar weakness (eg, dysphagia), and ipsilateral Horner syndrome (miosis, ptosis, anhidrosis).

(Choice D) The lingual nerve is a branch of the mandibular division of the trigeminal nerve (CN V3) that provides somatic sensation to the anterior two-thirds of the tongue. Fibers of the chorda tympani nerve, a branch of the facial nerve (CN VII), also travel with the lingual nerve to relay taste from the anterior two-thirds of the tongue. If taste disturbances were due to injury of the lingual nerve, tongue numbness would also be present.

(Choice E) Sphenoid bone fractures are associated with damage to the optic nerve (CN II), pituitary gland injury, and leakage of cerebrospinal fluid into the sphenoid sinus.

Educational objective:
Olfactory signals are relayed via the olfactory nerve (CN I) through the cribriform plate to the olfactory bulb, which then projects to the primary olfactory cortex in the medial temporal lobe. Head trauma can tear olfactory nerve (CNI) rootlets as they cross the cribriform plate, causing anosmia. Anosmia is often interpreted by patients as loss of taste.

Anatomy	Nervous System	Traumatic brain injury
Subject	System	Topic

6
7
8
9
10
11
12
13
14
15
16
17
18
19
20
21
22
23
24
25
26
27
28
29
30
31
32
33
34
35
36

Exhibit Display

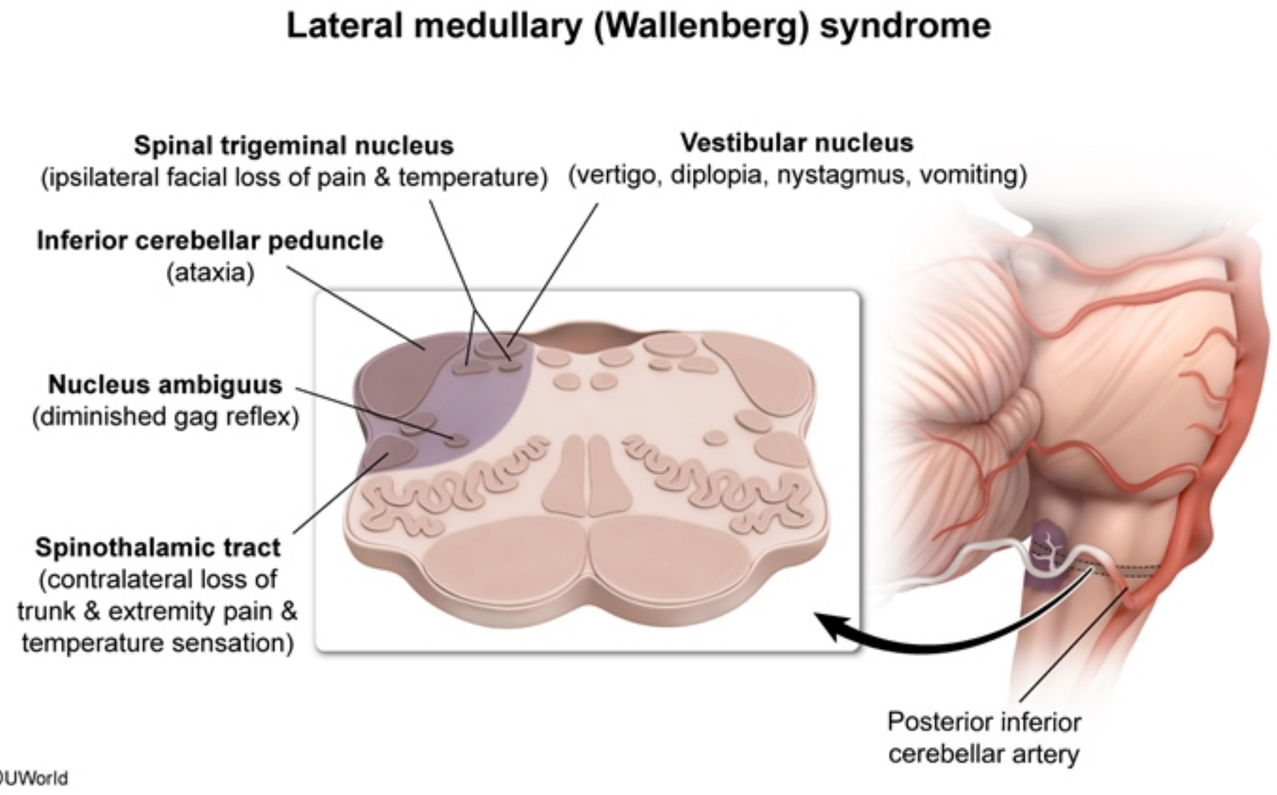

Zoom In | Zoom Out | Reset | Add To New Card | Existing Card

6
7
8
9
10
11
12
13
14
15
16
17
18
19
20
21
22
23
24
25
26
27
28
29
30
31
32
33
34
35
36

Exhibit Display

Mandibular division of trigeminal nerve

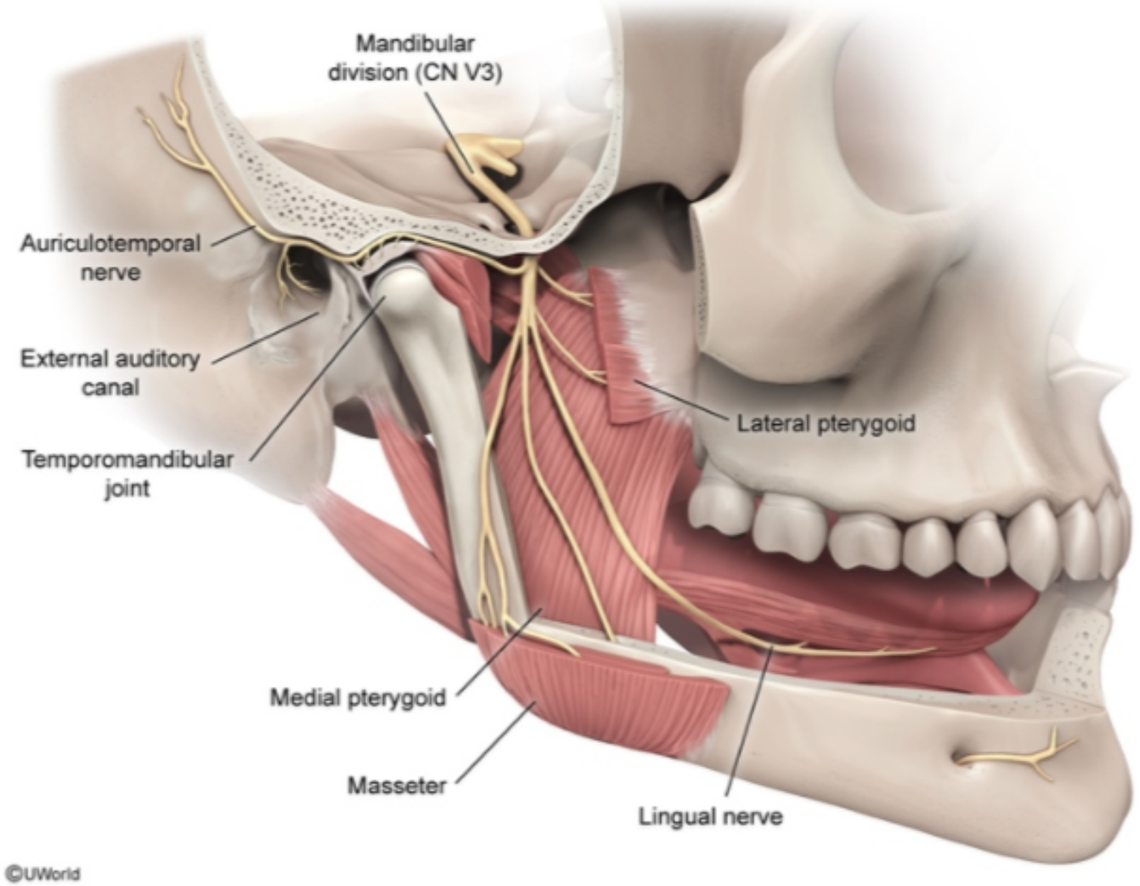

Zoom In | Zoom Out | Reset | Add To New Card | Existing Card

6
7
8
9
10
11
12
13
14
15
16
17
18
19
20
21
22
23
24
25
26
27
28
29
30
31
32
33
34
35
36

A 9-year old girl is brought to the emergency department by her parents due to severe headache, lethargy, and vomiting. Her symptoms began a few weeks ago with mild intermittent headaches and fatigue and have progressively worsened. A CT scan of the brain reveals a mass lesion, enlarged lateral and third ventricles, and a normal-sized fourth ventricle. Which of the following is the most likely site of obstruction in this patient?

A. Arachnoid Villi

B. Cerebral aqueduct

C. Interventricular foramina of Monro

D. Lateral foramina of Luschka

E. Medial foramen of Magendie

Submit

6
7
8
9
10
11
12
13
14
15
16
17
18
19
20
21
22
23
24
25
26
27
28
29
30
31
32
33
34
35
36

A 9-year old girl is brought to the emergency department by her parents due to severe headache, lethargy, and vomiting. Her symptoms began a few weeks ago with mild intermittent headaches and fatigue and have progressively worsened. A CT scan of the brain reveals a mass lesion, enlarged lateral and third ventricles, and a normal-sized fourth ventricle. Which of the following is the most likely site of obstruction in this patient?

A. Arachnoid Villi (0%)
✓ B. Cerebral aqueduct (81%)
C. Interventricular foramina of Monro (13%)
D. Lateral foramina of Luschka (2%)
E. Medial foramen of Magendie (2%)

Omitted
Correct answer
B

81%
Answered correctly

02 secs
Time Spent

07/04/2020
Last Updated

Explanation

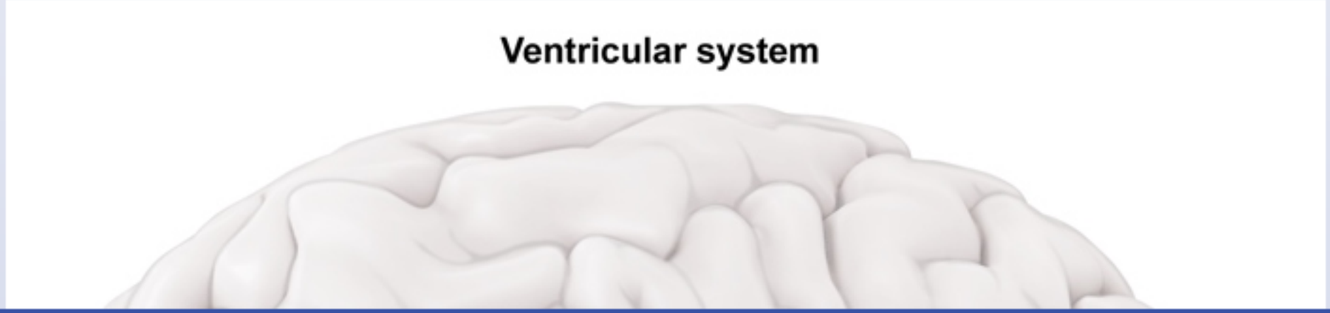

6
7
8
9
10
11
12
13
14
15
16
17
18
19
20
21
22
23
24
25
26
27
28
29
30
31
32
33
34
35
36

Ventricular system

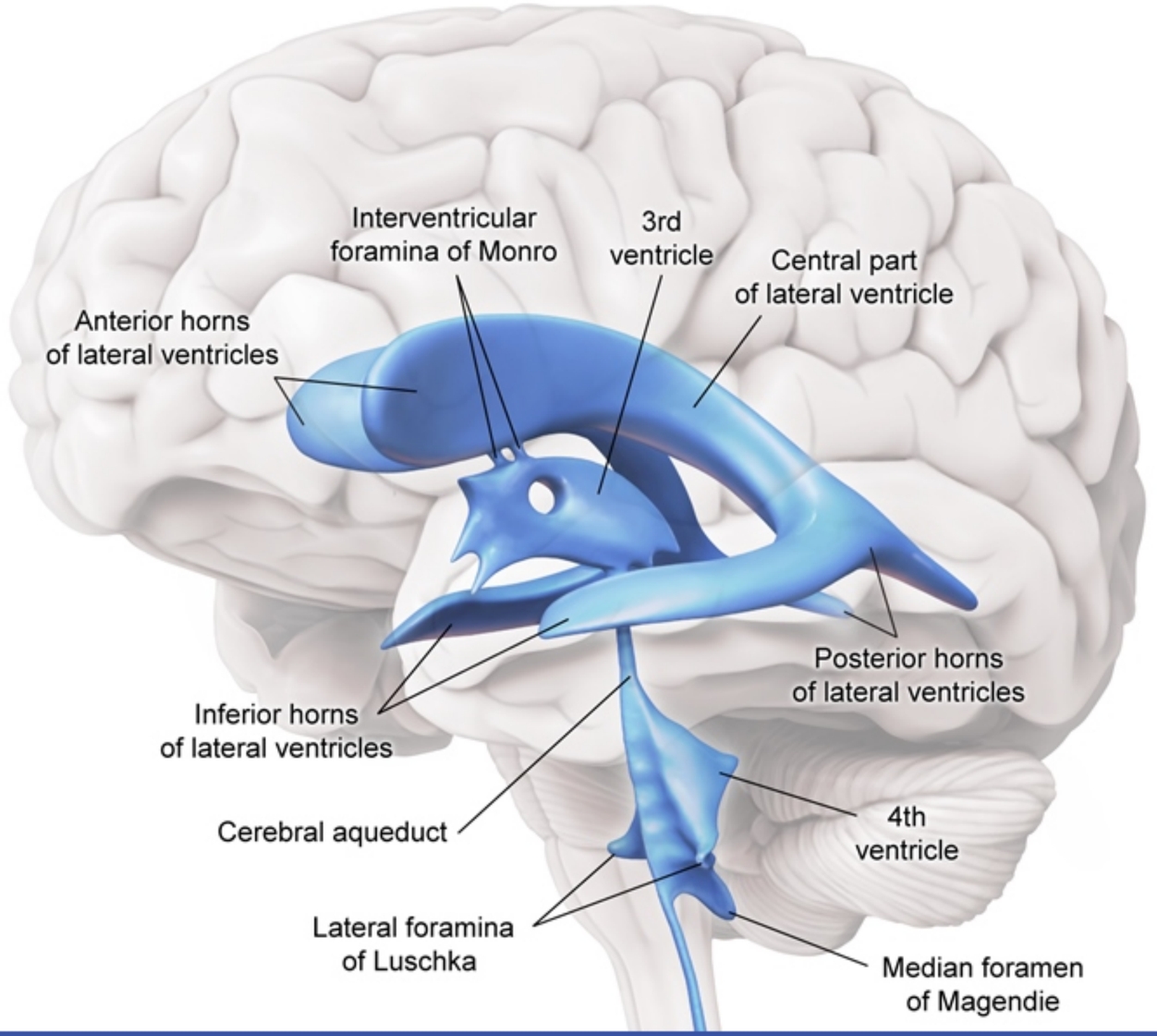

©UWorld

Cerebrospinal fluid (CSF) is formed by 4 choroid plexuses found in each of the ventricles. The choroid plexus is composed of ependymal cell-covered outgrowths of pia mater capillaries that are fenestrated unlike other central nervous system (CNS) capillaries. The ependymal layer is a simple ciliated columnar epithelium with tight junctions between the cells. This selectively allows only certain materials from the blood to enter the CSF. Once formed, CSF flows from the lateral ventricles to the third ventricle via the interventricular foramina of Monro. It then circulates to the fourth ventricle through the cerebral aqueduct (of Sylvius). CSF then exits the fourth ventricle and enters the subarachnoid space via one of 3 foramina: the 2 lateral foramina of Luschka and the single midline foramen of Magendie. CSF is returned to the venous circulation via the arachnoid villi (granulations).

This patient has findings consistent with noncommunicating (obstructive) hydrocephalus. Obstruction of CSF flow is most commonly caused by tumors, scarring (post-hemorrhage, infection), and CNS malformations. In this patient, obstruction at the level of the cerebral aqueduct causes increased pressures and ventricular dilation proximal to the site of blockage, which includes the lateral and third ventricles. The fourth ventricle is normal-sized as it is distal to the obstruction. In contrast, obstruction at the foramen of Magendie and Luschka would cause enlargement of all 4 ventricles **(Choices D and E)**, while obstruction at the foramen of Monro would cause enlargement of only the affected lateral ventricle **(Choice C)**.

Other forms of hydrocephalus are described below:

1. **Communicating hydrocephalus** presents with global ventricular dilation and increased intracranial pressure (ICP) without significant blockage to CSF flow within the brain or brainstem. It usually results from impaired CSF absorption by the arachnoid villi due to inflammation and fibrosis caused by hemorrhage or infection **(Choice A)**. It rarely occurs due to increased production of CSF caused by papillomas of the choroid plexus.
2. **Normal pressure hydrocephalus** presents with enlarged ventricles in the setting of normal ICP. It is considered to be a form of communicating hydrocephalus where impaired absorption of CSF is compensated for by decreased CSF formation. Although ICP is normal, there is still a pressure gradient between the ventricles and subarachnoid space which is responsible for the ventricular enlargement. Communicating hydrocephalus is more often found in infants and children, while normal pressure hydrocephalus is most commonly found in adults.
3. **Hydrocephalus ex vacuo** presents with normal ICP and increased dilatation of ventricles secondary to cortical atrophy. It occurs most often in elderly patients with dementia.

ventricles **(Choices D and E)**, while obstruction at the foramen of Monro would cause enlargement of only the affected lateral ventricle **(Choice C)**.

Other forms of hydrocephalus are described below:

1. **Communicating hydrocephalus** presents with global ventricular dilation and increased intracranial pressure (ICP) without significant blockage to CSF flow within the brain or brainstem. It usually results from impaired CSF absorption by the arachnoid villi due to inflammation and fibrosis caused by hemorrhage or infection **(Choice A)**. It rarely occurs due to increased production of CSF caused by papillomas of the choroid plexus.
2. **Normal pressure hydrocephalus** presents with enlarged ventricles in the setting of normal ICP. It is considered to be a form of communicating hydrocephalus where impaired absorption of CSF is compensated for by decreased CSF formation. Although ICP is normal, there is still a pressure gradient between the ventricles and subarachnoid space which is responsible for the ventricular enlargement. Communicating hydrocephalus is more often found in infants and children, while normal pressure hydrocephalus is most commonly found in adults.
3. **Hydrocephalus ex vacuo** presents with normal ICP and increased dilatation of ventricles secondary to cortical atrophy. It occurs most often in elderly patients with dementia.
4. **Pseudotumor cerebri** presents with elevated ICP and classically occurs in young women who are overweight. The etiology of the condition is not well known, but it is thought to be related to cerebral venous outflow abnormalities due to elevated intracranial pressures.

Educational objective:
CSF flows from the third ventricle to the fourth ventricle via the cerebral aqueduct of Sylvius. Obstruction at this level can cause dilated lateral and third ventricles with a normal-sized fourth ventricle. Obstruction at the foramen of Monro would cause enlargement of only the affected lateral ventricle, while obstruction at the foramen of Magendie and Luschka causes enlargement of all 4 ventricles.

Anatomy	Nervous System	Hydrocephalus
Subject	System	Topic

Copyright © UWorld. All rights reserved.

6
7
8
9
10
11
12
13
14
15
16
17
18
19
20
21
22
23
24
25
26
27
28
29
30
31
32
33
34
35
36

Central canal

Exhibit Display

Flow of cerebrospinal fluid

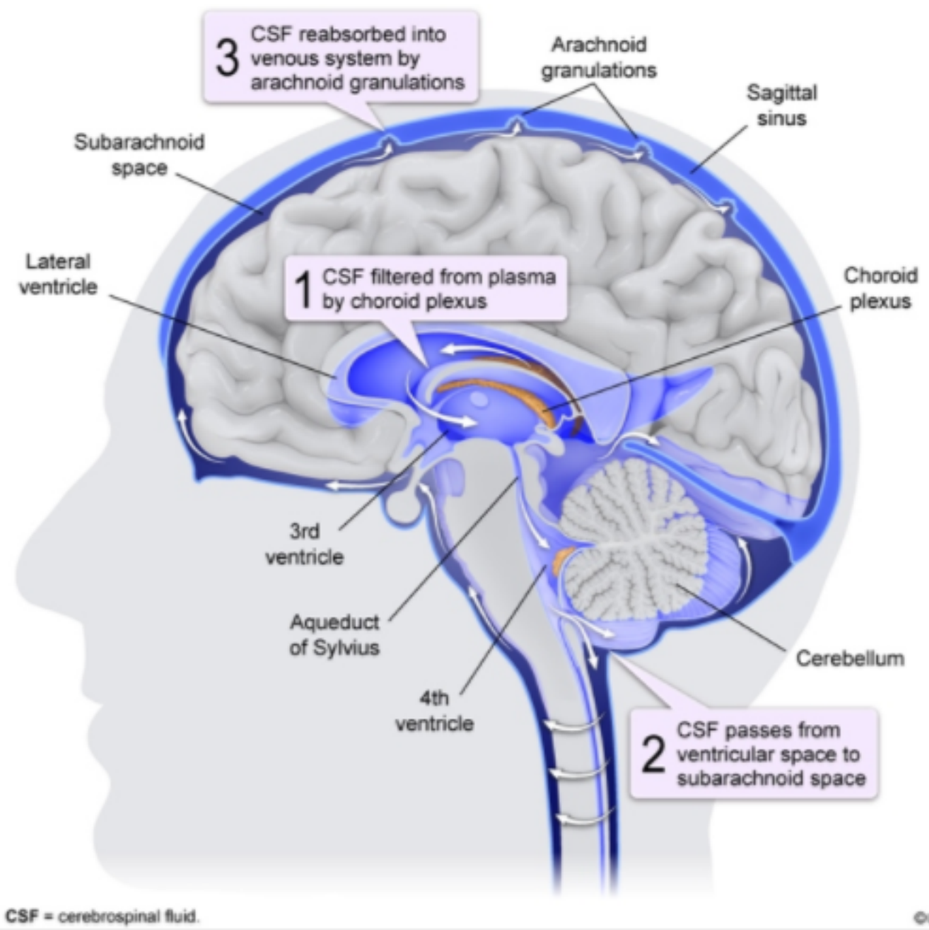

CSF = cerebrospinal fluid.

©UWorld

Zoom In | Zoom Out | Reset | Add To New Card | Existing Card

Central canal

Exhibit Display

Zoom In
Zoom Out
Reset
Add To New Card | Existing Card

6
7
8
9
10
11
12
13
14
15
16
17
18
19
20
21
22
23
24
25
26
27
28
29
30
31
32
33
34
35
36

Central canal

Exhibit Display

Zoom In | Zoom Out | Reset | Add To New Card | Existing Card

6
7
8
9
10
11
12
13
14
15
16
17
18
19
20
21
22
23
24
25
26
27
28
29
30
31
32
33
34
35
36

6
7
8
9
10
11
12
13
14
15
16
17
18
19
20
21
22
23
24
25
26
27
28
29
30
31
32
33
34
35
36

A 55-year-old man with poorly controlled hypertension and type 2 diabetes mellitus comes to the emergency department due to difficulty seeing. He has had blurry vision for the last 2 weeks, and 1 day ago he suddenly noticed a shadow develop across the visual field of his left eye. The patient has no recent headache, double vision, vertigo, light sensitivity, or nausea. On examination, pupils are equal and reactive to light. There is an area of reduced vision in the left eye. Funduscopic examination reveals a flame-shaped hemorrhage in the left temporal hemiretina. The transmission of visual information through which of the following neural structures will be disrupted?

A. Left inferior colliculus
B. Left lateral geniculate body
C. Left medial geniculate body
D. Medial optic chiasm
E. Right inferior colliculus
F. Right lateral geniculate body
G. Right medial geniculate body

Submit

6
7
8
9
10
11
12
13
14
15
16
17
18
19
20
21
22
23
24
25
26
27
28
29
30
31
32
33
34
35
36

A 55-year-old man with poorly controlled hypertension and type 2 diabetes mellitus comes to the emergency department due to difficulty seeing. He has had blurry vision for the last 2 weeks, and 1 day ago he suddenly noticed a shadow develop across the visual field of his left eye. The patient has no recent headache, double vision, vertigo, light sensitivity, or nausea. On examination, pupils are equal and reactive to light. There is an area of reduced vision in the left eye. Funduscopic examination reveals a flame-shaped hemorrhage in the left temporal hemiretina. The transmission of visual information through which of the following neural structures will be disrupted?

- A. Left inferior colliculus (4%)
- ✓ B. Left lateral geniculate body (53%)
- C. Left medial geniculate body (7%)
- D. Medial optic chiasm (8%)
- E. Right inferior colliculus (3%)
- F. Right lateral geniculate body (18%)
- G. Right medial geniculate body (5%)

Omitted
Correct answer
B

53%
Answered correctly

02 secs
Time Spent

04/01/2020
Last Updated

Explanation

Visual pathways from above

6
7
8
9
10
11
12
13
14
15
16
17
18
19
20
21
22
23
24
25
26
27
28
29
30
31
32
33
34
35
36

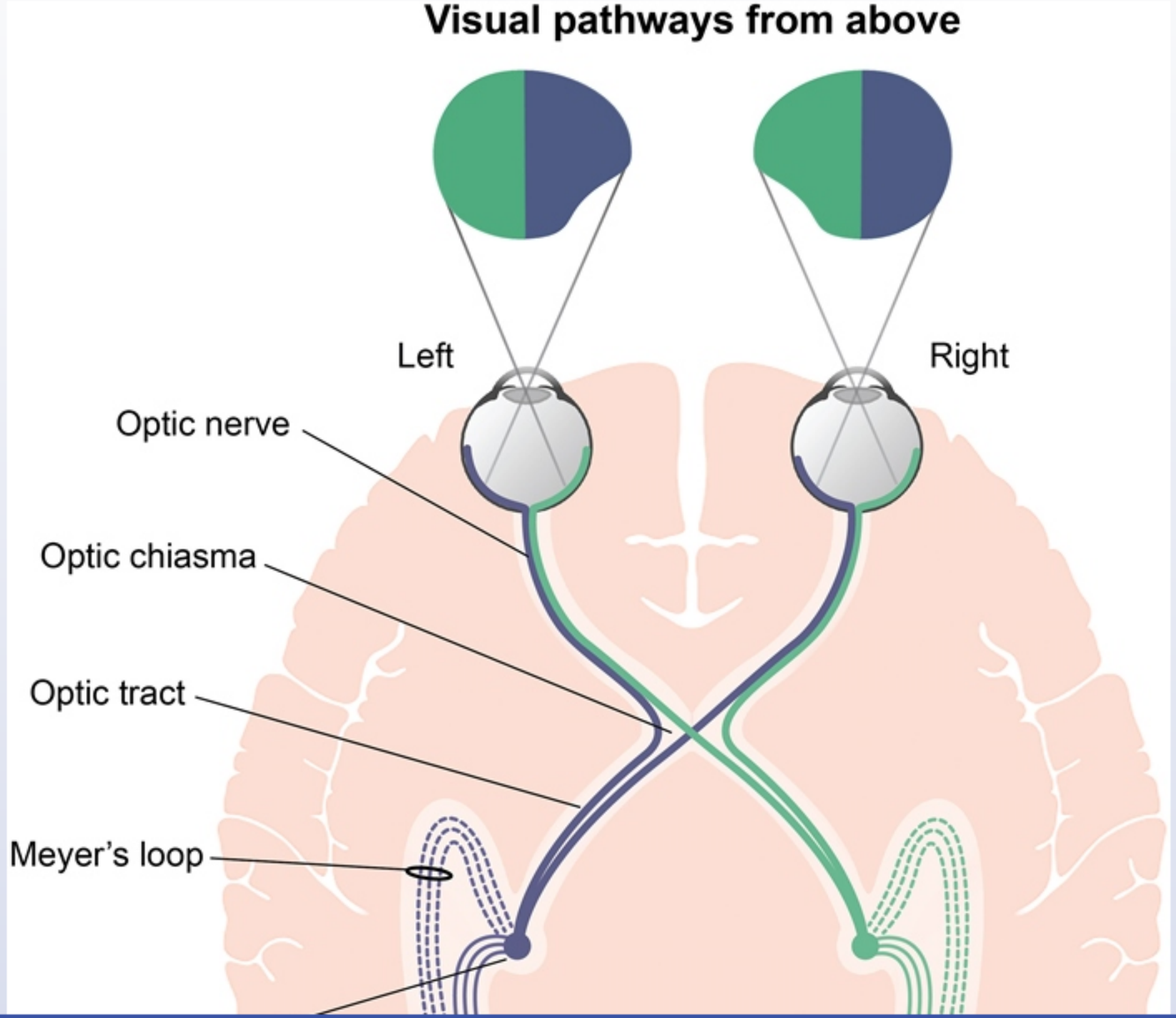

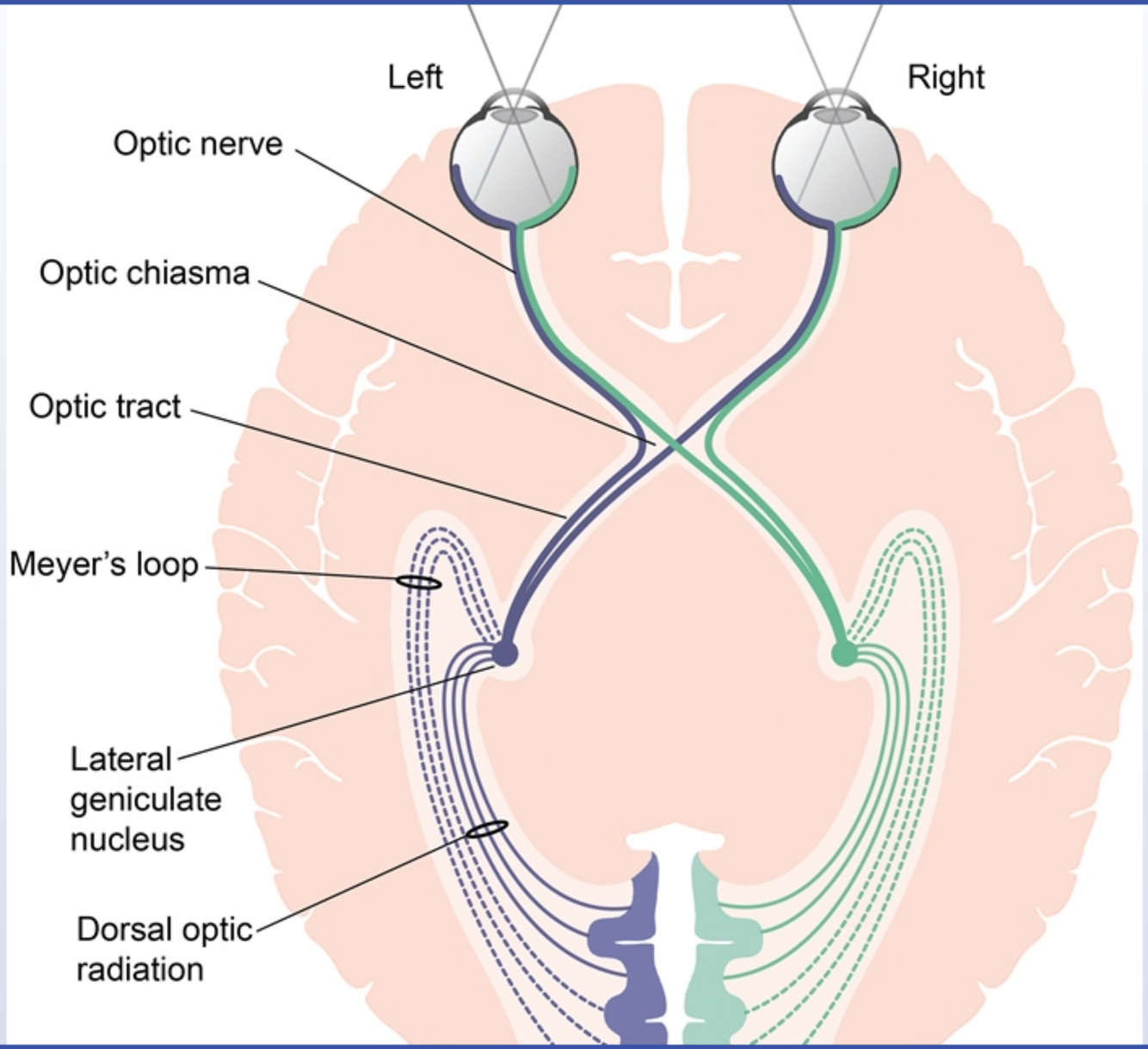
Left
Right
Optic nerve
Optic chiasma
Optic tract
Meyer's loop
Lateral geniculate nucleus
Dorsal optic radiation

6
7
8
9
10
11
12
13
14
15
16
17
18
19
20
21
22
23
24
25
26
27
28
29
30
31
32
33
34
35
36

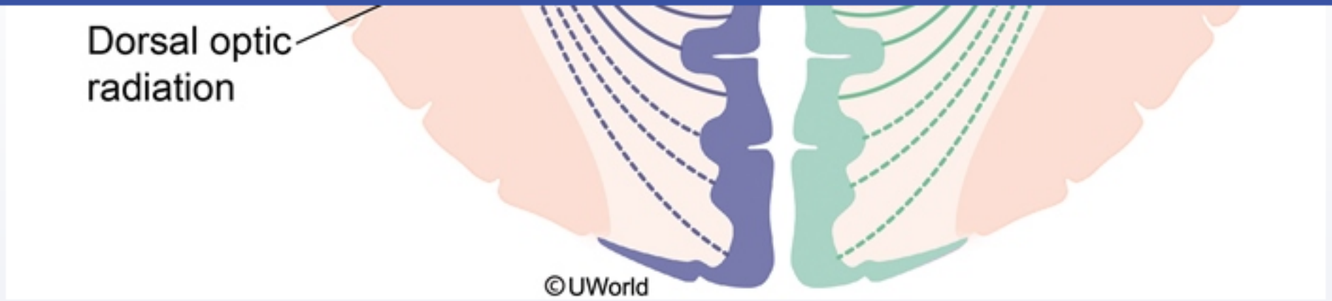

This patient has a hypertensive hemorrhage in the left temporal hemiretina. The left temporal hemiretina receives visual information from the nasal visual field of the left eye. This **visual signal** is transmitted via the left optic nerve to the lateral aspect of the optic chiasm. It then joins the visual signal from the right nasal hemiretina (receives visual information from the temporal visual field of the right eye) and travels via the left optic tract to the left **lateral geniculate body** in the **thalamus**. After this homonymous visual signal leaves the left lateral geniculate body, it travels via the ipsilateral optic radiations to the ipsilateral primary visual cortex for visual processing.

(Choices A, C, G and E) The inferior colliculi and medial geniculate bodies are part of the auditory pathway.

(Choice D) The medial optic chiasm contains crossing nerve fibers that transmit visual information from the bilateral nasal hemiretinas.

(Choice F) The right lateral geniculate body receives visual information from the right temporal hemiretina and the left nasal hemiretina.

Educational objective:
Damage to the left temporal hemiretina will disrupt the transmission of visual information along the ipsilateral optic nerve, lateral optic chiasm, optic tract, lateral geniculate body, optic radiations, and primary visual cortex.

References

- Anatomy of the visual pathways.

Anatomy	Nervous System	Visual pathway
Subject	System	Topic

Copyright © UWorld. All rights reserved.

6
7
8
9
10
11
12
13
14
15
16
17
18
19
20
21
22
23
24
25
26
27
28
29
30
31
32
33
34
35
36

A 62-year-old man is brought to the office by his son due to memory impairment and frequent falls. The patient has been living alone since the death of his wife a year ago. His son, who is visiting from out of town, found his father in poor living conditions. The patient was forgetful and did not know the location of various items in his house, where he has lived for more than 20 years. His gait is also unsteady, and he had had several falls. The son says his father has always been "a drinker" and may have been drinking more recently. The patient is indifferent to his son's concerns and says he feels fine. Vital signs are within normal limits. On physical examination, bilateral lateral gaze palsy and nystagmus are present. Muscle strength and deep tendon reflexes are normal, but the gait is ataxic. On memory testing, he recalls 0 out of 3 objects after 5 minutes. A lesion of which of the following labeled structures on a normal brain MRI is most specifically associated with this patient's current condition?

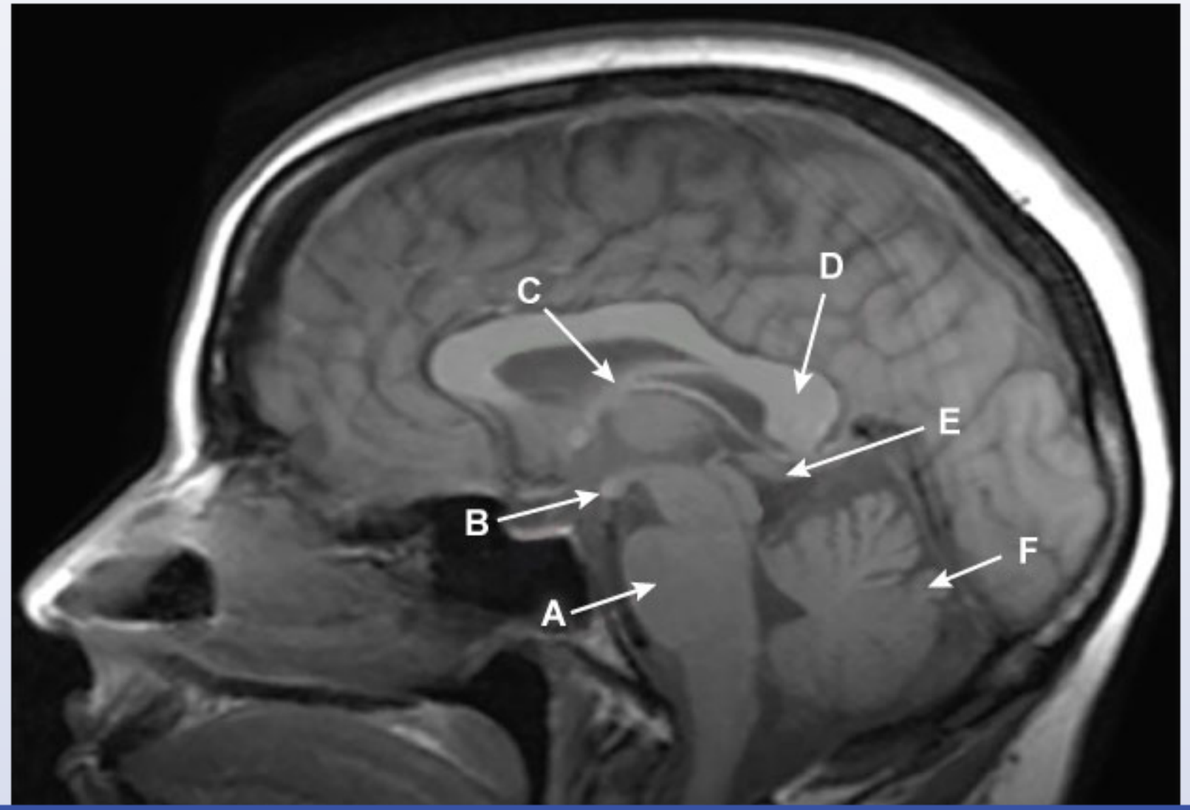

6
7
8
9
10
11
12
13
14
15
16
17
18
19
20
21
22
23
24
25
26
27
28
29
30
31
32
33
34
35
36

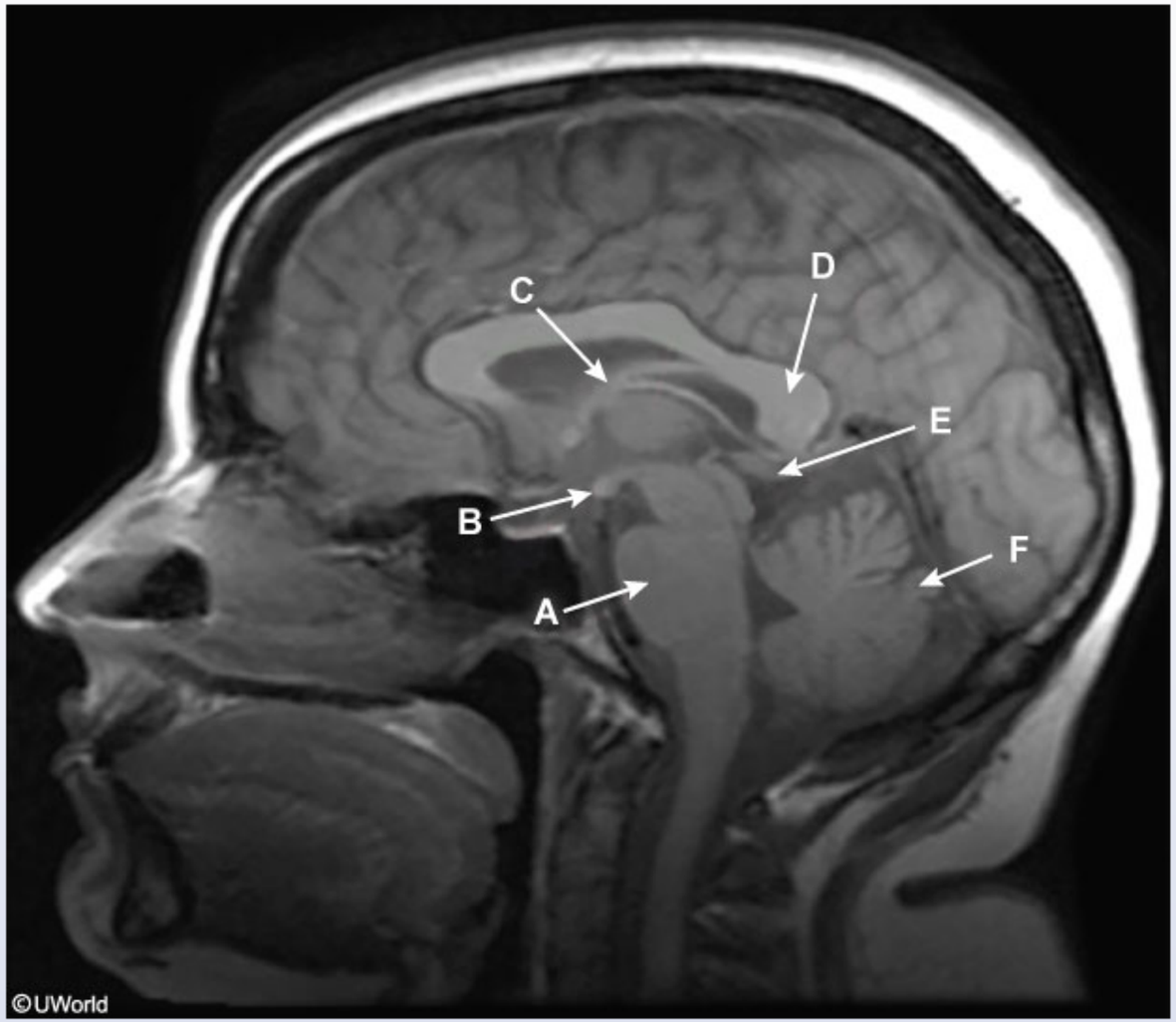

A. A

B. B

6
7
8
9
10
11
12
13
14
15
16
17
18
19
20
21
22
23
24
25
26
27
28
29
30
31
32
33
34
35
36

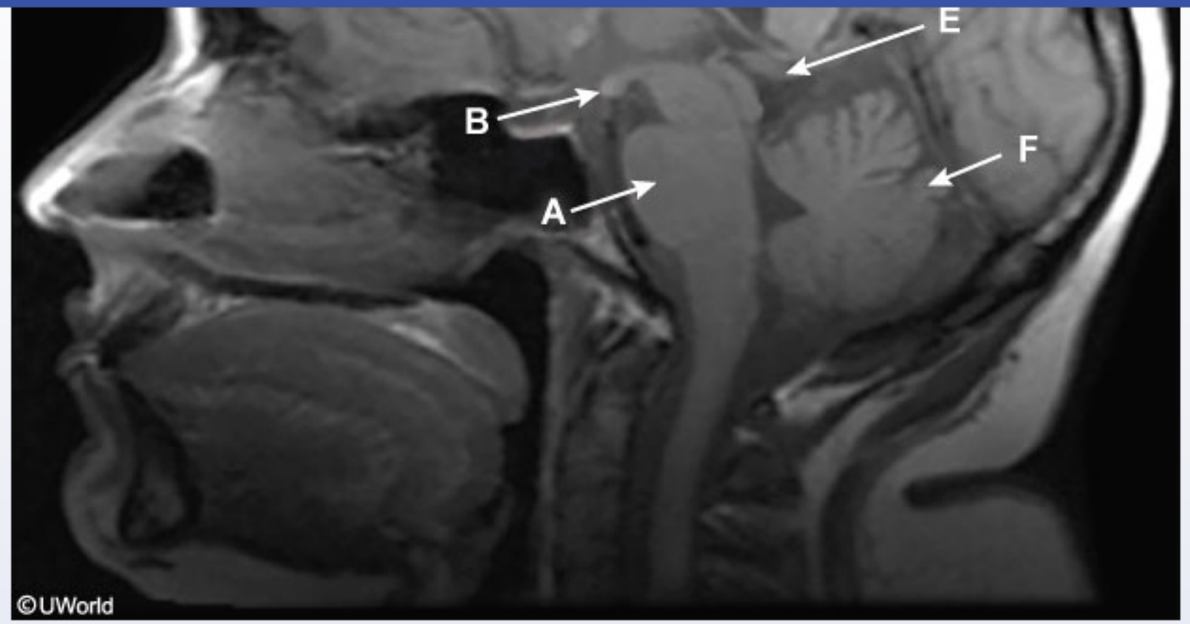

A. A

B. B

C. C

D. D

E. E

F. F

Submit

6
7
8
9
10
11
12
13
14
15
16
17
18
19
20
21
22
23
24
25
26
27
28
29
30
31
32
33
34
35
36

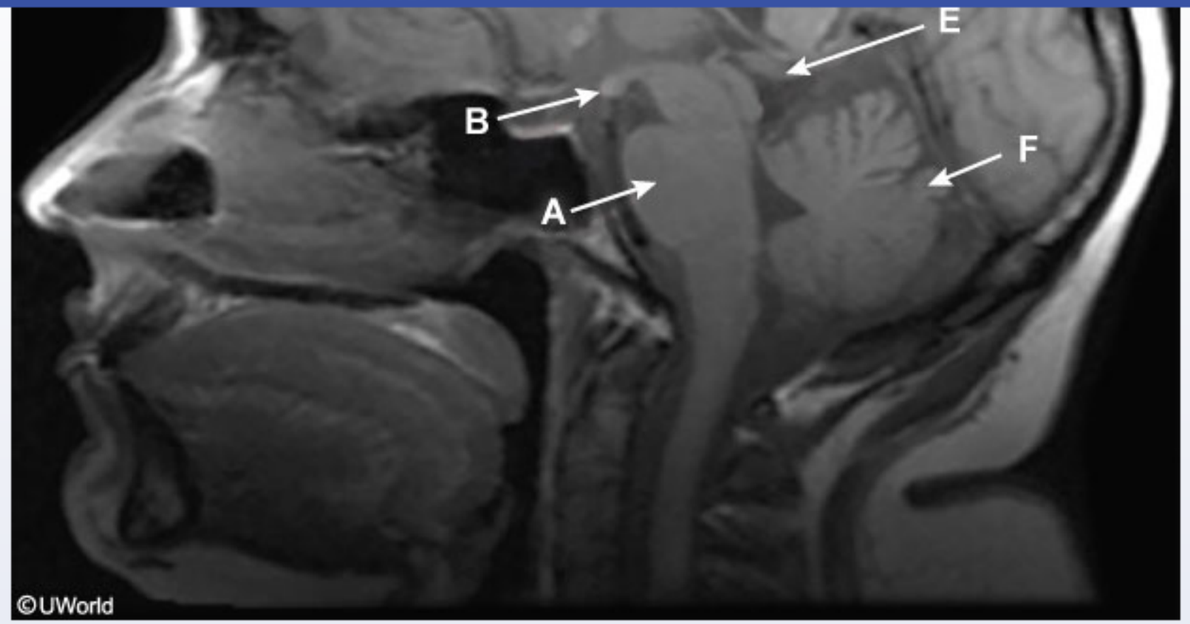

A. A (4%)
B. B (50%) ✓
C. C (8%)
D. D (2%)
E. E (16%)
F. F (18%)

Omitted
Correct answer

50%
Answered correctly

07 secs
Time Spent

03/24/2020
Last Updated

6
7
8
9
10
11
12
13
14
15
16
17
18
19
20
21
22
23
24
25
26
27
28
29
30
31
32
33
34
35
36

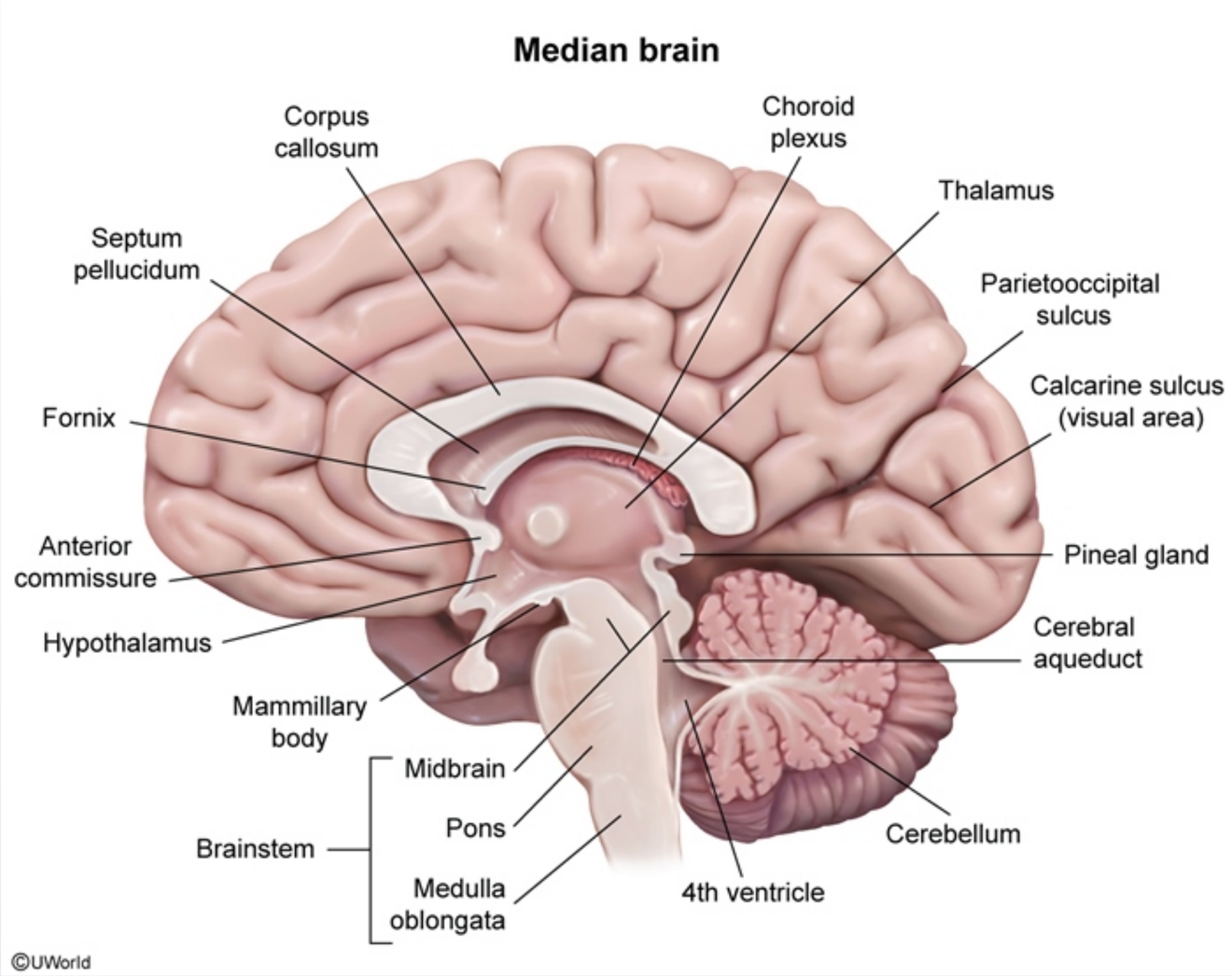

This patient with a suspected history of alcohol abuse has **oculomotor dysfunction** (nystagmus, ophthalmoplegia), **ataxia**, and **encephalopathy** (confusion, anterograde amnesia). This presentation is consistent with the classic triad of **Wernicke encephalopathy** (WE), a complication of

©UWorld

This patient with a suspected history of alcohol abuse has **oculomotor dysfunction** (nystagmus, ophthalmoplegia), **ataxia**, and **encephalopathy** (confusion, anterograde amnesia). This presentation is consistent with the classic triad of **Wernicke encephalopathy** (WE), a complication of thiamine (vitamin B_1) deficiency. **Thiamine** is a cofactor for multiple enzymes involved in glucose metabolism; deficiency results in the brain's inability to use glucose and turn it into energy, leading to neuronal damage and necrosis. Areas of the brain with high metabolic demand are particularly susceptible; the **mammillary bodies** are nearly universally affected and demonstrate focal hemorrhage or atrophy on imaging. Other commonly involved areas include the thalamus, periaqueductal gray substance, and locus caeruleus.

Thiamine deficiency occurs most commonly in patients with **chronic alcoholism** but can also manifest with any form of malnutrition (eg, anorexia, advanced malignancy). Infusion of dextrose-containing solutions without concurrent thiamine supplementation acutely lowers thiamine levels and can precipitate WE; however, some patients with severe deficiency can develop symptoms without a clear inciting event. The **chronic** effects of thiamine deficiency lead to **Korsakoff syndrome**, which is characterized by anterograde and retrograde amnesia, apathy, lack of insight, and confabulation. Attention, social behavior, and long-term memory are relatively preserved.

(Choice A) Demyelination of the pons (central pontine myelinolysis) can occur with overly rapid correction of chronic hyponatremia. It can result in locked-in syndrome, in which patients can move their eyes but cannot move or verbally communicate. The pons is not typically involved in WE.

(Choice C) The fornix is a bundle of axons originating from the hippocampal subiculum that projects to the mammillary bodies. Although it can (rarely) be involved in WE, the mamillary bodies are more specifically associated.

(Choice D) The splenium of the corpus callosum is not typically affected in WE. Lesions (demyelinating or ischemic) in this structure will clinically result in alexia without agraphia.

(Choice E) The pineal gland synthesizes melatonin and is involved in circadian rhythm; it is not typically involved in WE.

(Choice F) Alcoholic cerebellar degeneration also causes ataxia but does not typically cause confusion or ophthalmoplegia. The cerebellum is less frequently involved in WE.

Educational objective:
Wernicke encephalopathy is a complication of thiamine deficiency and is characterized by oculomotor dysfunction, encephalopathy, and ataxia. Chronic deficiency results in Korsakoff syndrome (eg, anterograde and retrograde amnesia, confabulation, apathy). Thiamine is involved in glucose metabolism, and areas of the brain with high metabolic demands are particularly susceptible; the mammillary bodies are most commonly

6
7
8
9
10
11
12
13
14
15
16
17
18
19
20
21
22
23
24
25
26
27
28
29
30
31
32
33
34
35
36

Thiamine deficiency occurs most commonly in patients with **chronic alcoholism** but can also manifest with any form of malnutrition (eg, anorexia, advanced malignancy). Infusion of dextrose-containing solutions without concurrent thiamine supplementation acutely lowers thiamine levels and can precipitate WE; however, some patients with severe deficiency can develop symptoms without a clear inciting event. The **chronic** effects of thiamine deficiency lead to **Korsakoff syndrome**, which is characterized by anterograde and retrograde amnesia, apathy, lack of insight, and confabulation. Attention, social behavior, and long-term memory are relatively preserved.

(Choice A) Demyelination of the pons (central pontine myelinolysis) can occur with overly rapid correction of chronic hyponatremia. It can result in locked-in syndrome, in which patients can move their eyes but cannot move or verbally communicate. The pons is not typically involved in WE.

(Choice C) The fornix is a bundle of axons originating from the hippocampal subiculum that projects to the mammillary bodies. Although it can (rarely) be involved in WE, the mamillary bodies are more specifically associated.

(Choice D) The splenium of the corpus callosum is not typically affected in WE. Lesions (demyelinating or ischemic) in this structure will clinically result in alexia without agraphia.

(Choice E) The pineal gland synthesizes melatonin and is involved in circadian rhythm; it is not typically involved in WE.

(Choice F) Alcoholic cerebellar degeneration also causes ataxia but does not typically cause confusion or ophthalmoplegia. The cerebellum is less frequently involved in WE.

Educational objective:
Wernicke encephalopathy is a complication of thiamine deficiency and is characterized by oculomotor dysfunction, encephalopathy, and ataxia. Chronic deficiency results in Korsakoff syndrome (eg, anterograde and retrograde amnesia, confabulation, apathy). Thiamine is involved in glucose metabolism, and areas of the brain with high metabolic demands are particularly susceptible; the mammillary bodies are most commonly affected.

Anatomy	Nervous System	Wernicke korsakoff syndrome
Subject	System	Topic

Copyright © UWorld. All rights reserved.

6
7
8
9
10
11
12
13
14
15
16
17
18
19
20
21
22
23
24
25
26
27
28
29
30
31
32
33
34
35
36

A 37-year-old previously healthy man comes to the office for evaluation of enlarged lymph nodes. He has an 8-week history of progressively enlarging cervical lymph nodes associated with subjective fevers, fatigue, and drenching night sweats. After initial assessment, the patient undergoes excisional biopsy of enlarged lymph nodes in the left posterior triangle of the neck. Two weeks later, during a follow-up visit, he describes difficulty with overhead activities such as combing his hair or placing dishes on overhead shelves. Examination shows a left shoulder droop with weakness of left arm abduction above 100 degrees. Other shoulder movements are normal, and there is no sensory loss. Which of the following muscles is most likely paralyzed in this patient?

A. Deltoid
B. Latissimus dorsi
C. Levator scapulae
D. Serratus anterior
E. Trapezius

Submit

6
7
8
9
10
11
12
13
14
15
16
17
18
19
20
21
22
23
24
25
26
27
28
29
30
31
32
33
34
35
36

A 37-year-old previously healthy man comes to the office for evaluation of enlarged lymph nodes. He has an 8-week history of progressively enlarging cervical lymph nodes associated with subjective fevers, fatigue, and drenching night sweats. After initial assessment, the patient undergoes excisional biopsy of enlarged lymph nodes in the left posterior triangle of the neck. Two weeks later, during a follow-up visit, he describes difficulty with overhead activities such as combing his hair or placing dishes on overhead shelves. Examination shows a left shoulder droop with weakness of left arm abduction above 100 degrees. Other shoulder movements are normal, and there is no sensory loss. Which of the following muscles is most likely paralyzed in this patient?

A. Deltoid (17%)
B. Latissimus dorsi (3%)
C. Levator scapulae (9%)
D. Serratus anterior (20%)
✓ E. Trapezius (48%)

Omitted
Correct answer
E

48%
Answered correctly

02 secs
Time Spent

02/11/2020
Last Updated

Explanation

Course of the accessory nerve in the neck

6
7
8
9
10
11
12
13
14
15
16
17
18
19
20
21
22
23
24
25
26
27
28
29
30
31
32
33
34
35
36

Course of the accessory nerve in the neck

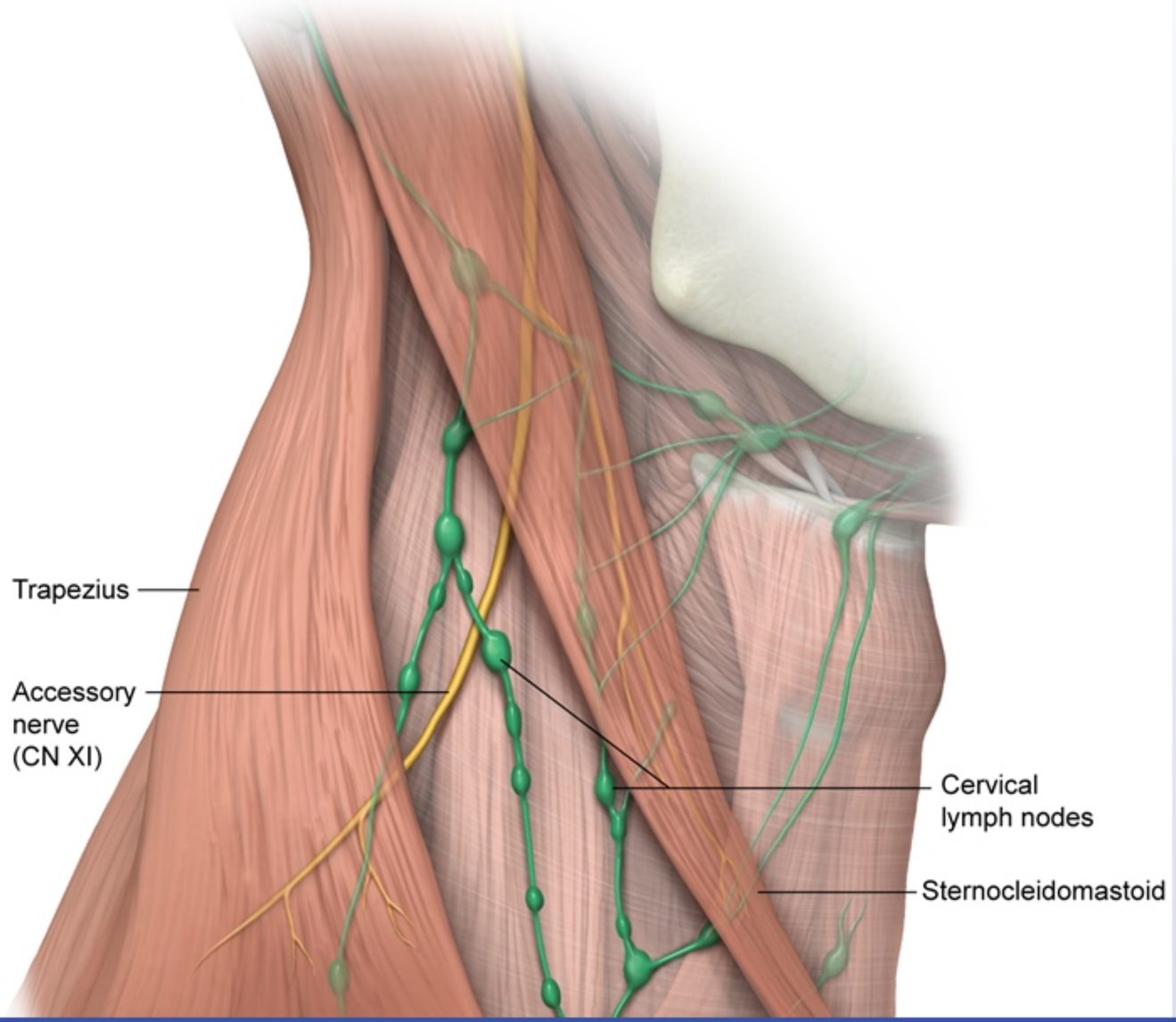

6
7
8
9
10
11
12
13
14
15
16
17
18
19
20
21
22
23
24
25
26
27
28
29
30
31
32
33
34
35
36

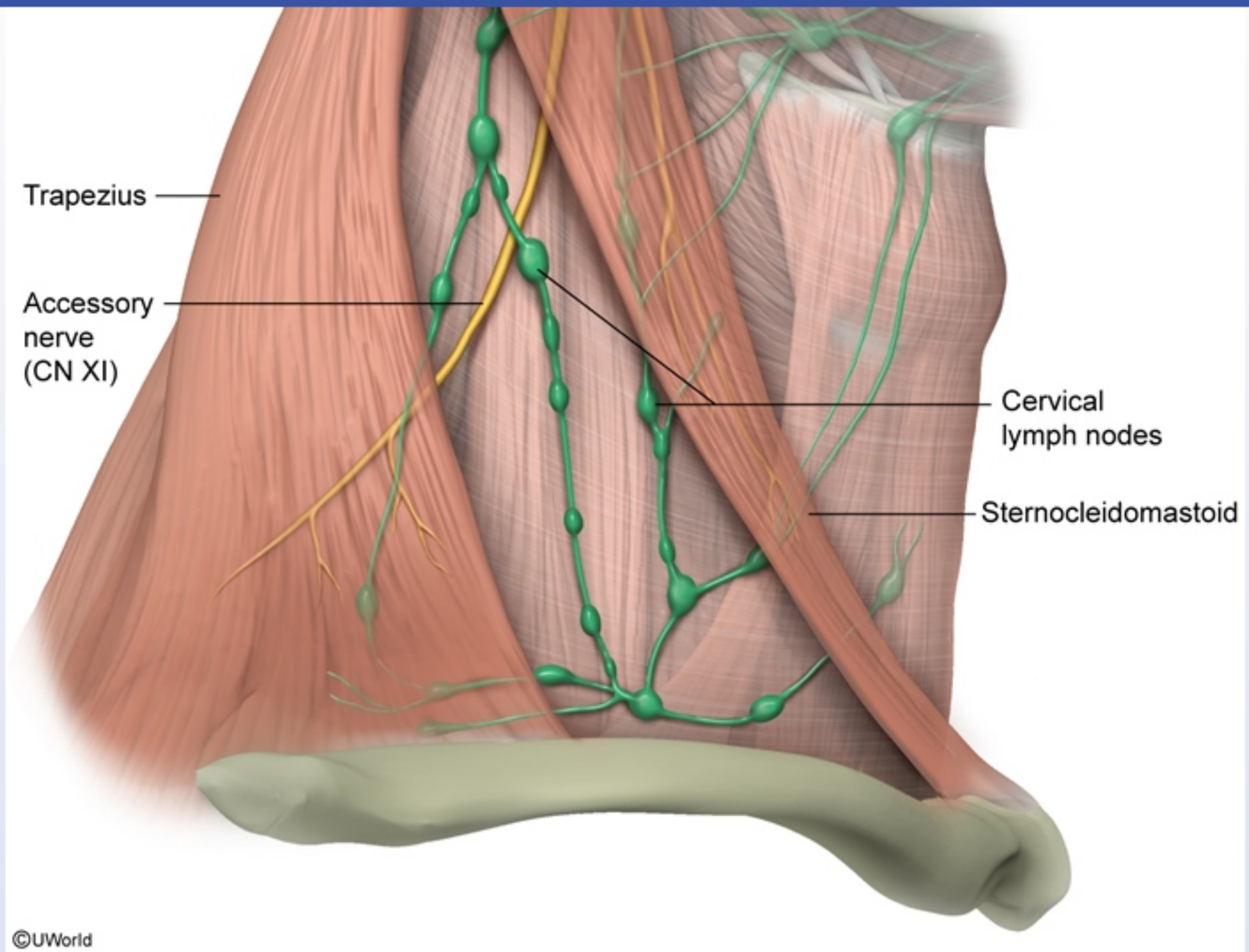

The **spinal accessory nerve** (CN XI) is a pure motor nerve that innervates the sternocleidomastoid and trapezius. It follows a superficial course through the posterior triangle of the neck and is vulnerable to penetrating trauma and **iatrogenic injury** (eg, cervical lymph node dissection).

The trapezius elevates and rotates the scapula upward (eg, during arm abduction) and stabilizes the shoulder. Symptoms of trapezius weakness include **drooping of the shoulder**, impaired abduction of the arm **above 100 degrees**, and lateral displacement of the scapula. If the injury

©UWorld

The **spinal accessory nerve** (CN XI) is a pure motor nerve that innervates the sternocleidomastoid and trapezius. It follows a superficial course through the posterior triangle of the neck and is vulnerable to penetrating trauma and **iatrogenic injury** (eg, cervical lymph node dissection).

The trapezius elevates and rotates the scapula upward (eg, during arm abduction) and stabilizes the shoulder. Symptoms of trapezius weakness include **drooping of the shoulder**, impaired abduction of the arm **above 100 degrees**, and lateral displacement of the scapula. If the injury involves the proximal portions of the nerve, weakness of the sternocleidomastoid may also occur.

(Choice A) The deltoid is innervated by the axillary nerve (C5-6). Injury would cause impaired sensation over the lateral shoulder and weakness in abduction of the arm from 30 to 100 degrees. Iatrogenic axillary nerve injury can occur during shoulder surgery (eg, proximal humerus fracture repair) or intramuscular injection in the deltoid.

(Choice B) The latissimus dorsi is innervated by the thoracodorsal nerve which can be damaged during axillary lymph node dissection. It is the most powerful adductor of the arm and assists with extension and medial rotation.

(Choice C) The levator scapulae is innervated by the C3 and C4 cervical nerves and the dorsal scapular nerve (C5). It acts to elevate the scapula and rotate its medial border inferiorly but does not have a significant effect on arm abduction.

(Choice D) The serratus anterior is innervated by the long thoracic nerve and protracts and rotates the scapula upward, assisting with elevation of the arm over the head. Although weakness of the serratus anterior causes winging of the scapula, it usually occurs following axillary lymph node dissection and would not be associated with shoulder droop.

Educational objective:
The spinal accessory nerve is vulnerable to injury in the posterior triangle of the neck. Injury results in weakness of the trapezius muscle, which presents with drooping of the shoulder, impaired abduction of the arm above 100 degrees, and lateral displacement of the scapula.

References

- Spinal accessory nerve injury: eight cases and review of the literature.

Anatomy	Nervous System	Cranial nerve palsy
Subject	System	Topic

6
7
8
9
10
11
12
13
14
15
16
17
18
19
20
21
22
23
24
25
26
27
28
29
30
31
32
33
34
35
36

A 29-year-old woman comes to the office for treatment of anxiety that has worsened over the past year. She finds herself worrying all the time and fears that she may not complete her graduate studies in time to meet requirements for her degree. The patient is also worried about her son's health and anxiously obsesses about him all the time. She says, "My anxiety just comes out of the blue; one way or another, I'm anxious all the time." The patient has no history of medical problems. Physical examination is unremarkable; complete blood count, chemistry panel, and TSH and B_{12} levels are normal. An anxiety disorder is diagnosed and fluoxetine is prescribed. The patient's anxiety begins to improve over the next 4-6 weeks. The physician explains that the medication inhibits the reuptake of a neurotransmitter released by a specific set of neurons. These neurons are most likely part of which of the following structures?

A. Caudate nucleus
B. Locus ceruleus
C. Nucleus basalis of Meynert
D. Raphe nuclei
E. Red nucleus
F. Substantia nigra

Submit

6
7
8
9
10
11
12
13
14
15
16
17
18
19
20
21
22
23
24
25
26
27
28
29
30
31
32
33
34
35
36

A 29-year-old woman comes to the office for treatment of anxiety that has worsened over the past year. She finds herself worrying all the time and fears that she may not complete her graduate studies in time to meet requirements for her degree. The patient is also worried about her son's health and anxiously obsesses about him all the time. She says, "My anxiety just comes out of the blue; one way or another, I'm anxious all the time." The patient has no history of medical problems. Physical examination is unremarkable; complete blood count, chemistry panel, and TSH and B_{12} levels are normal. An anxiety disorder is diagnosed and fluoxetine is prescribed. The patient's anxiety begins to improve over the next 4-6 weeks. The physician explains that the medication inhibits the reuptake of a neurotransmitter released by a specific set of neurons. These neurons are most likely part of which of the following structures?

- A. Caudate nucleus (5%)
- B. Locus ceruleus (20%)
- C. Nucleus basalis of Meynert (6%)
- ✓ D. Raphe nuclei (61%)
- E. Red nucleus (1%)
- F. Substantia nigra (3%)

Omitted
Correct answer
D

61%
Answered correctly

02 secs
Time Spent

01/12/2020
Last Updated

Explanation

In the **central nervous system (CNS), serotonergic** (serotonin-releasing) **neurons** are primarily found in the **raphe nuclei** of the brainstem. The raphe nuclei are located in the midbrain, pons, and medulla, and axons from these cell bodies project widely throughout the CNS to synapse on

6
7
8
9
10
11
12
13
14
15
16
17
18
19
20
21
22
23
24
25
26
27
28
29
30
31
32
33
34
35
36

In the **central nervous system (CNS), serotonergic** (serotonin-releasing) **neurons** are primarily found in the **raphe nuclei** of the brainstem. The raphe nuclei are located in the midbrain, pons, and medulla, and axons from these cell bodies project widely throughout the CNS to synapse on structures such as the cerebral cortex, thalamus, hypothalamus, cerebellum, hippocampus, and spinal cord. These neurons play a role in the sleep-wake cycle, anxiety, mood, psychosis, sexuality, eating behavior, and impulsivity.

Medications that target serotonin neurons are widely used in psychiatric disorders. Serotonergic antidepressants are the primary pharmacotherapy for most depressive and anxiety disorders. Antidepressants such as selective serotonin reuptake inhibitors (SSRIs [eg, fluoxetine]), serotonin-norepinephrine reuptake inhibitors, and tricyclic antidepressants work by prolonging the amount of time that serotonin spends in the synaptic clefts of these neurons before being taken up by presynaptic neurons.

(Choice A) The caudate nucleus and putamen form the striatum, which functions in motor activities. In Huntington disease, there is loss of cholinergic and GABA-releasing neurons in the striatum.

(Choice B) The locus ceruleus houses norepinephrine-secreting neurons that participate in activation of the "fight or flight" response to physical and emotional stressors. It is located in the dorsal pons. These neurons are implicated in some anxiety symptoms, but they are not serotonergic and not affected by SSRIs.

(Choice C) The nucleus basalis of Meynert houses the cell bodies of cholinergic neurons. In Alzheimer disease, these neurons secrete decreased amounts of acetylcholine.

(Choice E) The red nucleus is located in the anterior midbrain. Its neurons participate in motor coordination of the upper extremities.

(Choice F) The substantia nigra contains dopaminergic neurons. In Parkinson disease, these neurons are depleted.

Educational objective:
Serotonin-releasing neurons in the central nervous system (CNS) are located in the raphe nuclei. These neurons disseminate widely to synapse on numerous structures in the CNS. Antidepressants such as selective serotonin reuptake inhibitors, serotonin-norepinephrine reuptake inhibitors, and tricyclic antidepressants inhibit serotonin reuptake at these synapses.

References

- Stress-related serotonergic systems: implications of symptomatology of anxiety and affectivedisorders.

6
7
8
9
10
11
12
13
14
15
16
17
18
19
20
21
22
23
24
25
26
27
28
29
30
31
32
33
34
35
36

A 26-year-old woman comes to the office due to several weeks of pain and muffled hearing in the left ear, along with a sensation of jaw clicking when chewing food. The patient has had episodic headaches and left-sided facial pain for several years that is worse when moving her jaw. She also has been told that she grinds her teeth while asleep. On examination, the patient is unable to fully open her mouth and reports pain with passive movement of the jaw. The external auditory canal and tympanic membrane are normal. A disorder affecting pterygoid muscle contractility is suspected. Involvement of which of the following nerves is most likely contributing to this patient's ear symptoms?

A. Cervical spinal nerves

B. Facial nerve

C. Mandibular nerve

D. Maxillary nerve

E. Vestibulocochlear nerve

Submit

6
7
8
9
10
11
12
13
14
15
16
17
18
19
20
21
22
23
24
25
26
27
28
29
30
31
32
33
34
35
36

A 26-year-old woman comes to the office due to several weeks of pain and muffled hearing in the left ear, along with a sensation of jaw clicking when chewing food. The patient has had episodic headaches and left-sided facial pain for several years that is worse when moving her jaw. She also has been told that she grinds her teeth while asleep. On examination, the patient is unable to fully open her mouth and reports pain with passive movement of the jaw. The external auditory canal and tympanic membrane are normal. A disorder affecting pterygoid muscle contractility is suspected. Involvement of which of the following nerves is most likely contributing to this patient's ear symptoms?

A. Cervical spinal nerves (0%)
B. Facial nerve (26%)
✓ C. Mandibular nerve (51%)
D. Maxillary nerve (12%)
E. Vestibulocochlear nerve (8%)

Omitted
Correct answer
C

51%
Answered correctly

01 sec
Time Spent

03/22/2020
Last Updated

Explanation

This patient's facial pain, headaches, jaw dysfunction, and ear pain/muffled hearing are characteristic of **temporomandibular disorder** (TMD). The underlying etiology of TMD is multifactorial but includes temporomandibular joint (TMJ) derangement (eg, jaw misalignment, trauma) and **hypersensitivity of the mandibular nerve**.

The mandibular nerve (CN V3) is the largest branch of the **trigeminal nerve** and supplies sensation to the TMJ, floor of the mouth, anterior tongue, and the lower part of the face. It also innervates the muscles of mastication (eg, medial and lateral pterygoid, masseter, temporalis),

6
7
8
9
10
11
12
13
14
15
16
17
18
19
20
21
22
23
24
25
26
27
28
29
30
31
32
33
34
35
36

Explanation

This patient's facial pain, headaches, jaw dysfunction, and ear pain/muffled hearing are characteristic of **temporomandibular disorder** (TMD). The underlying etiology of TMD is multifactorial but includes temporomandibular joint (TMJ) derangement (eg, jaw misalignment, trauma) and **hypersensitivity of the mandibular nerve**.

The mandibular nerve (CN V3) is the largest branch of the **trigeminal nerve** and supplies sensation to the TMJ, floor of the mouth, anterior tongue, and the lower part of the face. It also innervates the muscles of mastication (eg, medial and lateral pterygoid, masseter, temporalis), tensor veli palatini, and the tensor tympani in the middle ear, which dampens loud sounds by tensing the tympanic membrane.

Mechanical derangement of the TMJ can result in irritation and hypersensitivity of the mandibular nerve, leading to pathologic contraction of the pterygoid muscles (worsening the jaw pain and dysfunction) and tensor tympani (causing **ear pain** and **muffled hearing** despite a normal otoscopic examination).

(Choice A) Most patients with TMD have cervical spinal dysfunction and neck pain due to muscular and functional connections between the jaw and cervical regions. However, cervical spinal nerve damage is usually caused by overt structural lesions of the cervical spine (eg, cervical spondylosis, disc herniation) and would not result in ear pain or muffled hearing (but rather neck, shoulder, and arm pain/weakness).

(Choice B) The facial nerve (CN VII) provides sensory innervation to the external auditory canal/concha and motor innervation to the muscles of facial expression and the stapedius muscle, which dampens high-amplitude sound wave transmission. However, the facial nerve does not innervate the pterygoid muscles or TMJ.

(Choice D) The maxillary nerve (CN V2) provides sensory innervation to the cheek, nares, upper lip, and teeth. Involvement of the maxillary nerve in trigeminal neuralgia can cause facial pain; however, muffled hearing and pterygoid muscle dysfunction indicate mandibular nerve involvement.

(Choice E) The vestibulocochlear nerve (CN VIII) carries auditory and balance information from the inner ear. Damage to the cochlear portion of CNVIII (eg, vestibular schwannoma) can result in hearing loss; however, it would not be associated with facial pain or pterygoid muscle dysfunction.

Educational objective:
Temporomandibular disorder is associated with dysfunction of the temporomandibular joint and hypersensitivity of the mandibular nerve (CN V3).

Explanation

Exhibit Display

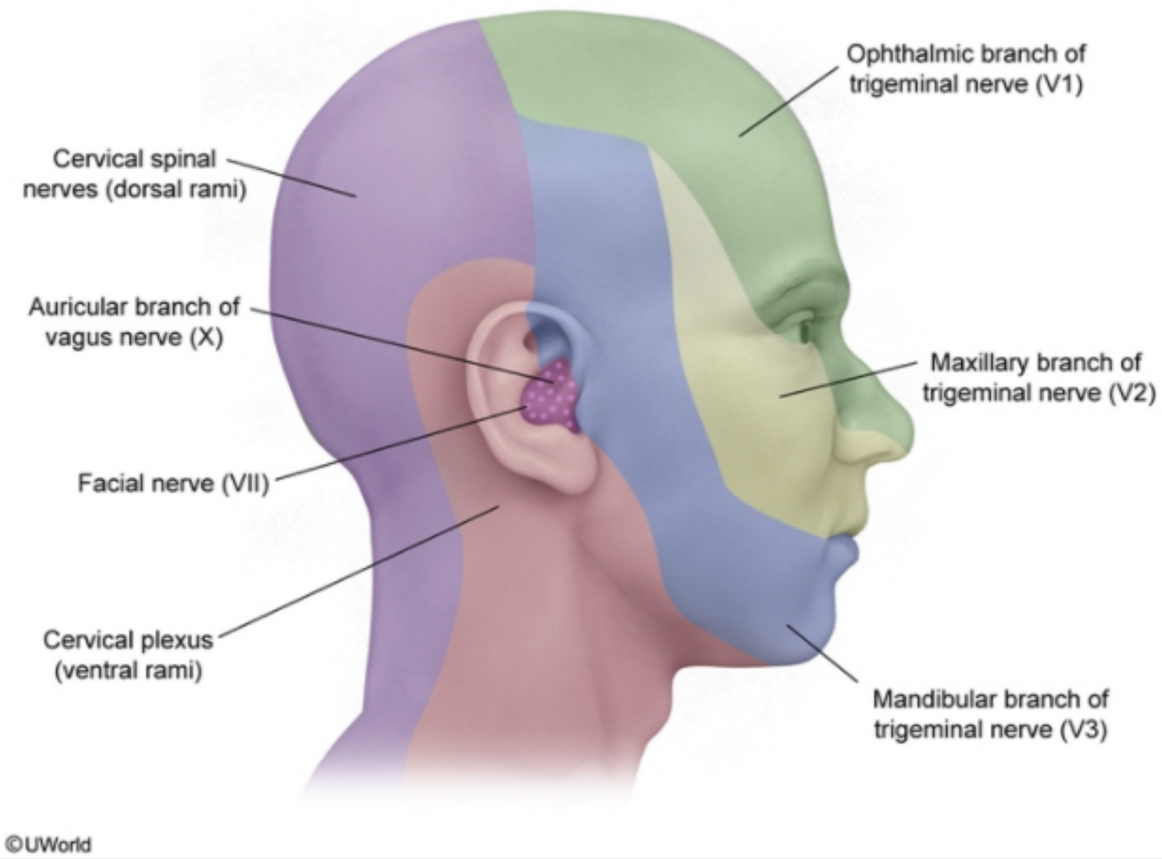

Zoom In | Zoom Out | Reset | Add To New Card | Existing Card

Temporomandibular disorder is associated with dysfunction of the temporomandibular joint and hypersensitivity of the mandibular nerve (CN V3).

6
7
8
9
10
11
12
13
14
15
16
17
18
19
20
21
22
23
24
25
26
27
28
29
30
31
32
33
34
35
36

Explanation

Exhibit Display

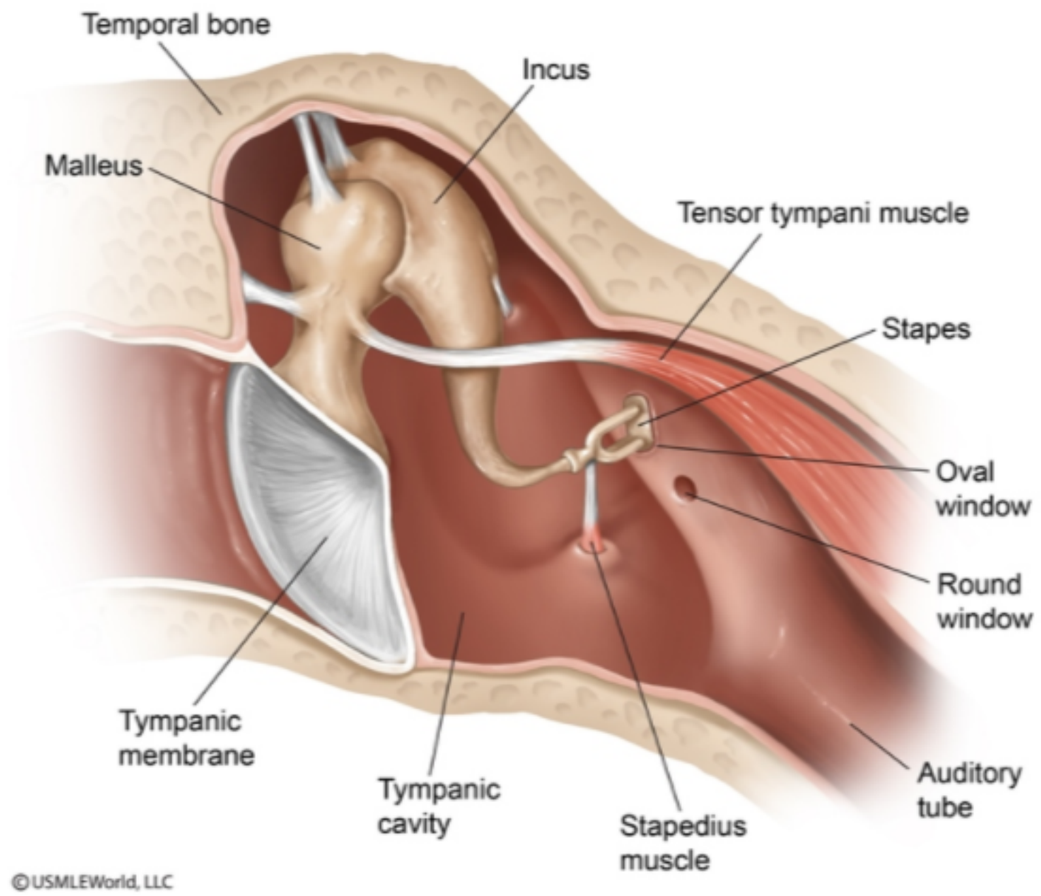

Zoom In | Zoom Out | Reset | Add To New Card | Existing Card

Temporomandibular disorder is associated with dysfunction of the temporomandibular joint and hypersensitivity of the mandibular nerve (CN V3).

6 7 8 9 10 11 12 13 14 15 16 17 18 19 20 21 22 23 24 25 26 27 28 29 30 31 32 33 34 35 36

pterygoid muscles (worsening the jaw pain and dysfunction) and tensor tympani (causing **ear pain** and **muffled hearing** despite a normal otoscopic examination).

(Choice A) Most patients with TMD have cervical spinal dysfunction and neck pain due to muscular and functional connections between the jaw and cervical regions. However, cervical spinal nerve damage is usually caused by overt structural lesions of the cervical spine (eg, cervical spondylosis, disc herniation) and would not result in ear pain or muffled hearing (but rather neck, shoulder, and arm pain/weakness).

(Choice B) The facial nerve (CN VII) provides sensory innervation to the external auditory canal/concha and motor innervation to the muscles of facial expression and the stapedius muscle, which dampens high-amplitude sound wave transmission. However, the facial nerve does not innervate the pterygoid muscles or TMJ.

(Choice D) The maxillary nerve (CN V2) provides sensory innervation to the cheek, nares, upper lip, and teeth. Involvement of the maxillary nerve in trigeminal neuralgia can cause facial pain; however, muffled hearing and pterygoid muscle dysfunction indicate mandibular nerve involvement.

(Choice E) The vestibulocochlear nerve (CN VIII) carries auditory and balance information from the inner ear. Damage to the cochlear portion of CNVIII (eg, vestibular schwannoma) can result in hearing loss; however, it would not be associated with facial pain or pterygoid muscle dysfunction.

Educational objective:
Temporomandibular disorder is associated with dysfunction of the temporomandibular joint and hypersensitivity of the mandibular nerve (CN V3). This can result in pathologic contraction of the pterygoid muscles (eg, jaw pain/dysfunction) and the tensor tympani in the middle ear (eg, ear pain, muffled hearing).

References

- Signs and symptoms of temporomandibular joint disorders related to the degree of mouth opening and hearing loss.

Anatomy	Nervous System	Temporomandibular disorders
Subject	System	Topic

Copyright © UWorld. All rights reserved.

6
7
8
9
10
11
12
13
14
15
16
17
18
19
20
21
22
23
24
25
26
27
28
29
30
31
32
33
34
35
36

A 62-year-old man comes to the physician complaining of double vision. He first noticed mild difficulty focusing his eyes about 3 weeks ago and his symptoms have progressively worsened. The patient's other medical problems include metastatic prostate cancer. On neurologic examination, he is unable to adduct his left eye, and stimulation of the left cornea does not elicit a corneal reflex. A lesion involving which of the following anatomical structures is most likely responsible for this patient's symptoms?

- A. Inferior orbital fissure
- B. Optic canal
- C. Superior orbital fissure
- D. Foramen rotundum
- E. Foramen lacerum
- F. Foramen ovale

Submit

6
7
8
9
10
11
12
13
14
15
16
17
18
19
20
21
22
23
24
25
26
27
28
29
30
31
32
33
34
35
36

A 62-year-old man comes to the physician complaining of double vision. He first noticed mild difficulty focusing his eyes about 3 weeks ago and his symptoms have progressively worsened. The patient's other medical problems include metastatic prostate cancer. On neurologic examination, he is unable to adduct his left eye, and stimulation of the left cornea does not elicit a corneal reflex. A lesion involving which of the following anatomical structures is most likely responsible for this patient's symptoms?

- A. Inferior orbital fissure (6%)
- B. Optic canal (7%)
- ✓ C. Superior orbital fissure (74%)
- D. Foramen rotundum (6%)
- E. Foramen lacerum (1%)
- F. Foramen ovale (3%)

Omitted
Correct answer
C

74%
Answered correctly

02 secs
Time Spent

04/21/2020
Last Updated

Explanation

This patient's diplopia is caused by his inability to adduct his left eye. Eye adduction depends on the oculomotor nerve (CN III) and the medial rectus muscle. The oculomotor nerve originates in the oculomotor nucleus of the midbrain, emerges from the anterior midbrain, and enters the orbit through the superior orbital fissure. The patient also has loss of the corneal reflex on the left side. The sensory limb of the corneal reflex is mediated by the nasociliary branch of the first division of the trigeminal nerve (CN V_1). The motor component of the corneal reflex is carried primarily by the temporal branch of the facial nerve (CN VII). Like the oculomotor nerve, the nasociliary nerve enters the orbit through the superior

6
7
8
9
10
11
12
13
14
15
16
17
18
19
20
21
22
23
24
25
26
27
28
29
30
31
32
33
34
35
36

This patient's diplopia is caused by his inability to adduct his left eye. Eye adduction depends on the oculomotor nerve (CN III) and the medial rectus muscle. The oculomotor nerve originates in the oculomotor nucleus of the midbrain, emerges from the anterior midbrain, and enters the orbit through the superior orbital fissure. The patient also has loss of the corneal reflex on the left side. The sensory limb of the corneal reflex is mediated by the nasociliary branch of the first division of the trigeminal nerve (CN V_1). The motor component of the corneal reflex is carried primarily by the temporal branch of the facial nerve (CN VII). Like the oculomotor nerve, the nasociliary nerve enters the orbit through the superior orbital fissure. Thus, a lesion involving the superior orbital fissure would cause the described deficits.

The trochlear nerve (CN IV), abducens nerve (CN VI), and superior ophthalmic vein also enter the orbit via the superior orbital fissure.

(Choice A) The maxillary division of the trigeminal nerve (CN V_2), the infraorbital vessels, and branches from the sphenopalatine ganglion pass through the inferior orbital fissure but do not enter the orbit.

(Choice B) The optic canal is medial to the superior orbital fissure and transmits only the optic nerve (CN II) and ophthalmic artery.

(Choice D) The foramen rotundum transmits the maxillary division of the trigeminal nerve (CN V_2) from within the skull to the pterygopalatine fossa. From there, it courses through the inferior orbital fissure to appear on the face at the infraorbital foramen as the infraorbital nerve.

(Choice E) The foramen lacerum is occluded by cartilage. The internal carotid artery courses just superior to the foramen lacerum in the lacerum portion of the carotid canal.

(Choice F) The mandibular branch of the trigeminal nerve (CN V_3) passes through the foramen ovale.

Educational objective:
The oculomotor nerve (CN III), ophthalmic nerve (CN V_1) branches, trochlear nerve (CN IV), abducens nerve (CN VI), and superior ophthalmic vein enter the orbit via the superior orbital fissure.

Anatomy	Nervous System	Cranial nerve palsy
Subject	System	Topic

Copyright © UWorld. All rights reserved.

6
7
8
9
10
11
12
13
14
15
16
17
18
19
20
21
22
23
24
25
26
27
28
29
30
31
32
33
34
35
36

A 48-year-old man comes to the hospital after a day of high-grade fever, progressive headache, and double vision. The patient has been having purulent nasal drainage and frontal headache for the past several days. He has a history of type 2 diabetes mellitus. His temperature is 38.9 C (102 F), blood pressure is 110/70 mm Hg, and pulse is 94/min. Physical examination shows ptosis, mydriasis, mild proptosis, and loss of the corneal reflex of the right eye. Visual acuity is normal in both eyes, but the patient is unable to move the right eye in any direction. There is decreased sensation in the right upper face. Which of the following structures is most likely involved in this patient's presentation?

A. Brainstem
B. Cavernous sinus
C. Frontal lobe of brain
D. Inferior orbital fissure
E. Jugular foramen
F. Optic chiasm

Submit

A 48-year-old man comes to the hospital after a day of high-grade fever, progressive headache, and double vision. The patient has been having purulent nasal drainage and frontal headache for the past several days. He has a history of type 2 diabetes mellitus. His temperature is 38.9 C (102 F), blood pressure is 110/70 mm Hg, and pulse is 94/min. Physical examination shows ptosis, mydriasis, mild proptosis, and loss of the corneal reflex of the right eye. Visual acuity is normal in both eyes, but the patient is unable to move the right eye in any direction. There is decreased sensation in the right upper face. Which of the following structures is most likely involved in this patient's presentation?

- A. Brainstem (7%)
- ✓ B. Cavernous sinus (74%)
- C. Frontal lobe of brain (2%)
- D. Inferior orbital fissure (12%)
- E. Jugular foramen (2%)
- F. Optic chiasm (1%)

Omitted
Correct answer
B

74%
Answered correctly

02 secs
Time Spent

05/13/2020
Last Updated

Explanation

6
7
8
9
10
11
12
13
14
15
16
17
18
19
20
21
22
23
24
25
26
27
28
29
30
31
32
33
34
35
36

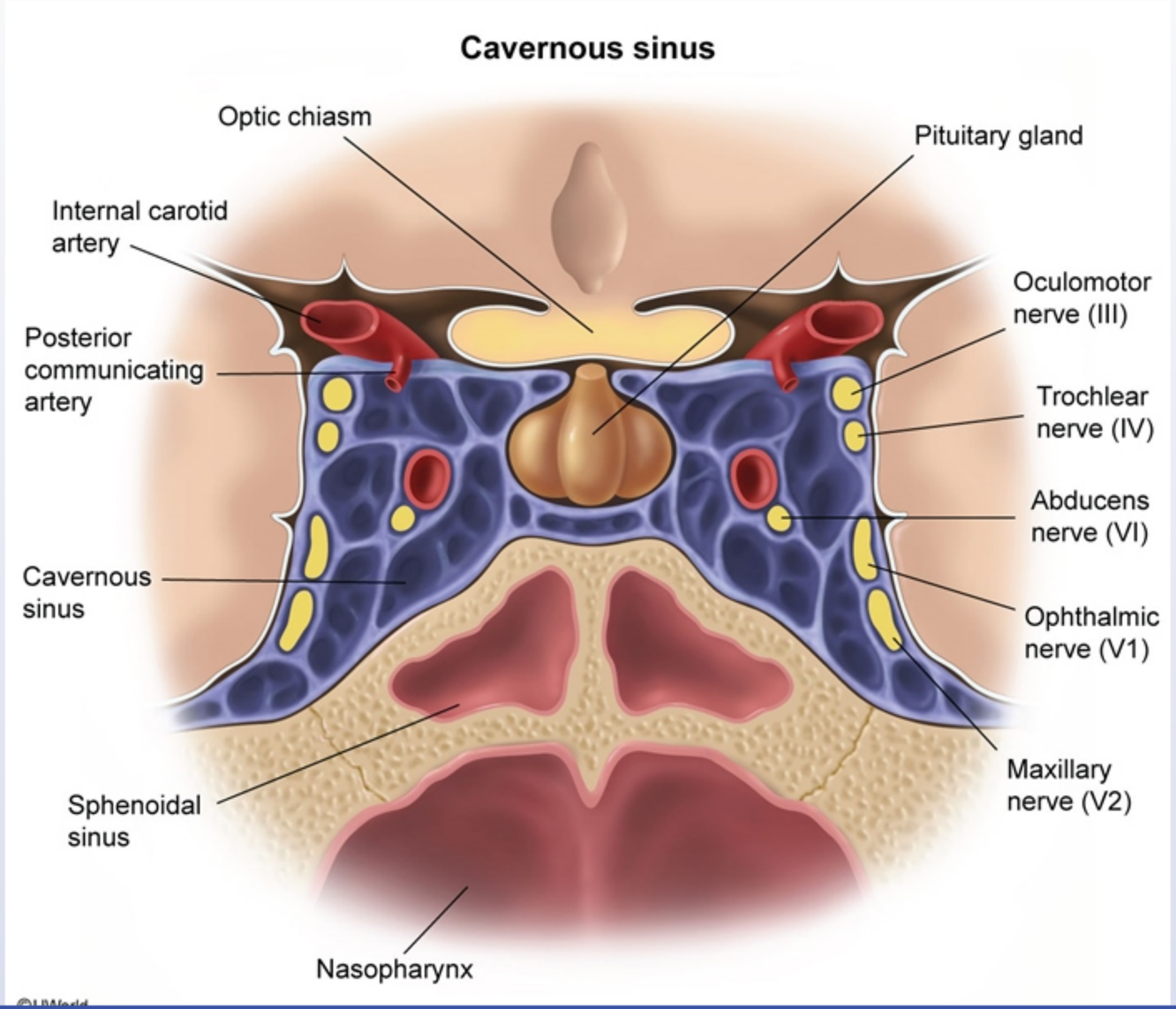

©UWorld

Cavernous sinus thrombosis is most commonly due to contiguous spread of an infection from the medial third of the face, sinuses (ethmoidal or sphenoidal), or teeth. The infection can communicate in a retrograde fashion into the cavernous sinus through the valveless facial venous system (via the superior and inferior ophthalmic veins). Common pathogens include *Staphylococcus aureus* (most common) and streptococci, although fungal organisms (eg, *Mucor*, *Rhizopus*) are responsible in rare cases.

Patients typically experience headache, fever, and diplopia. Ocular muscle paralysis occurs due to injury of **cranial nerves (CNs) III, IV, and VI**. CN III palsy may also result in ptosis and mydriasis. Involvement of the ophthalmic and maxillary branches of **CN V** can cause loss of both upper facial sensation and the afferent limb of the corneal reflex. Proptosis (eye protrusion) and chemosis (conjunctival swelling) may also be evident due to impaired venous drainage through the ophthalmic veins.

(Choice A) Brainstem lesions typically result in crossed signs (ipsilateral cranial nerve palsies and contralateral hemiparesis), vertigo, and ataxia.

(Choice C) Frontal lobe pathology can cause disinhibition, problems with planning/organizing, and personality changes. CN deficits are not characteristic.

(Choice D) The inferior orbital fissure transmits the maxillary division of CN V, infraorbital vessels, and branches from the sphenopalatine ganglion.

(Choice E) Lesions of the jugular foramen can result in jugular foramen (Vernet) syndrome, which is characterized by the dysfunction of CNs IX, X, and XI. Findings include dysphagia, hoarseness, loss of gag reflex on the ipsilateral side, and deviation of the uvula toward the normal side.

(Choice F) The optic chiasm is superior to the cavernous sinus and is where the optic nerve fibers from the nasal side of each retina cross to the opposite side of the brain. Optic chiasm lesions typically cause bitemporal hemianopia, which is absent in this patient.

Educational objective:
Infection of the medial face, sinuses (ethmoidal or sphenoidal), or teeth may spread through the valveless facial venous system into the cavernous sinus, resulting in cavernous sinus thrombosis. Patients typically present with headache, fever, proptosis, and ipsilateral deficits in cranial nerves III, IV, VI, and V (ophthalmic and maxillary branches).

References

- Septic thrombosis of the cavernous sinuses.

6
7
8
9
10
11
12
13
14
15
16
17
18
19
20
21
22
23
24
25
26
27
28
29
30
31
32
33
34
35
36

A 32-year-old man undergoes evaluation for episodes of paroxysmal supraventricular tachycardia. An electrophysiology study reveals focal atrial tachycardia that originates in the crista terminalis of the right atrium. Radiofrequency ablation is planned to destroy the ectopic focus and treat the arrhythmia. Which of the following nerves is in close proximity to the treatment site and is at risk for injury during the ablation?

A. Accessory nerve
B. Long thoracic nerve
C. Phrenic nerve
D. Recurrent laryngeal nerve
E. Sympathetic trunk

Submit

A 32-year-old man undergoes evaluation for episodes of paroxysmal supraventricular tachycardia. An electrophysiology study reveals focal atrial tachycardia that originates in the crista terminalis of the right atrium. Radiofrequency ablation is planned to destroy the ectopic focus and treat the arrhythmia. Which of the following nerves is in close proximity to the treatment site and is at risk for injury during the ablation?

- A. Accessory nerve (1%)
- B. Long thoracic nerve (3%)
- ✓ C. Phrenic nerve (55%)
- D. Recurrent laryngeal nerve (29%)
- E. Sympathetic trunk (11%)

Omitted
Correct answer
C

55%
Answered correctly

02 secs
Time Spent

03/17/2020
Last Updated

Explanation

6
7
8
9
10
11
12
13
14
15
16
17
18
19
20
21
22
23
24
25
26
27
28
29
30
31
32
33
34
35
36

Phrenic nerve injury during catheter ablation

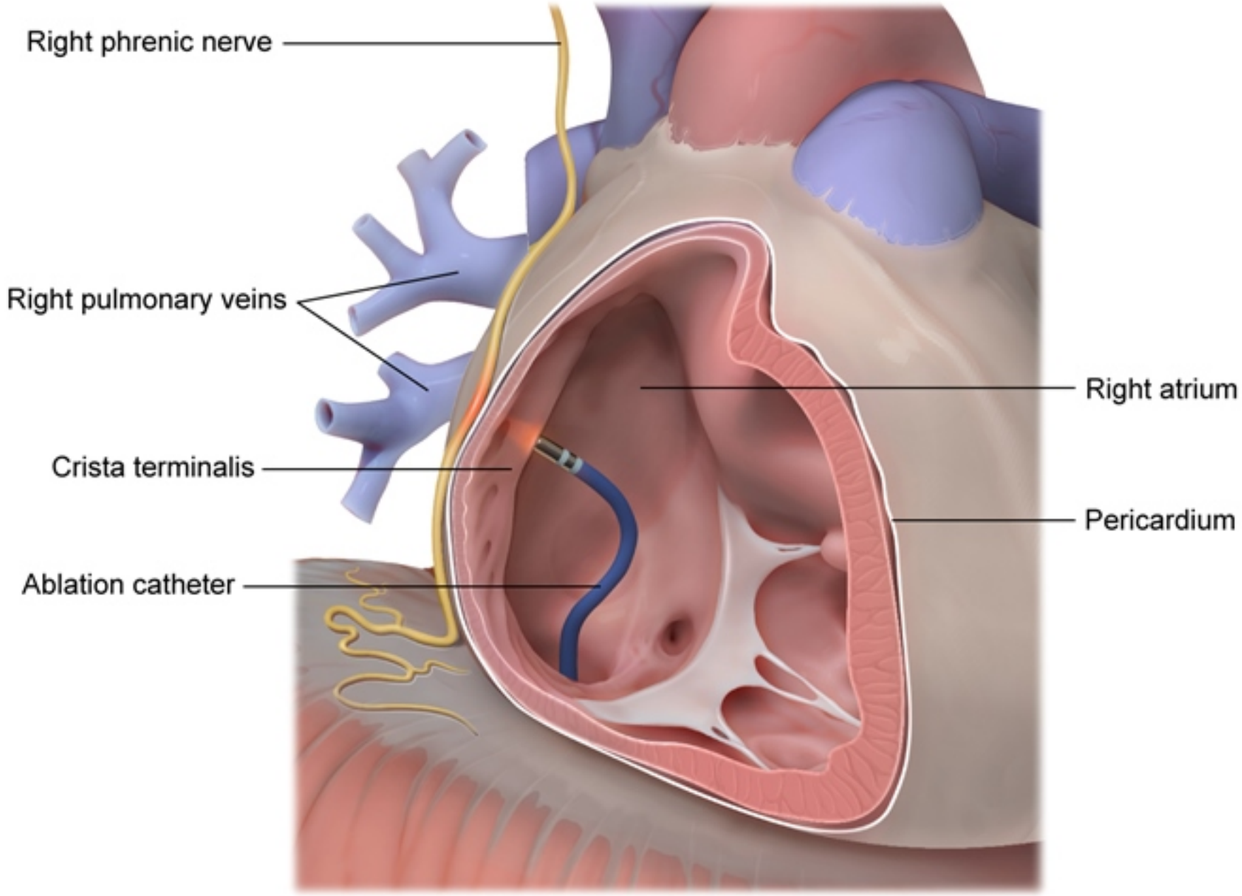

©UWorld

Paroxysmal supraventricular tachycardias (PSVTs) are arrhythmias that occur intermittently and have abrupt onset and offset. They arise from regions of abnormal electrical activity that occur in the atrioventricular node, an accessory pathway, or the atria. **Radiofrequency ablation** can be used to destroy the inciting cardiomyocytes and cure the arrhythmia.

Paroxysmal supraventricular tachycardias (PSVTs) are arrhythmias that occur intermittently and have abrupt onset and offset. They arise from regions of abnormal electrical activity that occur in the atrioventricular node, an accessory pathway, or the atria. **Radiofrequency ablation** can be used to destroy the inciting cardiomyocytes and cure the arrhythmia.

The crista terminalis, located in the **right atrium**, is a common site of origination for atrial PSVT. However, the **right phrenic nerve**, which innervates to the right hemidiaphragm, courses along the pericardium that overlies the right atrium and is at risk of injury during procedures that target structures in or near the right atrium (eg, crista terminalis, cavotricuspid isthmus, right-sided pulmonary veins). Such injury is typically recognized by **elevation of the right hemidiaphragm** on chest x-ray.

(Choice A) The spinal root of the accessory nerve (cranial nerve XI) courses superiorly from the upper spinal cord through the foramen magnum to join with the cranial root. The combined roots then exit the cranium through the jugular foramen to provide motor innervation to the sternocleidomastoid and trapezius muscles. There is risk of injury during biopsy or lymph node dissection in the neck, but not during procedures involving the right atrium.

(Choice B) The long thoracic nerve arises from the lower cervical spinal cord and courses laterally and inferiorly to provide motor innervation to the serratus anterior muscle. Injury can occur during breast surgery or chest-tube placement (resulting in a "winged" scapula); however, due to its lateral location, the nerve is not at risk of injury during procedures involving the right atrium.

(Choice D) The recurrent laryngeal nerve is a branch of the vagus nerve (cranial nerve X) that courses underneath the aortic arch on the left and the brachiocephalic trunk on the right to provide motor, sensory, and parasympathetic innervation to the upper esophagus, trachea, and portions of the larynx. It is at risk of injury during thyroid surgery but not during procedures involving the right atrium.

(Choice E) The sympathetic trunk parallels the length of the spinal column on both sides and provides sympathetic innervation throughout the body. Injury leads to Horner syndrome (ie, miosis, ptosis, anhydrosis) and can occur during spinal surgery, but not during procedures involving the right atrium.

Educational objective:
The right phrenic nerve courses along the pericardium overlying the right side of the heart and is at risk for injury during procedures in or near the right atrium (eg, radiofrequency ablation). Right phrenic nerve injury is typically recognized by elevation of the right hemidiaphragm.

Anatomy Nervous System Diaphragmatic paralysis

Paroxysmal supraventricular tachycardias (PSVTs) are arrhythmias that occur intermittently and have abrupt onset and offset. They arise from

Exhibit Display

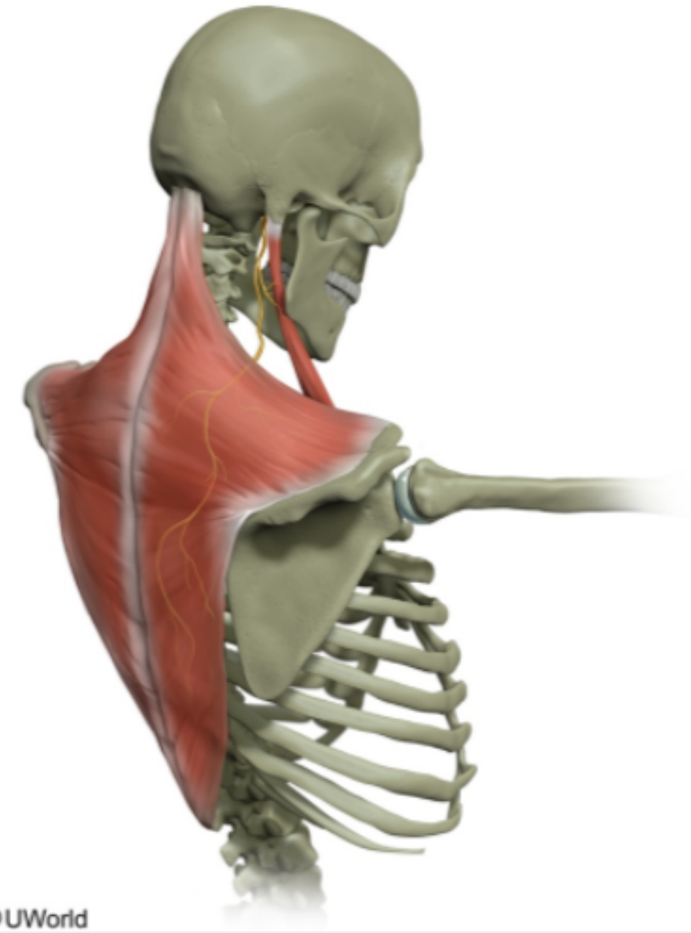

Zoom In | Zoom Out | Reset | Add To New Card | Existing Card

Anatomy | Nervous System | Diaphragmatic paralysis

Paroxysmal supraventricular tachycardias (PSVTs) are arrhythmias that occur intermittently and have abrupt onset and offset. They arise from

Exhibit Display

Laryngeal nerves

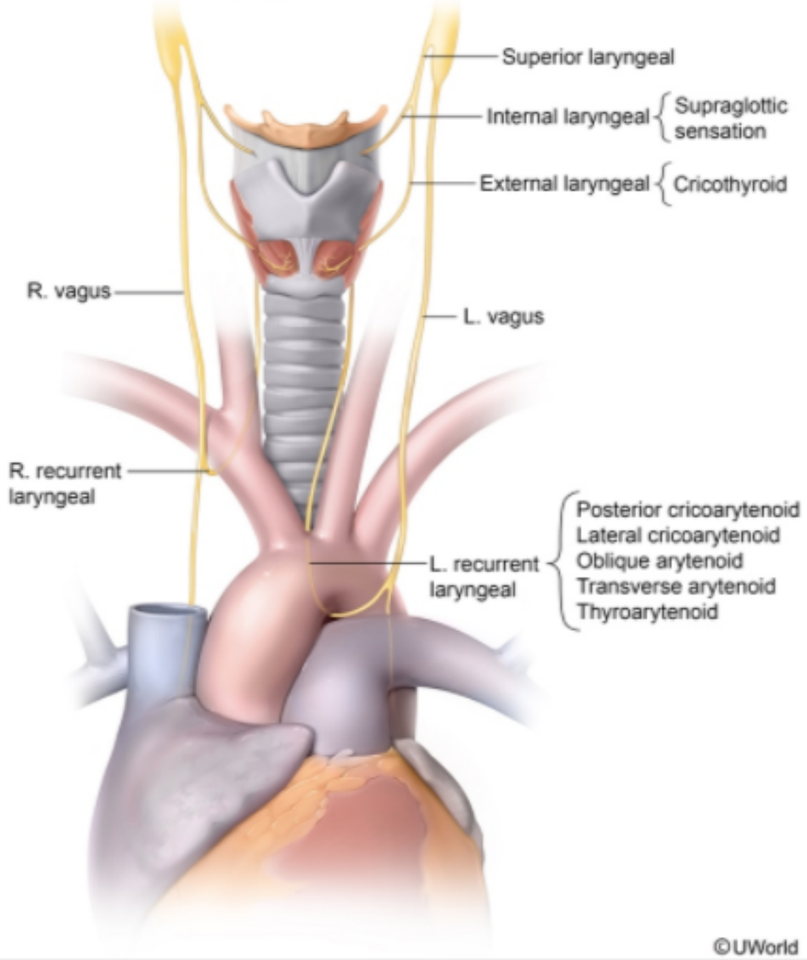

Zoom In | Zoom Out | Reset | Add To New Card | Existing Card

Anatomy | Nervous System | Diaphragmatic paralysis

6
7
8
9
10
11
12
13
14
15
16
17
18
19
20
21
22
23
24
25
26
27
28
29
30
31
32
33
34
35
36

A 53-year-old man comes to the office due to double vision. The patient lives in a two-story house and has had difficulty walking down stairs because he sees duplicates of every step and doesn't "know which ones are real." He does not have significant problems walking up stairs. The patient is also frustrated because he has trouble reading certain things, such as the morning newspaper and work-related documents. He has had no eye trauma, headache, focal weakness, or numbness. The patient has a history of hypertension and type 2 diabetes mellitus. He exercises regularly and does not use tobacco, alcohol, or illicit drugs. A lesion affecting which of the following structures is most likely responsible for this patient's visual symptoms?

A. Abducens nerve
B. Medial longitudinal fasciculus
C. Oculomotor nerve
D. Optic nerve
E. Trochlear nerve

Submit

A 53-year-old man comes to the office due to double vision. The patient lives in a two-story house and has had difficulty walking down stairs because he sees duplicates of every step and doesn't "know which ones are real." He does not have significant problems walking up stairs. The patient is also frustrated because he has trouble reading certain things, such as the morning newspaper and work-related documents. He has had no eye trauma, headache, focal weakness, or numbness. The patient has a history of hypertension and type 2 diabetes mellitus. He exercises regularly and does not use tobacco, alcohol, or illicit drugs. A lesion affecting which of the following structures is most likely responsible for this patient's visual symptoms?

- A. Abducens nerve (7%)
- B. Medial longitudinal fasciculus (10%)
- C. Oculomotor nerve (20%)
- D. Optic nerve (6%)
- ✓ E. Trochlear nerve (54%)

Omitted
Correct answer
E

54%
Answered correctly

02 secs
Time Spent

06/23/2020
Last Updated

Explanation

6
7
8
9
10
11
12
13
14
15
16
17
18
19
20
21
22
23
24
25
26
27
28
29
30
31
32
33
34
35
36

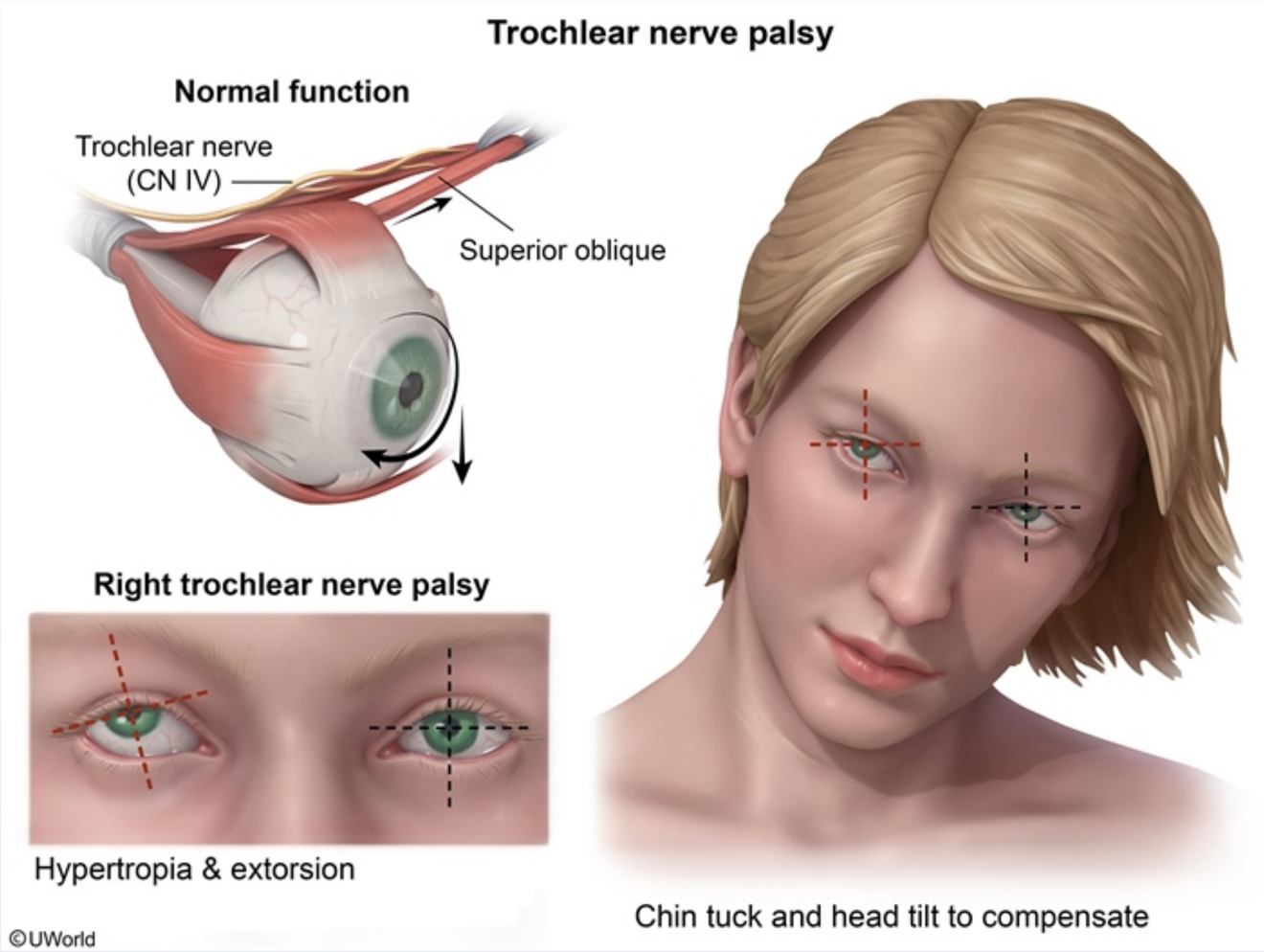

This patient likely has **trochlear nerve (CN IV) palsy**. The trochlear nerve innervates the superior oblique muscle, which causes the eye to **intort** (internally rotate) and **depress while adducted**. The nerve is particularly susceptible to injury due to its long course and small caliber. Most cases of neuropathy are traumatic or idiopathic in origin, although a proportion of idiopathic cases may actually be due to microvascular nerve ischemia in the setting of diabetes mellitus. Patients with trochlear nerve palsy typically present with **vertical diplopia**, which is most noticeable

This patient likely has **trochlear nerve (CN IV) palsy**. The trochlear nerve innervates the superior oblique muscle, which causes the eye to **intort** (internally rotate) and **depress while adducted**. The nerve is particularly susceptible to injury due to its long course and small caliber. Most cases of neuropathy are traumatic or idiopathic in origin, although a proportion of idiopathic cases may actually be due to microvascular nerve ischemia in the setting of diabetes mellitus. Patients with trochlear nerve palsy typically present with **vertical diplopia**, which is most noticeable when the affected eye looks down and toward the nose (eg, up-close reading, **walking down stairs**). Examination may show impairment of downgaze with the eye in the adducted position. In severe cases, the affected eye can appear vertically deviated (hypertropia). Symptoms often improve when the chin is tucked and the head is tilted away from the affected eye as this compensates for hypertropia and extorsion.

(Choice A) The abducens nerve (cranial nerve [CN] VI) innervates the lateral rectus, which is responsible for abduction of the eye. Palsies of this nerve can cause horizontal diplopia and inward deviation (esotropia).

(Choice B) Lesions of the medial longitudinal fasciculus are associated with internuclear ophthalmoplegia. This typically presents with impaired horizontal eye movement and weak adduction of the affected eye with simultaneous abduction nystagmus of the contralateral eye.

(Choice C) The oculomotor nerve (CN III) innervates the superior rectus, medial rectus, inferior rectus, and inferior oblique. These muscles collectively perform most eye movements. Palsies of this nerve can cause vertical and horizontal diplopia, ptosis, and an enlarged and nonreactive pupil.

(Choice D) The optic nerve (CN II) transmits visual information to the brain. Damage to this nerve causes loss of vision.

Educational objective:
The trochlear nerve innervates the superior oblique muscle, which causes the eye to intort (internally rotate) and depress while adducted. Trochlear nerve palsy is typically traumatic or idiopathic and presents with vertical diplopia that worsens when the affected eye looks down and toward the nose (eg, walking downstairs, up-close reading). Patients may compensate by tucking the chin and tilting the head away from the affected eye.

References

- Adult hypertropia: a guide to diagnostic evaluation based on review of 300 patients.

Anatomy	Nervous System	Cranial nerve palsy
Subject	System	Topic

6
7
8
9
10
11
12
13
14
15
16
17
18
19
20
21
22
23
24
25
26
27
28
29
30
31
32
33
34
35
36

A 68-year-old man is evaluated for visual loss in the left eye that resolved spontaneously within several hours. The patient has a history of hypertension, type 2 diabetes mellitus, coronary artery disease, and ischemic cardiomyopathy. He has smoked a pack of cigarettes daily for the past 40 years. Physical examination reveals a left carotid bruit but no neurologic deficits. A carotid duplex ultrasound shows 85% stenosis of the left internal carotid artery, and carotid angiography with stenting is performed. During the procedure, atherosclerotic debris embolize to the artery shown (red arrow) on the cerebral magnetic resonance angiograph below.

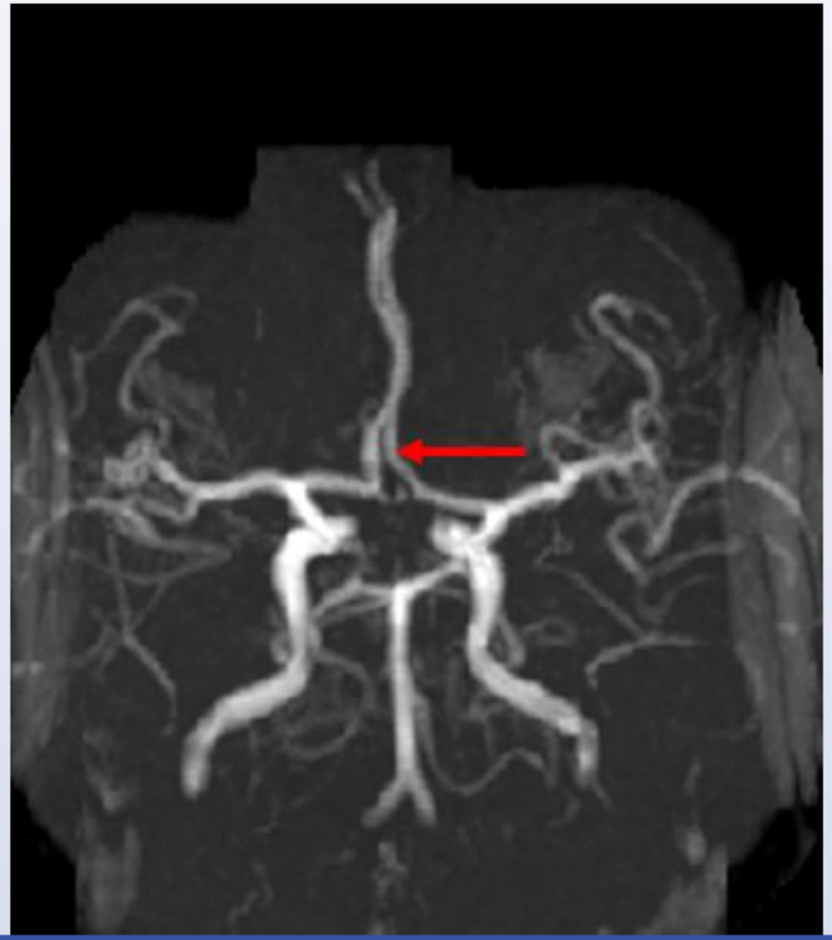

6
7
8
9
10
11
12
13
14
15
16
17
18
19
20
21
22
23
24
25
26
27
28
29
30
31
32
33
34
35
36

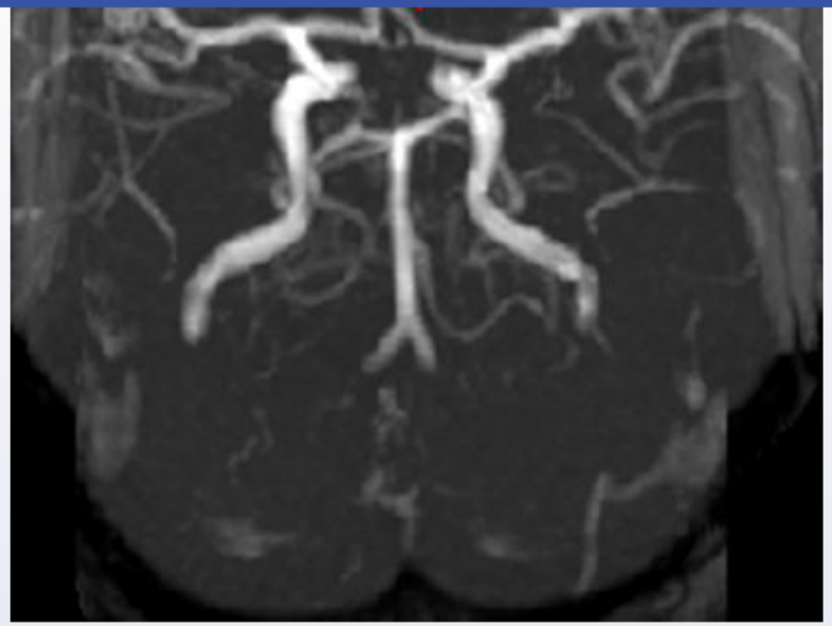

Which of the following actions is most likely to be impaired in this patient?

- A. Climbing stairs
- B. Gripping
- C. Speaking
- D. Swallowing food
- E. Whistling

Submit

6
7
8
9
10
11
12
13
14
15
16
17
18
19
20
21
22
23
24
25
26
27
28
29
30
31
32
33
34
35
36

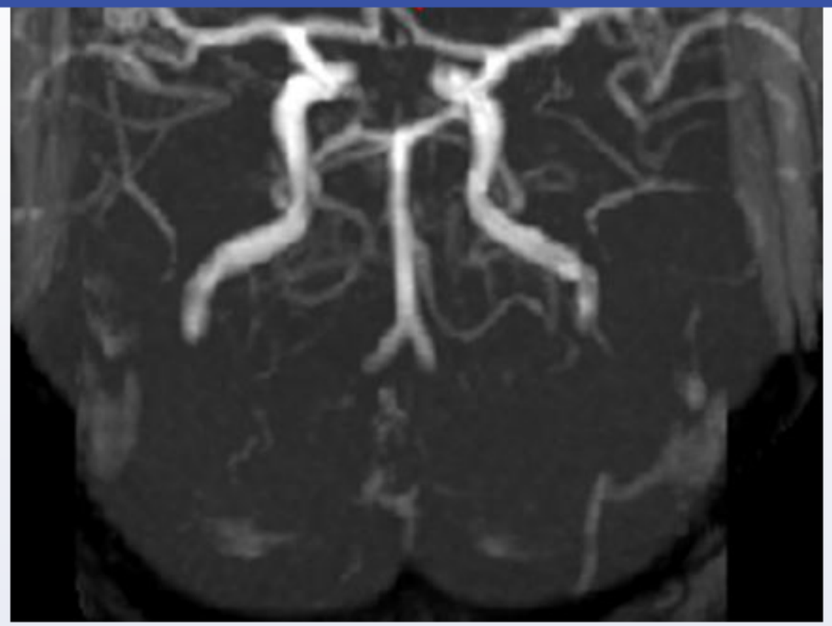

Which of the following actions is most likely to be impaired in this patient?

- ✓ A. Climbing stairs (76%)
- B. Gripping (5%)
- C. Speaking (11%)
- D. Swallowing food (3%)
- E. Whistling (3%)

Omitted
Correct answer

76%
Answered correctly

04 secs
Time Spent

05/27/2020
Last Updated

6
7
8
9
10
11
12
13
14
15
16
17
18
19
20
21
22
23
24
25
26
27
28
29
30
31
32
33
34
35
36

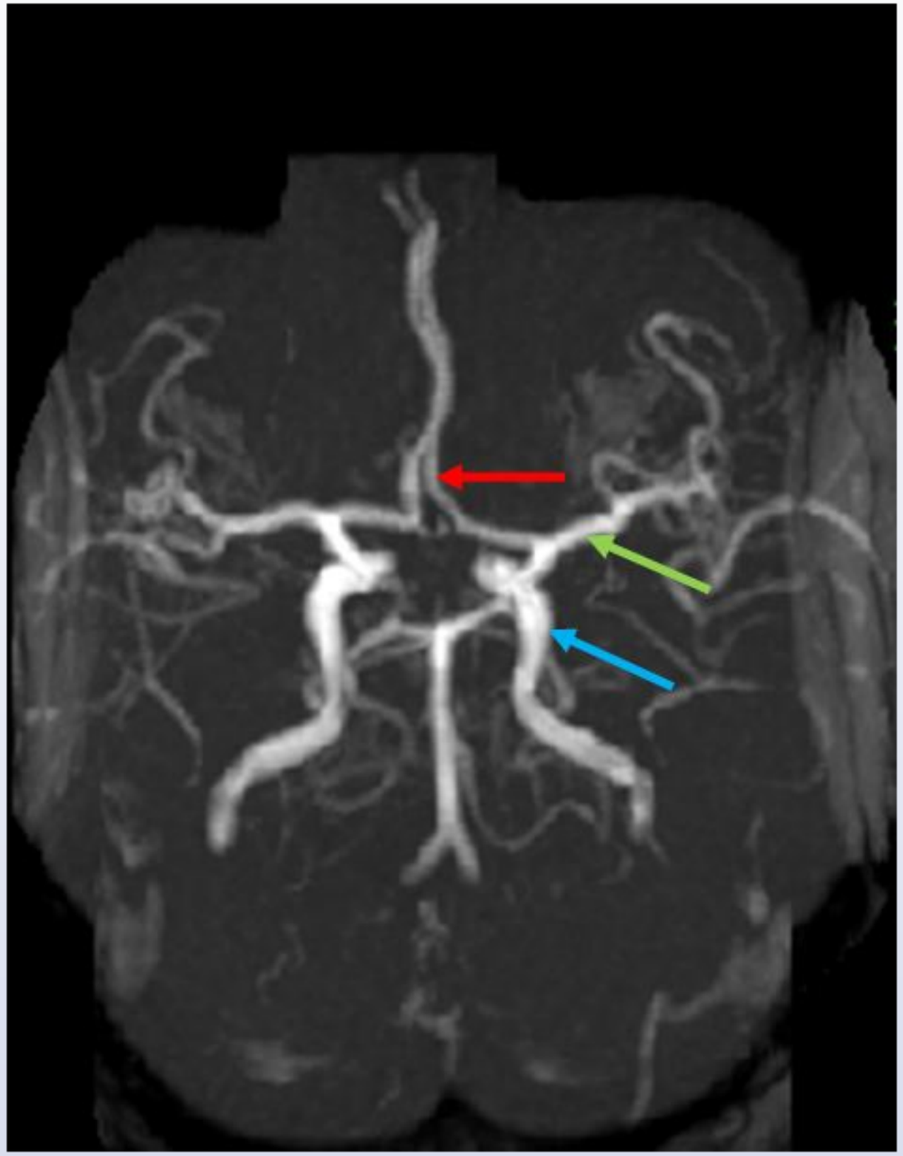

6
7
8
9
10
11
12
13
14
15
16
17
18
19
20
21
22
23
24
25
26
27
28
29
30
31
32
33
34
35
36

This cerebral magnetic resonance angiogram shows a 3D reconstruction of the circle of Willis, with the top representing superior regions and the bottom representing inferior regions. The internal carotid arteries are the large vessels seen bilaterally near the center of the image (blue arrow). Each gives off a middle cerebral artery (green arrow) to supply lateral brain regions and an **anterior cerebral artery** (red arrow), which extends medially and then superiorly. Each anterior cerebral artery supplies the medial region of the ipsilateral hemisphere, from the frontal pole to the parietooccipital sulcus.

Occlusion of the anterior cerebral artery would affect sensory and motor function of the **contralateral leg and foot** while predominantly sparing the contralateral arm/face (cortical homunculus). Patients with bilateral anterior cerebral artery occlusion can also develop significant **behavioral symptoms** (eg, abulia) and **urinary incontinence** if the frontal micturition center (eg, medial frontal lobe/cingulate gyrus) is affected.

(Choices B, C, D, and E) Occlusion of the middle cerebral artery would affect motor control of the hand (eg, gripping), face/mouth (eg, whistling), and throat (eg, swallowing) out of proportion to the leg. It can also result in Broca aphasia (due to damage of the dominant frontal lobe), anosognosia and spatial neglect of the contralateral side (due to damage of the nondominant parietal lobe), conjugate gaze deviation toward the side of the stroke, and contralateral homonymous hemianopsia (due to damage of the optic radiations in the subcortical temporoparietal lobe).

Educational objective:
The anterior cerebral arteries supply the medial portions of the 2 hemispheres (frontal and parietal lobes). Occlusion can cause contralateral motor and sensory deficits of the lower extremities, behavioral changes, and urinary incontinence.

References

- Anterior cerebral artery and Heubner's artery territory infarction.

Anatomy	Nervous System	Ischemic stroke
Subject	System	Topic

Copyright © UWorld. All rights reserved.

6
7
8
9
10
11
12
13
14
15
16
17
18
19
20
21
22
23
24
25
26
27
28
29
30
31
32
33
34
35
36

This cerebral magnetic resonance angiogram shows a 3D reconstruction of the circl
bottom representing inferior regions. The internal carotid arteries are the large vess
Each gives off a middle cerebral artery (green arrow) to supply lateral brain regions
medially and then superiorly. Each anterior cerebral artery supplies the medial regio
parietooccipital sulcus.

Occlusion of the anterior cerebral artery would affect sensory and motor function of
the contralateral arm/face (cortical homunculus). Patients with bilateral anterior cere
symptoms (eg, abulia) and **urinary incontinence** if the frontal micturition center (e

(Choices B, C, D, and E) Occlusion of the middle cerebral artery would affect moto
and throat (eg, swallowing) out of proportion to the leg. It can also result in Broca a
anosognosia and spatial neglect of the contralateral side (due to damage of the non
side of the stroke, and contralateral homonymous hemianopsia (due to damage of t

Educational objective:
The anterior cerebral arteries supply the medial portions of the 2 hemispheres (front
motor and sensory deficits of the lower extremities, behavioral changes, and urinary

References

- Anterior cerebral artery and Heubner's artery territory infarction.

Anatomy	Nervous System	Ischemic stroke
Subject	System	Topic

Copyright © UWorld. All rights rese

Exhibit Display

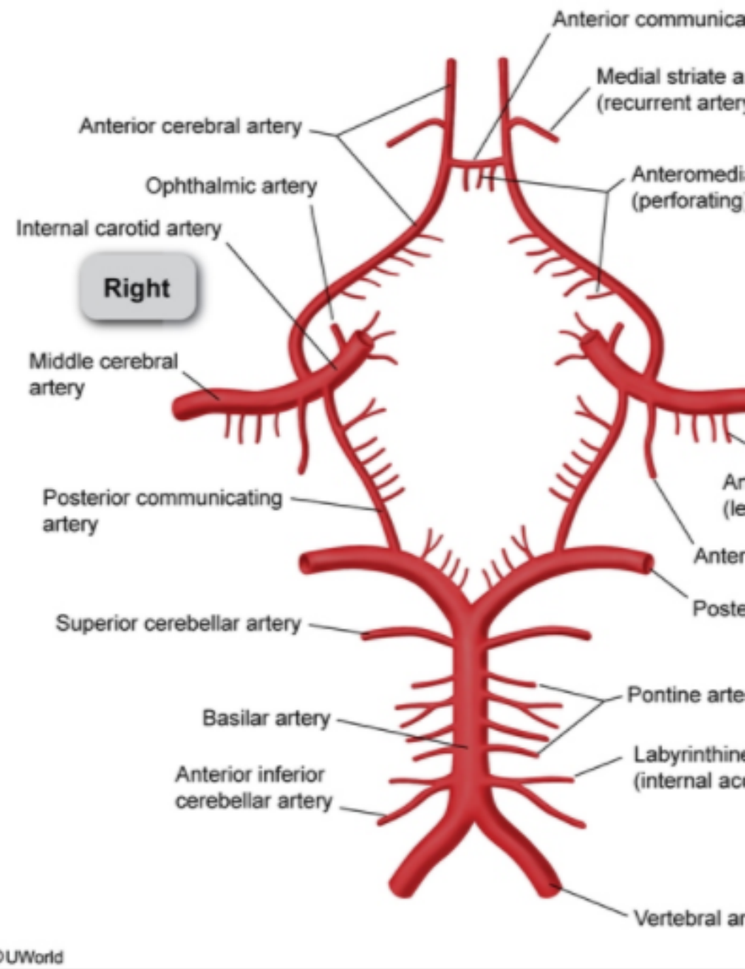

Zoom In
Zoom Out
Reset
Add To New

6
7
8
9
10
11
12
13
14
15
16
17
18
19
20
21
22
23
24
25
26
27
28
29
30
31
32
33
34
35
36

This cerebral magne
bottom representing
Each gives off a mid
medially and then s
parietooccipital sulc

Occlusion of the ant
the contralateral arm
symptoms (eg, abu

(Choices B, C, D, a
and throat (eg, swal
anosognosia and sp
side of the stroke, a

Educational object
The anterior cerebra
motor and sensory c

References

- Anterior cerebra

Anatomy
Subject

Ner
Syst

Exhibit Display

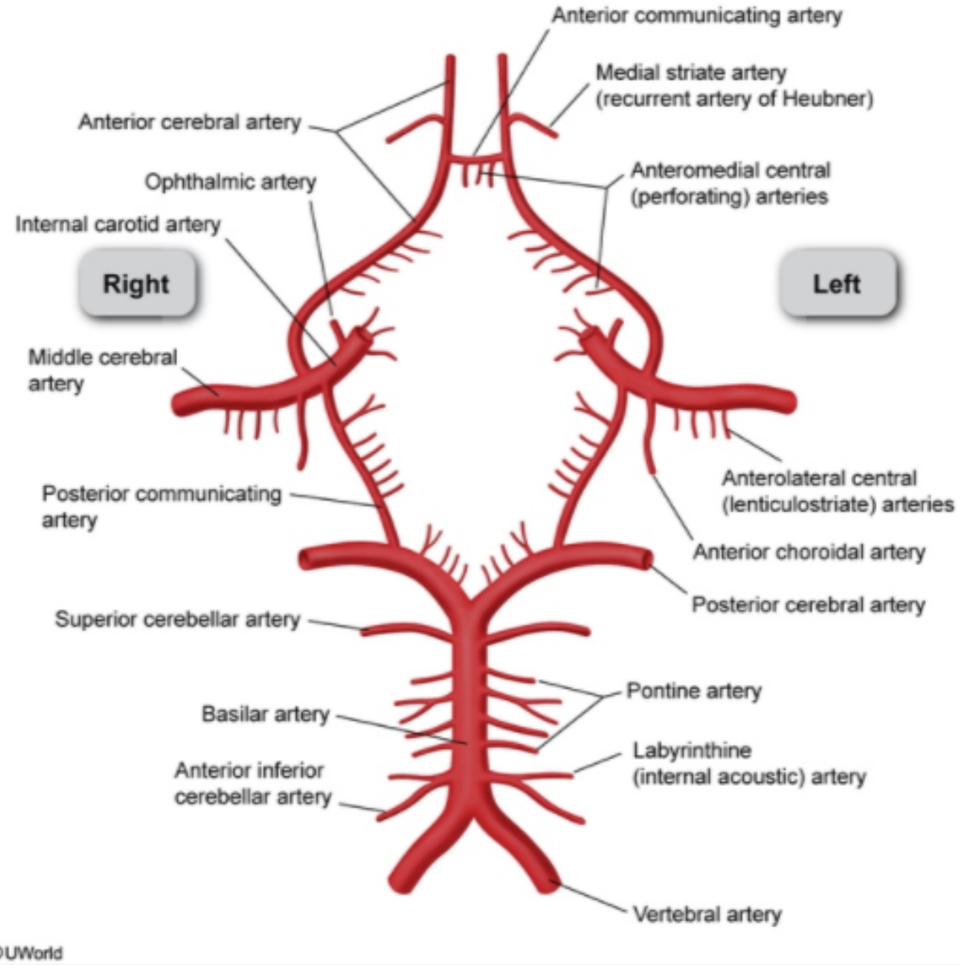

Zoom In
Zoom Out
Reset
Add To New Card | Existing Card

6
7
8
9
10
11
12
13
14
15
16
17
18
19
20
21
22
23
24
25
26
27
28
29
30
31
32
33
34
35
36

Exhibit Display

Blood supply to the cerebral hemispheres Cerebral hemisphere blood supply

Blood supply to the cerebral hemispheres

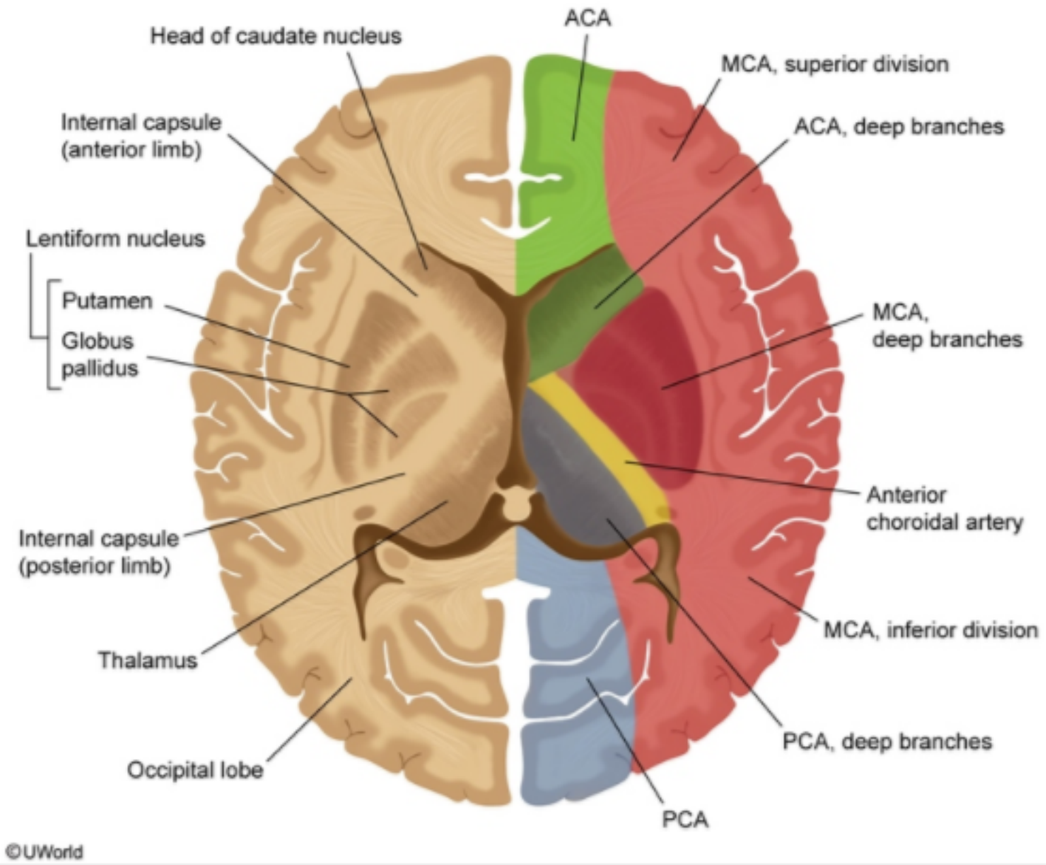

Zoom In Zoom Out Reset Add To New Card | Existing Card

6
7
8
9
10
11
12
13
14
15
16
17
18
19
20
21
22
23
24
25
26
27
28
29
30
31
32
33
34
35
36

Exhibit Display

Blood supply to the cerebral hemispheres Cerebral hemisphere blood supply

Blood supply to the Cerebral Hemispheres

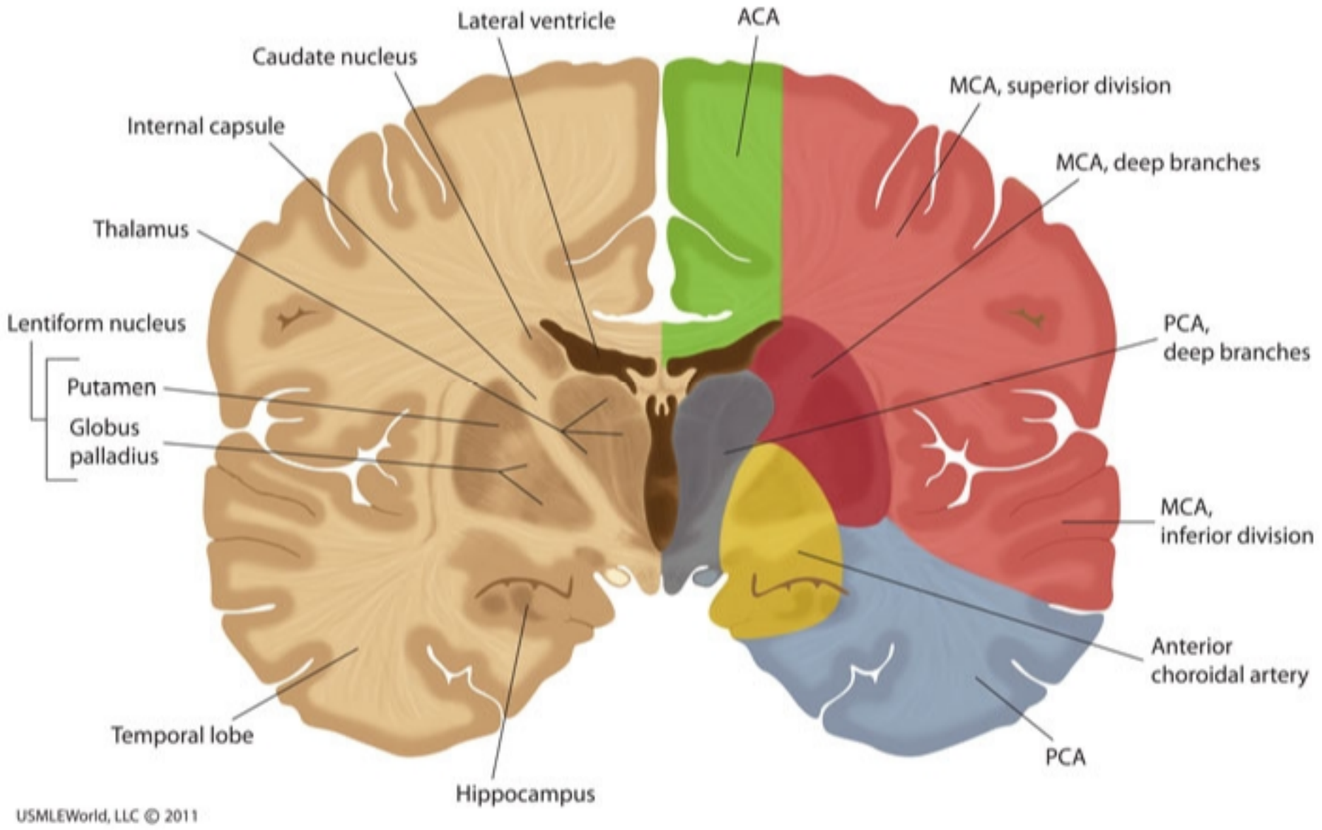

Zoom In Zoom Out Reset Add To New Card | Existing Card

Exhibit Display

Homunculus

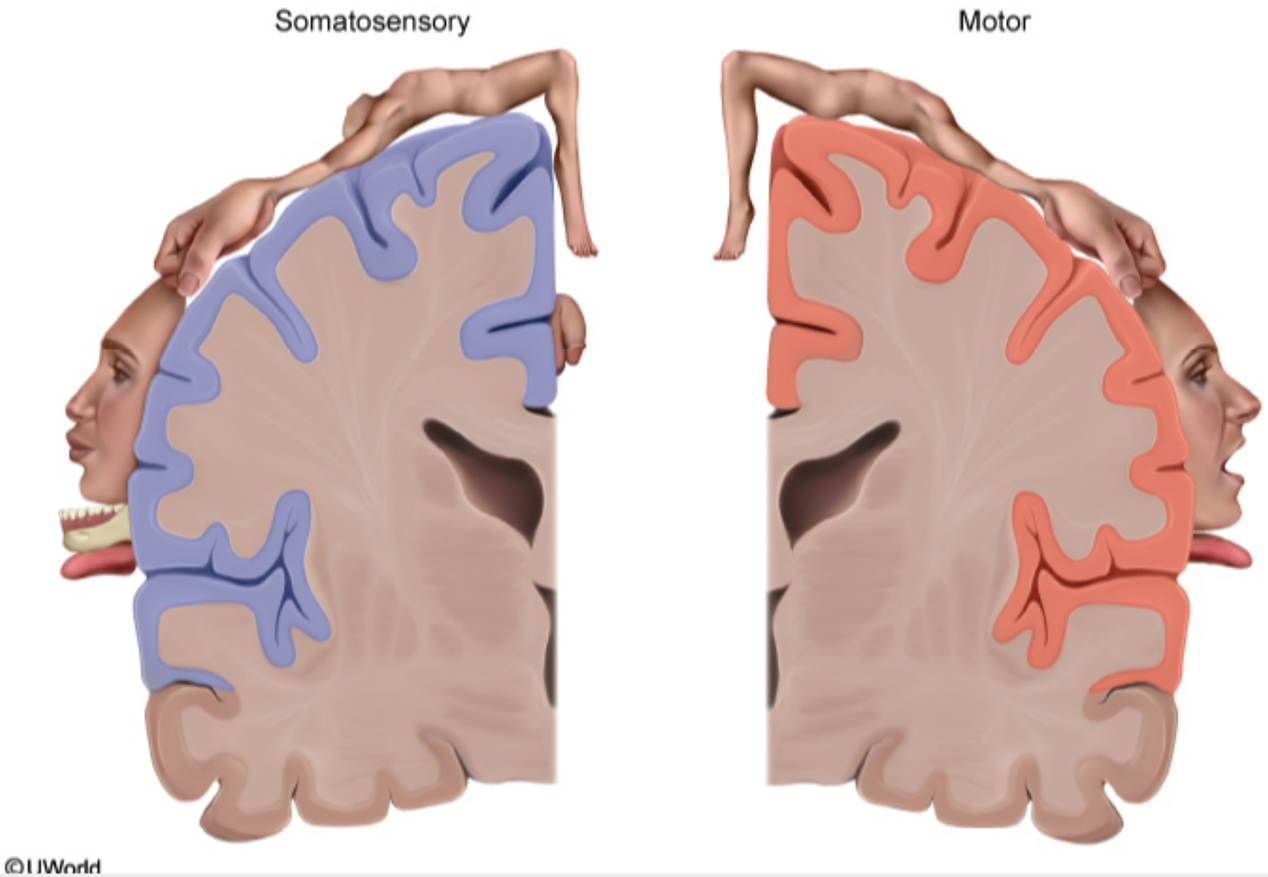

Zoom In | Zoom Out | Reset | Add To New Card | Existing Card

Exhibit Display

Homunculus

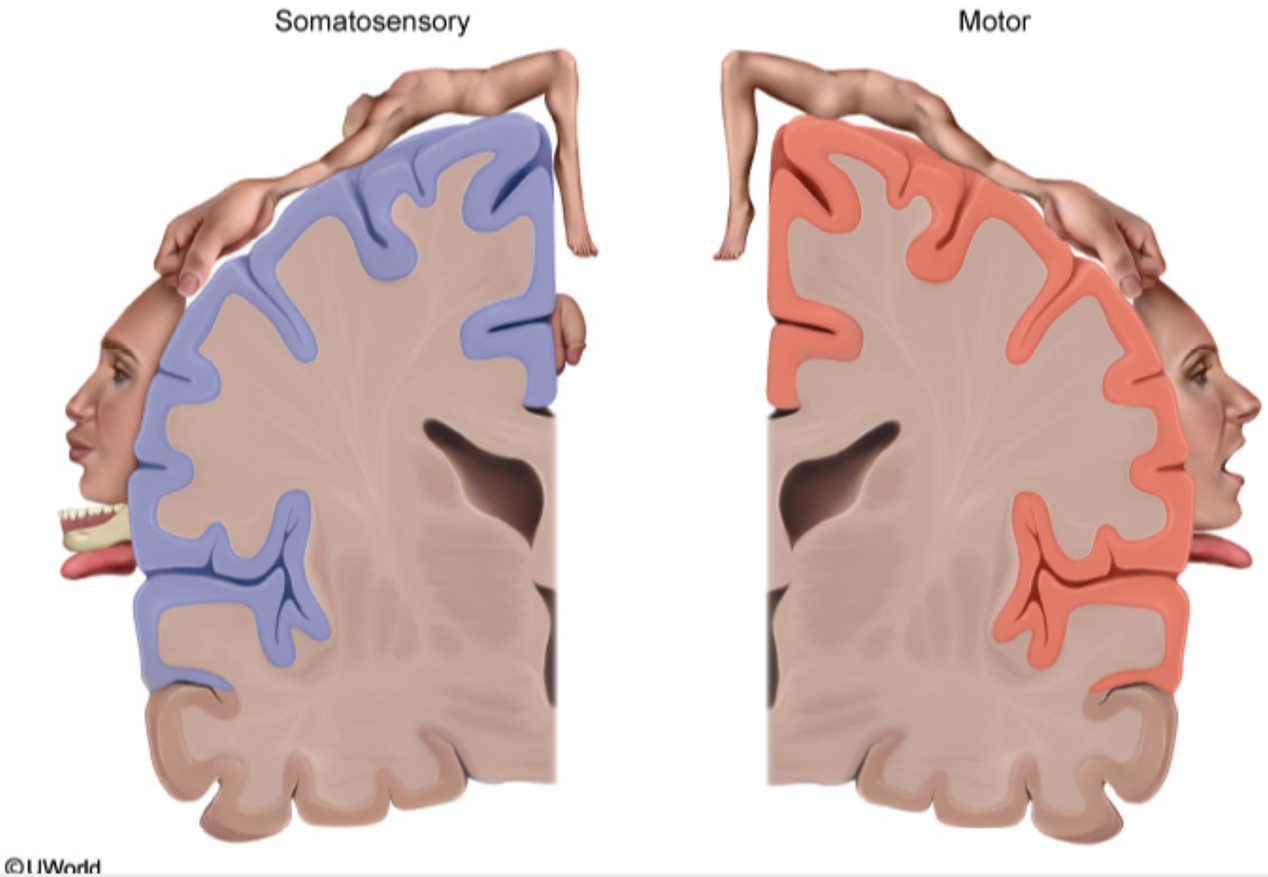

Zoom In | Zoom Out | Reset | Add To New Card | Existing Card

6
7
8
9
10
11
12
13
14
15
16
17
18
19
20
21
22
23
24
25
26
27
28
29
30
31
32
33
34
35
36

A 21-year old man is brought to the emergency department due to head trauma sustained during a boxing match. During the fight, he had a brief loss of consciousness after a hard hit to the right side of his face. He has a headache and muffled hearing in his right ear. On examination, the patient is alert and oriented. Palpation of the head does not reveal any step-offs. Cervical spine examination is normal. Otoscopic examination reveals hemotympanum in the right ear. This patient is at greatest risk for injury involving which of the following cranial nerves?

A. Olfactory nerve
B. Oculomotor nerve
C. Trigeminal nerve
D. Facial nerve
E. Hypoglossal nerve

Submit

A 21-year old man is brought to the emergency department due to head trauma sustained during a boxing match. During the fight, he had a brief loss of consciousness after a hard hit to the right side of his face. He has a headache and muffled hearing in his right ear. On examination, the patient is alert and oriented. Palpation of the head does not reveal any step-offs. Cervical spine examination is normal. Otoscopic examination reveals hemotympanum in the right ear. This patient is at greatest risk for injury involving which of the following cranial nerves?

- A. Olfactory nerve (0%)
- B. Oculomotor nerve (1%)
- C. Trigeminal nerve (14%)
- ✓ D. Facial nerve (82%)
- E. Hypoglossal nerve (1%)

Omitted
Correct answer
D

82%
Answered correctly

02 secs
Time Spent

05/27/2020
Last Updated

Explanation

Facial nerve course through the temporal bone

6
7
8
9
10
11
12
13
14
15
16
17
18
19
20
21
22
23
24
25
26
27
28
29
30
31
32
33
34
35
36

Facial nerve course through the temporal bone

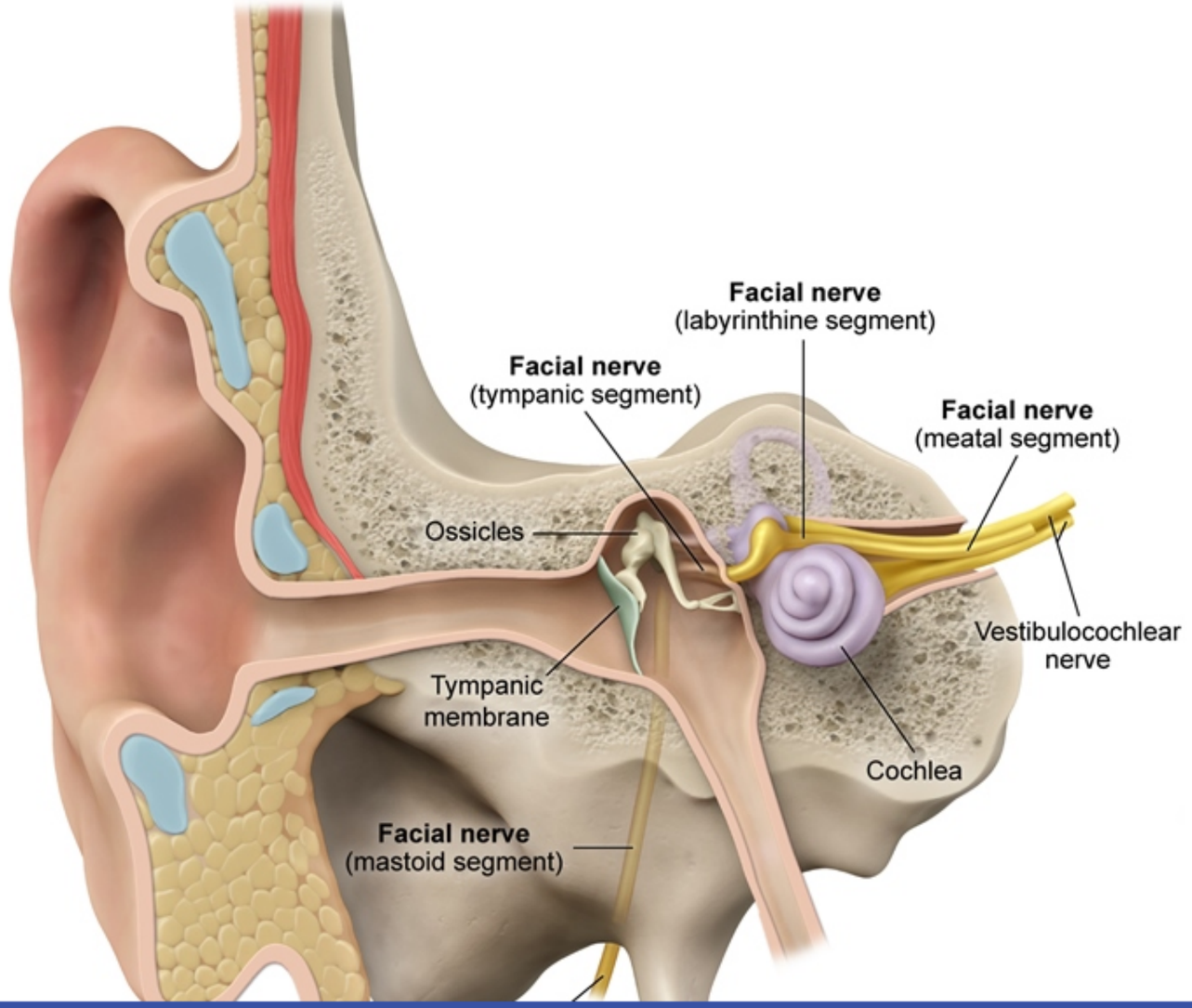

6
7
8
9
10
11
12
13
14
15
16
17
18
19
20
21
22
23
24
25
26
27
28
29
30
31
32
33
34
35
36

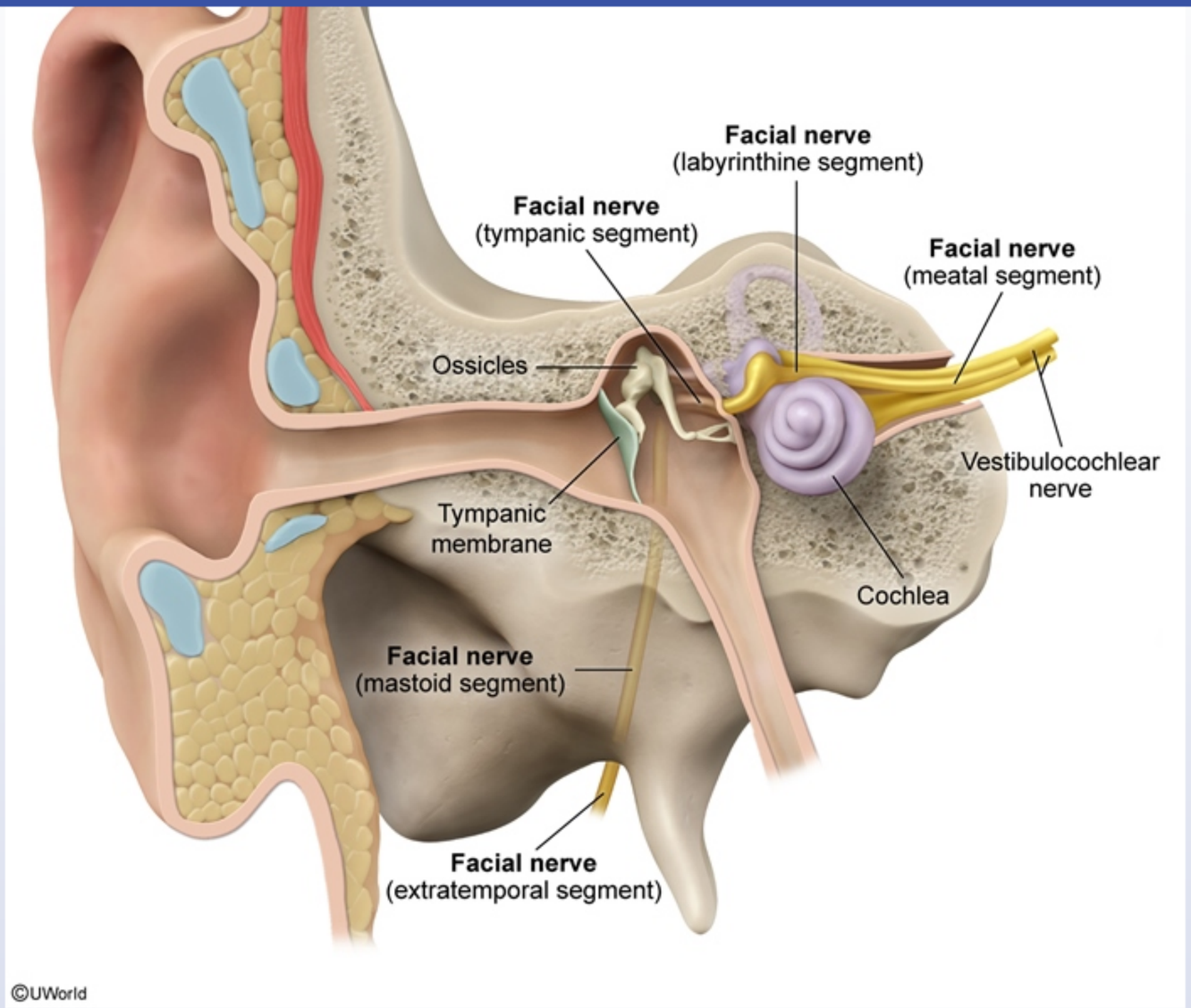

This patient who sustained trauma to the head now has hearing loss and **hemotympanum**, which is concerning for a **temporal bone fracture**.

Contained within the temporal bone are many structures involved in hearing, including the external auditory canal, tympanic membrane, ossicular

This patient who sustained trauma to the head now has hearing loss and **hemotympanum**, which is concerning for a **temporal bone fracture**. Contained within the temporal bone are many structures involved in hearing, including the external auditory canal, tympanic membrane, ossicular chain, cochlea, and vestibulocochlear nerve (CN VIII). Injury or disruption to any of these structures can cause **hearing loss**, as in this patient.

The temporal bone also contains the **facial nerve (CN VII)**, which originates in the brainstem and then enters the temporal bone at the internal auditory meatus. It **travels** through the internal auditory canal with the vestibulocochlear nerve (CN VIII) and then takes a complicated route **through the temporal bone** itself, traveling near the otic capsule, through the middle ear, and then through the mastoid portion to exit at the stylomastoid foramen.

Because of its location, the facial nerve is at risk of injury in temporal bone fractures. Deficits can be diverse and significant because the facial nerve has many functions, including:

- Movement of the face, including eye closure
- Taste from the anterior 2/3 of the tongue
- Parasympathetic innervation of submandibular and lacrimal glands
- Sound dampening (due to innervation of the stapedius muscle)

(Choice A) Axons of chemoreceptor cells make up the olfactory nerve (CN I) rootlets, which project through the cribriform plate of the ethmoid bone. Acceleration-deceleration head injuries can lead to avulsion of the olfactory nerve rootlets, but this would not be associated with hearing loss or hemotympanum.

(Choice B) The oculomotor nerve (CN III) exits the skull base from the superior orbital fissure and is at risk with trauma to the orbit or anterior face.

(Choice C) The trigeminal nerve (CN V) divides into V1, V2, and V3, which exit the skull base from the superior orbital fissure, foramen rotundum, and foramen ovale, respectively, which are all located in the sphenoid bone. These branches are at risk with trauma to the orbit or anterior face.

(Choice E) The hypoglossal nerve (CN XII) exits the skull base through the hypoglossal canal of the occipital bone. It could be injured by fractures involving the occipital bone, but it is more commonly injured due to penetrating neck trauma.

Educational objective:
In addition to much of the hearing apparatus (eg, ossicles, cochlea, vestibulocochlear nerve), the temporal bone also contains the facial nerve,

nerve has many functions, including:

- Movement of the face, including eye closure
- Taste from the anterior 2/3 of the tongue
- Parasympathetic innervation of submandibular and lacrimal glands
- Sound dampening (due to innervation of the stapedius muscle)

(Choice A) Axons of chemoreceptor cells make up the olfactory nerve (CN I) rootlets, which project through the cribriform plate of the ethmoid bone. Acceleration-deceleration head injuries can lead to avulsion of the olfactory nerve rootlets, but this would not be associated with hearing loss or hemotympanum.

(Choice B) The oculomotor nerve (CN III) exits the skull base from the superior orbital fissure and is at risk with trauma to the orbit or anterior face.

(Choice C) The trigeminal nerve (CN V) divides into V1, V2, and V3, which exit the skull base from the superior orbital fissure, foramen rotundum, and foramen ovale, respectively, which are all located in the sphenoid bone. These branches are at risk with trauma to the orbit or anterior face.

(Choice E) The hypoglossal nerve (CN XII) exits the skull base through the hypoglossal canal of the occipital bone. It could be injured by fractures involving the occipital bone, but it is more commonly injured due to penetrating neck trauma.

Educational objective:
In addition to much of the hearing apparatus (eg, ossicles, cochlea, vestibulocochlear nerve), the temporal bone also contains the facial nerve, which can be injured in temporal bone fractures.

References

- Facial Nerve Anatomy and Clinical Applications

Anatomy	Nervous System	Skull fractures
Subject	System	Topic

Copyright © UWorld. All rights reserved.

nerve has many functions, including:

Exhibit Display

Olfactory nerve rootlet avulsion with TBI

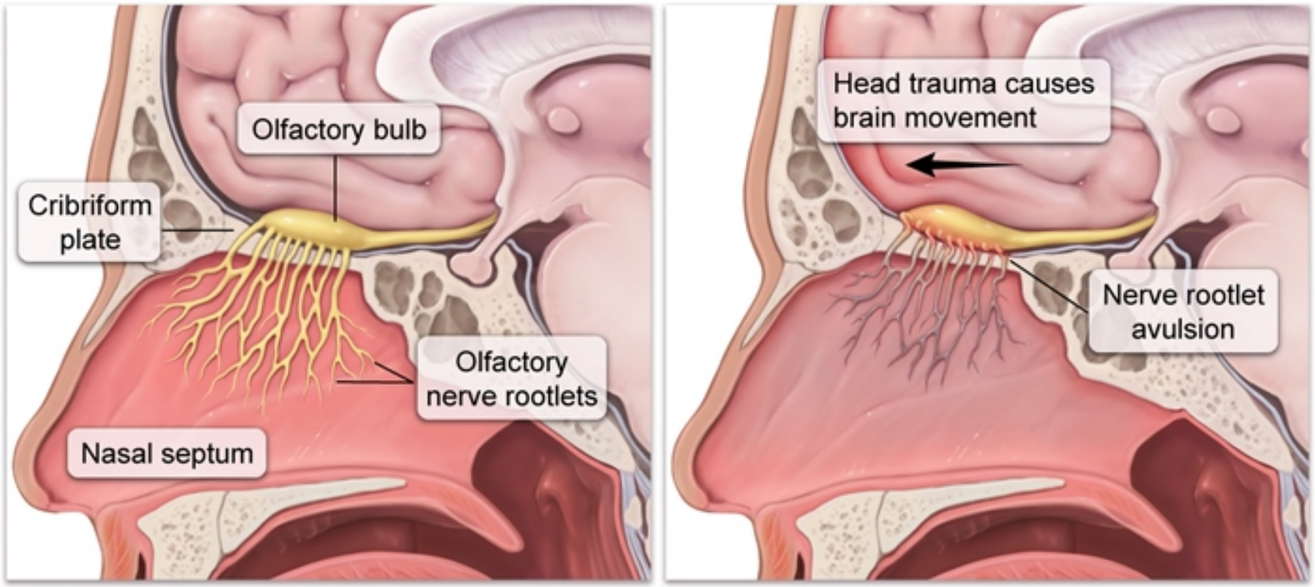

TBI = traumatic brain injury.

©UWorld

Zoom In Zoom Out Reset Add To Flash Card

nerve has many functions, including:

Exhibit Display

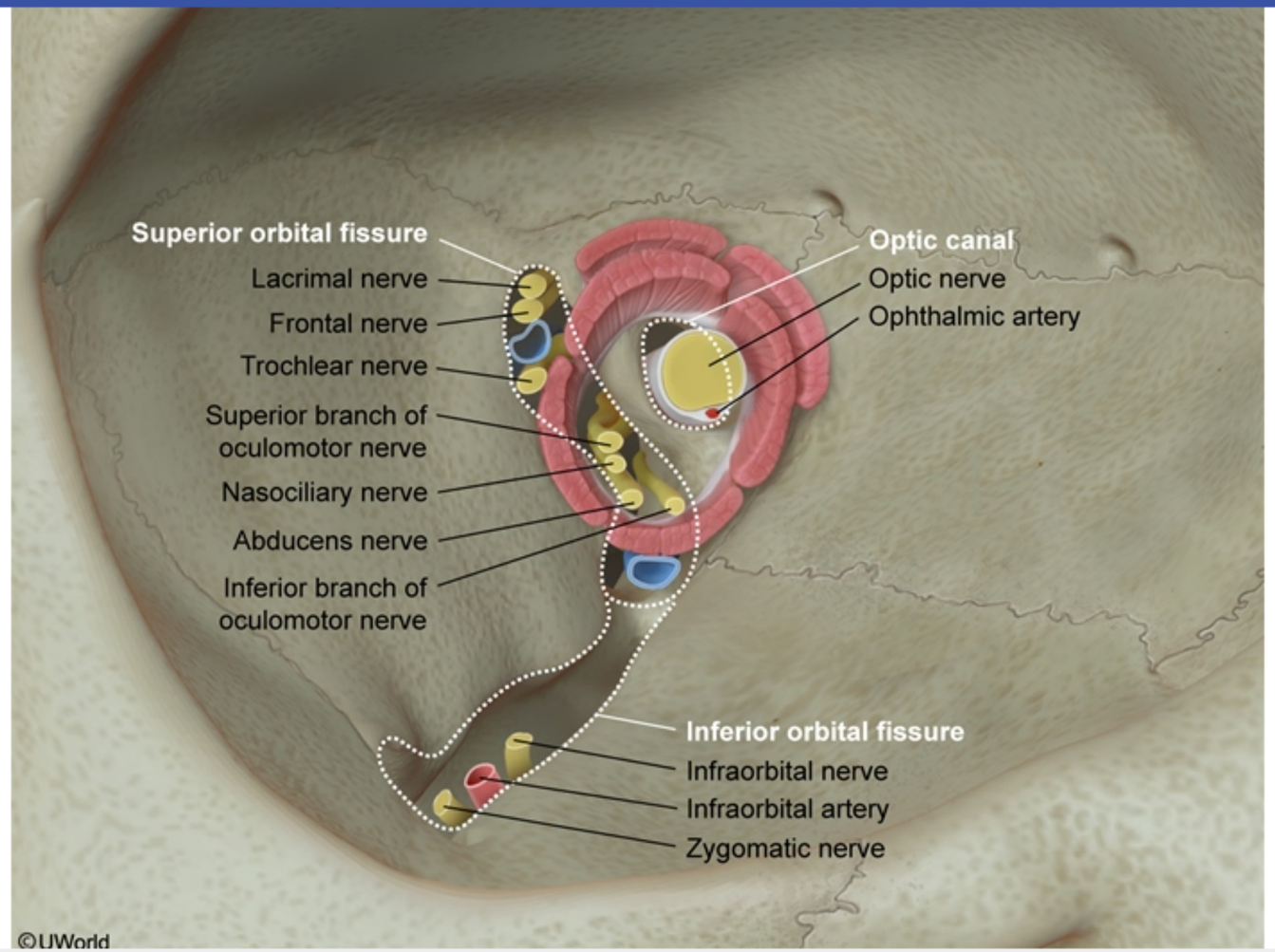

Zoom In Zoom Out Reset Add To Flash Card

nerve has many functions, including:

Exhibit Display

Mandibular division of trigeminal nerve

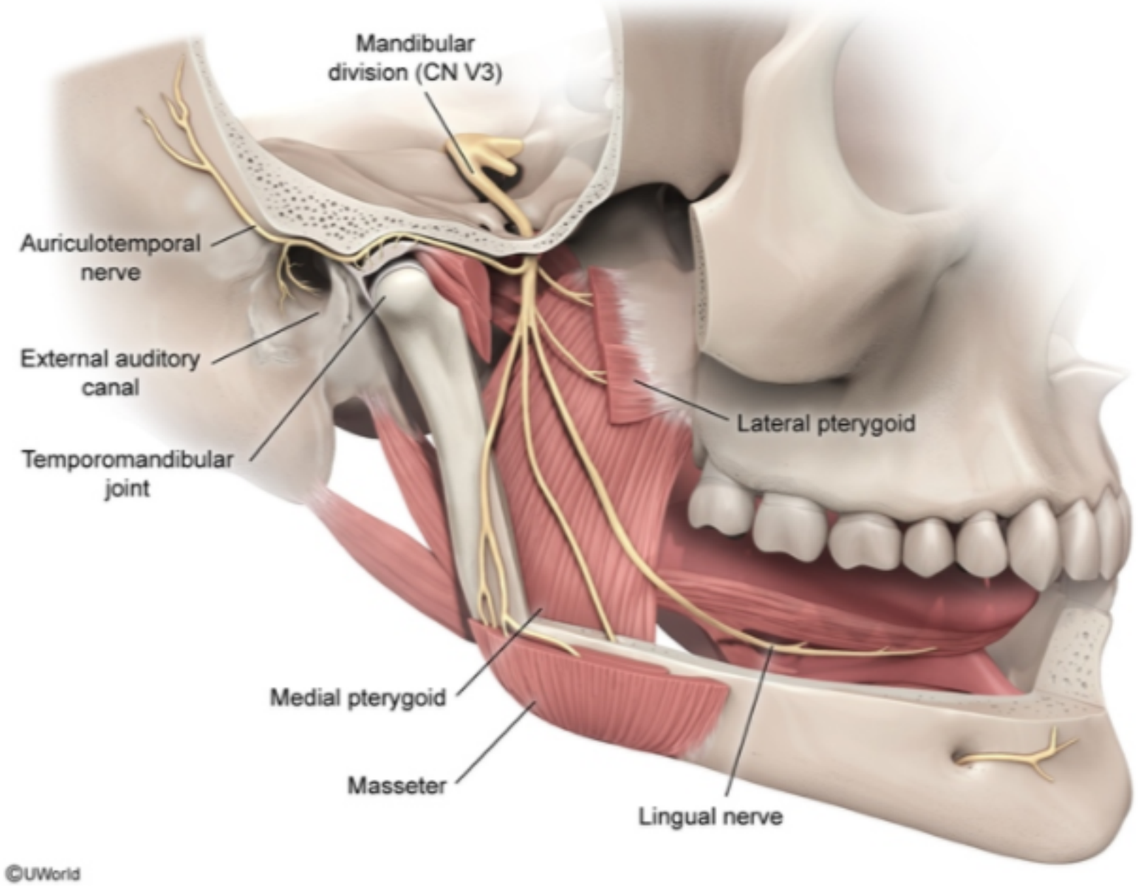

Zoom In Zoom Out Reset Add To Flash Card

A 55-year-old man is being evaluated for a 4-week history of right shoulder pain. The pain worsens when actively abducting the shoulder or when lying on the shoulder at night. The patient also has weakness with abduction and external rotation of the right shoulder. He has attempted treatment with over-the-counter analgesics with limited relief. MRI of the shoulder shows a partial rotator cuff tear, and the patient is scheduled for surgical repair. Immediately before the surgery, he receives anesthesia with an injection between the right anterior and middle scalene muscles in order to block the C3 through C7 nerve roots of the cervical and brachial plexuses. Which of the following muscles is most likely to be paralyzed due to the anesthesia?

A. Cricothyroid
B. Diaphragm
C. Intercostal
D. Platysma
E. Sternocleidomastoid

Submit

A 55-year-old man is being evaluated for a 4-week history of right shoulder pain. The pain worsens when actively abducting the shoulder or when lying on the shoulder at night. The patient also has weakness with abduction and external rotation of the right shoulder. He has attempted treatment with over-the-counter analgesics with limited relief. MRI of the shoulder shows a partial rotator cuff tear, and the patient is scheduled for surgical repair. Immediately before the surgery, he receives anesthesia with an injection between the right anterior and middle scalene muscles in order to block the C3 through C7 nerve roots of the cervical and brachial plexuses. Which of the following muscles is most likely to be paralyzed due to the anesthesia?

- A. Cricothyroid (2%)
- ✓ B. Diaphragm (69%)
- C. Intercostal (4%)
- D. Platysma (6%)
- E. Sternocleidomastoid (17%)

Omitted
Correct answer
B

69%
Answered correctly

06 secs
Time Spent

03/02/2020
Last Updated

Explanation

Course of phrenic nerve

Course of phrenic nerve

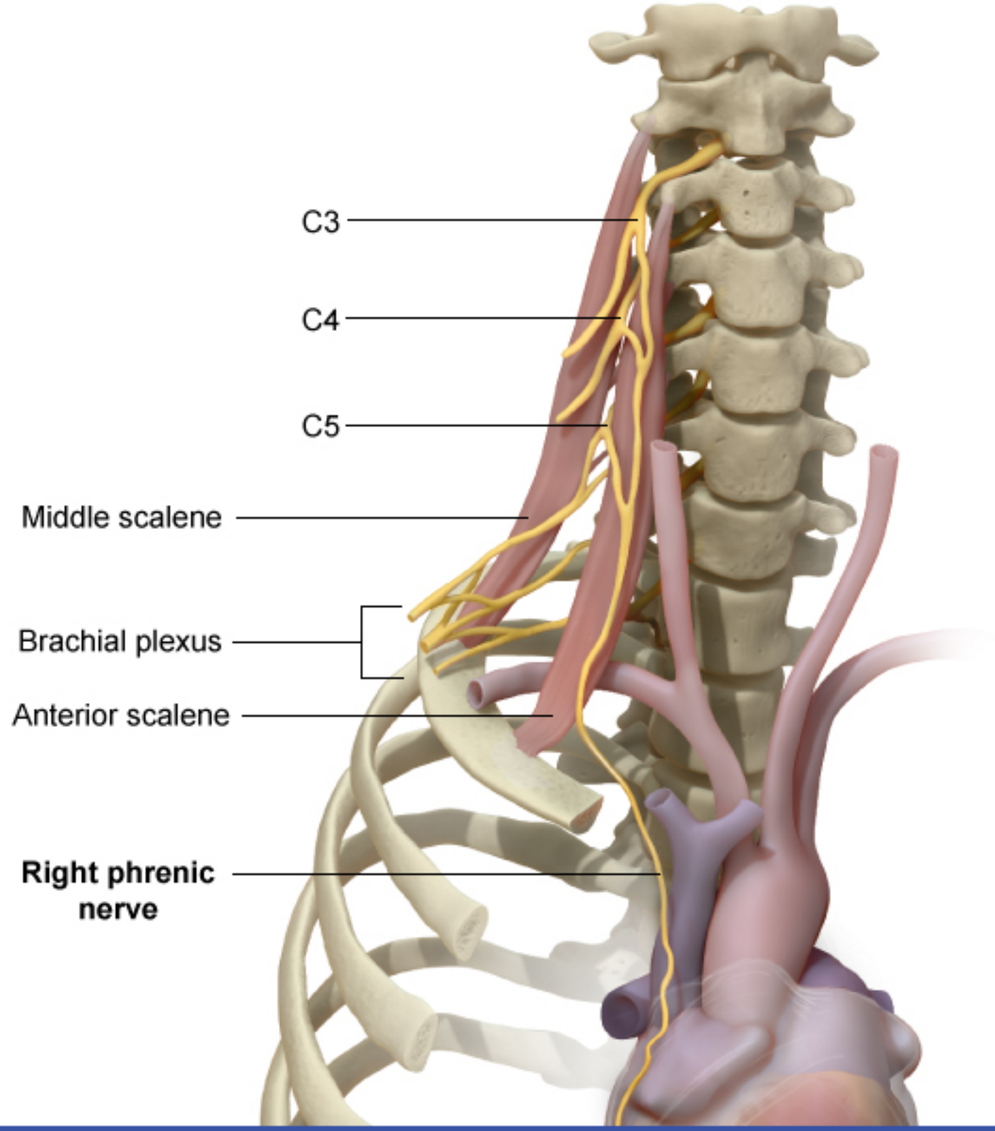

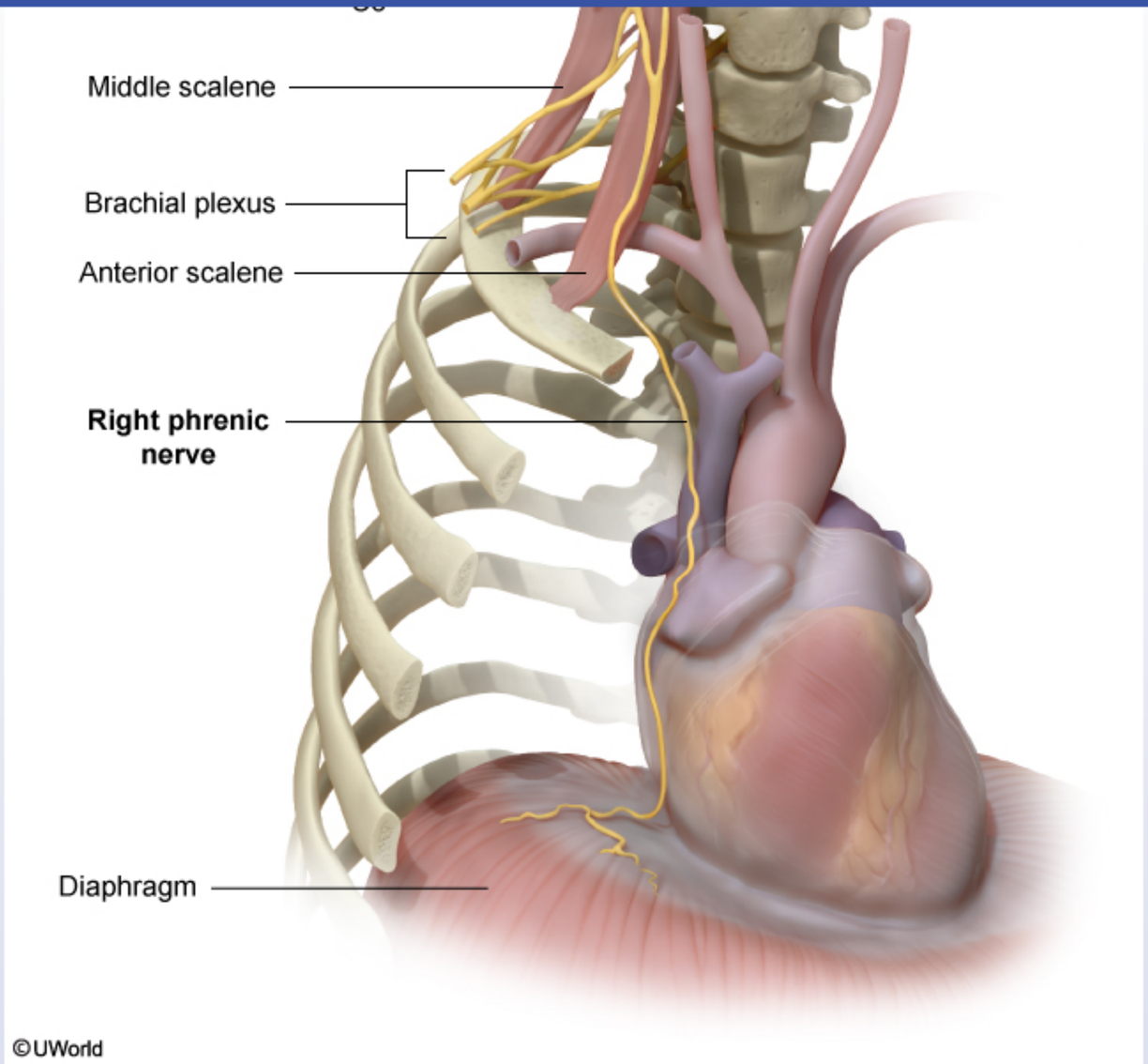

The brachial plexus originates from the C5-T1 spinal nerve roots, which combine into 3 trunks and pass between the **anterior and middle**

©UWorld

The brachial plexus originates from the C5-T1 spinal nerve roots, which combine into 3 trunks and pass between the **anterior and middle scalene muscles** (scalene triangle) in the posterior neck. The trunks then differentiate into divisions, cords, and terminal nerve branches. The brachial plexus supplies all sensory and motor innervation to the upper extremity, except for an area of skin near the axilla which is innervated by the intercostobrachial nerve and the trapezius muscle which is innervated by the accessory nerve (CN XI).

An **interscalene nerve block** is a regional anesthesia technique used for procedures involving the **shoulder and upper arm**. In this technique, anesthetic is administered to the brachial plexus roots and trunks between the anterior and middle scalene muscles. Anesthetic also traverses along the interscalene sheath and affects the roots of the **phrenic nerve (C3-C5)**, which causes transient **ipsilateral diaphragmatic paralysis**. Therefore, an interscalene nerve block should be avoided in patients with conditions that could be worsened by unilateral diaphragmatic paralysis (eg, chronic lung disease, contralateral phrenic nerve dysfunction).

(Choice A) The cricothyroid muscle is innervated by the external branch of the superior laryngeal nerve (vagus nerve [CN X]) and helps tense the vocal cords, allowing higher-pitched speech.

(Choice C) The intercostal muscles aid in expansion and contraction of the chest cavity during breathing. They are innervated by the intercostal nerves (ventral rami of thoracic spinal nerves).

(Choice D) The platysma is a superficial neck muscle that covers the anterior neck from the clavicle to the mandible and tenses the skin of the neck and lower face. It is innervated by the cervical branch of the facial nerve (CN VII).

(Choice E) The sternocleidomastoid, a superficial neck muscle controlling neck flexion and head rotation, is innervated by the accessory nerve (CN XI).

Educational objective:
An interscalene nerve block is used to provide anesthesia for the shoulder and upper arm by anesthetizing the upper brachial plexus (C5-C7) as it passes between the anterior and middle scalene muscles. Anesthetic also transverses along the interscalene sheath, frequently resulting in transient ipsilateral diaphragmatic paralysis due to involvement of the phrenic nerve roots (C3-C5).

References

- Sudden severe postoperative dyspnea following shoulder surgery: remember inadvertent phrenic nerve block due to interscalene brachial

A 4-year-old boy is brought to the office due to headaches that have worsened progressively over the past month and are most severe when lying down. He also has had nonbloody, nonbilious emesis for 2 weeks that typically occurs early in the morning. In addition, the child has intermittent blurry vision, particularly when looking up at the mirror while brushing his teeth. Physical examination shows bilateral papilledema, inability to gaze upwards, and bilateral eyelid retraction. Laboratory testing of sodium, growth hormone, luteinizing hormone (LH), and follicle-stimulating hormone (FSH) is normal. Given the early morning emesis and papilledema, a brain mass is suspected and a brain MRI is ordered. Which of the following is the most likely location of the brain lesion in this patient?

- A. A
- B. B
- C. C
- D. D
- E. E
- F. F

Submit

A 4-year-old boy is brought to the office due to headaches that have worsened progressively over the past month and are most severe when lying down. He also has had nonbloody, nonbilious emesis for 2 weeks that typically occurs early in the morning. In addition, the child has intermittent blurry vision, particularly when looking up at the mirror while brushing his teeth. Physical examination shows bilateral papilledema, inability to gaze upwards, and bilateral eyelid retraction. Laboratory testing of sodium, growth hormone, luteinizing hormone (LH), and follicle-stimulating hormone (FSH) is normal. Given the early morning emesis and papilledema, a brain mass is suspected and a brain MRI is ordered. Which of the following is the most likely location of the brain lesion in this patient?

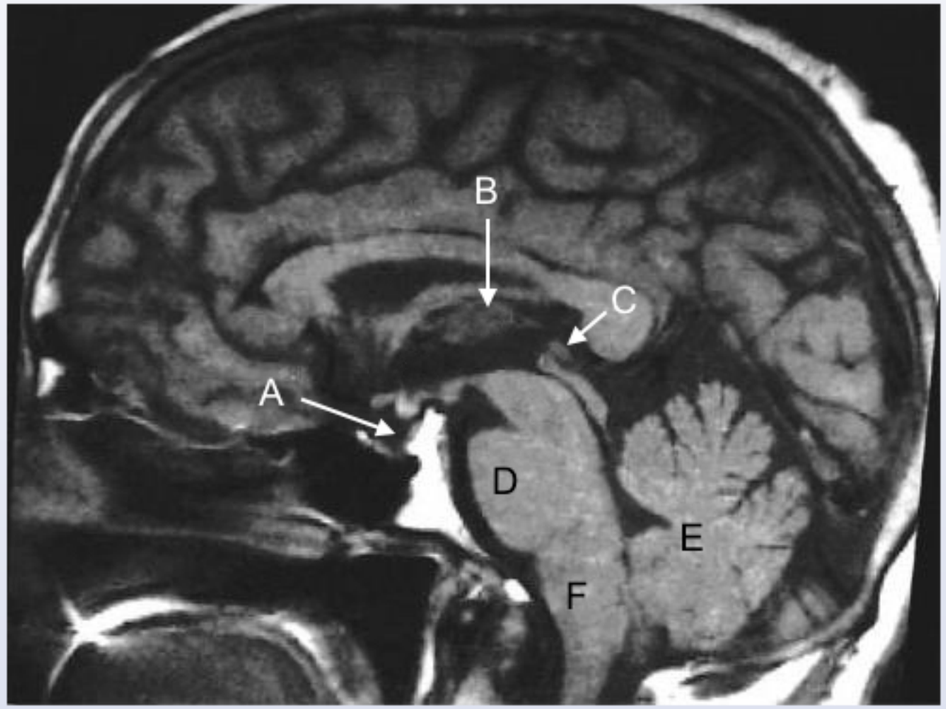

A. A

B. B

C. C

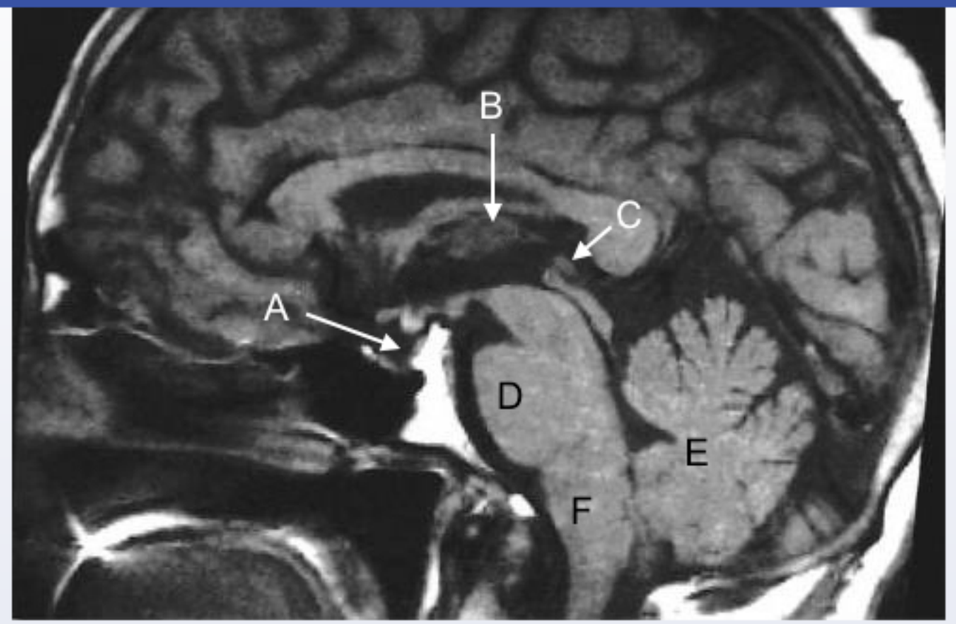

A. A
B. B
C. C
D. D
E. E
F. F

Submit

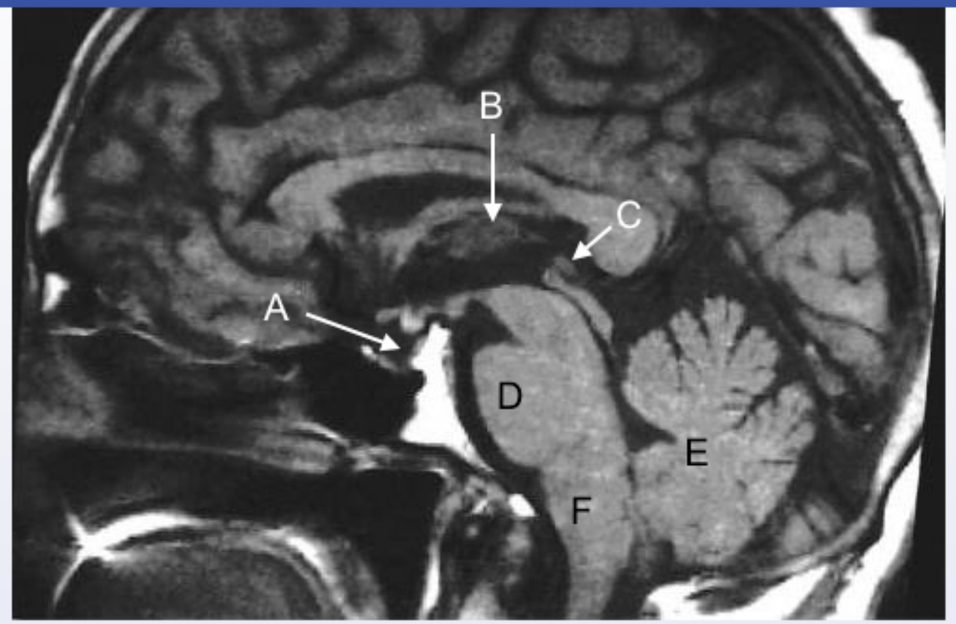

A. A (20%)

B. B (7%)

✓ C. C (41%)

D. D (10%)

E. E (9%)

F. F (11%)

Omitted
Correct answer

41%
Answered correctly

07 secs
Time Spent

03/08/2020
Last Updated

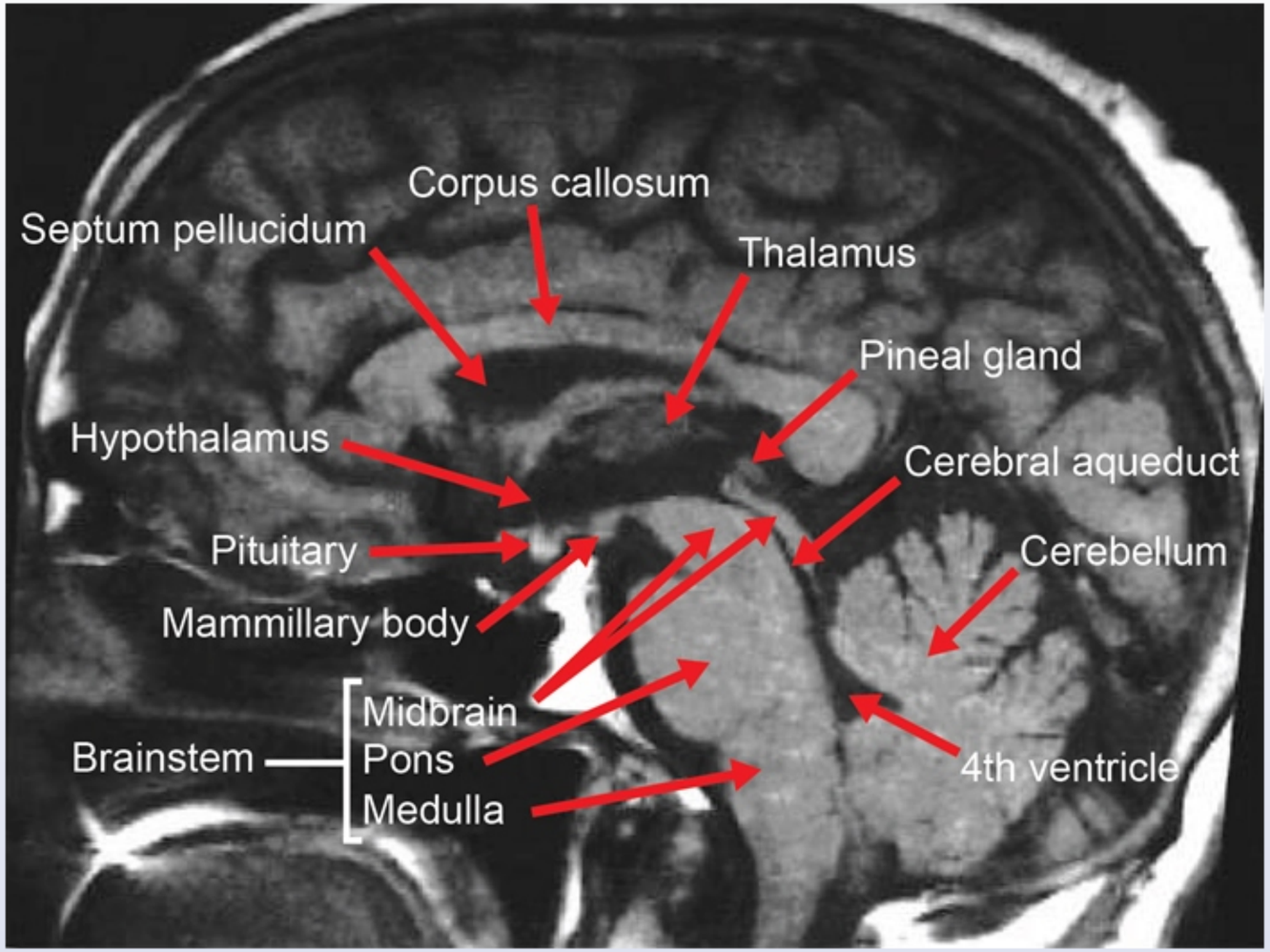

This patient has a **pineal gland mass**. Classic manifestations of a pineal gland mass include **obstructive hydrocephalus** from aqueductal stenosis (papilledema, headache, and vomiting) and **dorsal midbrain (Parinaud) syndrome** due to direct compression of the pretectal region of the midbrain. Parinaud syndrome is characterized by limitation of upward gaze with a downward gaze preference, bilateral eyelid retraction (eg, Collier sign, sclera visible above the superior corneal limbus), and light-near dissociation (eg, pupils that react to accommodation but not to light)

This patient has a **pineal gland mass**. Classic manifestations of a pineal gland mass include **obstructive hydrocephalus** from aqueductal stenosis (papilledema, headache, and vomiting) and **dorsal midbrain (Parinaud) syndrome** due to direct compression of the pretectal region of the midbrain. Parinaud syndrome is characterized by limitation of upward gaze with a downward gaze preference, bilateral eyelid retraction (eg, Collier sign, sclera visible above the superior corneal limbus), and light-near dissociation (eg, pupils that react to accommodation but not to light). Diagnosis of pineal gland mass is made by brain MRI.

The most common pineal mass is a **germinoma**, a **midline** malignant tumor thought to arise from embryonic germ cells. A germinoma can also arise in the gonads or mediastinum and is more common in young boys. The most common locations for intracranial germinomas are the pineal gland and the suprasellar region (less common site) **(Choice A)**. Due to their proximity to the pituitary gland and hypothalamus, suprasellar germinomas do not lead to Parinaud syndrome, but they are more likely to present with endocrinopathies (eg, central precocious puberty, diabetes insipidus).

(Choice B) Primary thalamic tumors are rare. Damage to the thalamus from a mass or more commonly infarction/hemorrhage presents with contralateral hemisensory loss, behavioral changes, and language deficits.

(Choice D) Pontine hemorrhage or tumor may cause "locked-in" syndrome, which is characterized by spastic quadriplegia and paralysis of most cranial nerves (CNs) with preserved consciousness and eye movements.

(Choice E) The most common cerebellar tumor in children is medulloblastoma, which typically presents with gait and limb ataxia, intention tremor, and nystagmus.

(Choice F) Lesions of the medulla can cause lateral and medial medullary syndromes. Lateral medullary (Wallenberg) syndrome leads to contralateral loss of pain and temperature sensations along with ipsilateral paralysis of CNs V, IX, X, and XI. Medial medullary syndrome causes contralateral spastic paralysis, contralateral sensory loss of vibration and proprioception, and ipsilateral flaccid paralysis of the tongue (CN XII).

Educational objective:
Germinomas are the most common pineal gland tumor and present with obstructive hydrocephalus and dorsal midbrain (Parinaud) syndrome. Germinomas in the suprasellar region cause endocrinopathies due to pituitary/hypothalamic dysfunction.

References

- Pineal germinoma.

gland and the suprasellar region (less common site) **(Choice A)**. Due to their proximity to the pituitary gland and hypothalamus, suprasellar germinomas do not lead to Parinaud syndrome, but they are more likely to present with endocrinopathies (eg, central precocious puberty, diabetes insipidus).

(Choice B) Primary thalamic tumors are rare. Damage to the thalamus from a mass or more commonly infarction/hemorrhage presents with contralateral hemisensory loss, behavioral changes, and language deficits.

(Choice D) Pontine hemorrhage or tumor may cause "locked-in" syndrome, which is characterized by spastic quadriplegia and paralysis of most cranial nerves (CNs) with preserved consciousness and eye movements.

(Choice E) The most common cerebellar tumor in children is medulloblastoma, which typically presents with gait and limb ataxia, intention tremor, and nystagmus.

(Choice F) Lesions of the medulla can cause lateral and medial medullary syndromes. Lateral medullary (Wallenberg) syndrome leads to contralateral loss of pain and temperature sensations along with ipsilateral paralysis of CNs V, IX, X, and XI. Medial medullary syndrome causes contralateral spastic paralysis, contralateral sensory loss of vibration and proprioception, and ipsilateral flaccid paralysis of the tongue (CN XII).

Educational objective:
Germinomas are the most common pineal gland tumor and present with obstructive hydrocephalus and dorsal midbrain (Parinaud) syndrome. Germinomas in the suprasellar region cause endocrinopathies due to pituitary/hypothalamic dysfunction.

References

- Pineal germinoma.
- Pineal region tumors in children.
- Primary brain tumors in adults.

Anatomy	Nervous System	Brain tumors
Subject	System	Topic

Copyright © UWorld. All rights reserved.

A 12-year-old boy is brought to the emergency department by his mother due to right hand clumsiness. Several hours ago he attempted to climb a tree with a friend but lost his balance and fell from a branch. The boy tried to break the fall by grabbing the tree branch with his right hand. He landed safely on his feet with no head injury or loss of consciousness. On physical examination, he has difficulty performing fine finger movements with the right hand. Which of the following structures is most likely injured in this patient?

- A. Axillary nerve
- B. Long thoracic nerve
- C. Lower trunk of the brachial plexus
- D. Musculocutaneous nerve
- E. Radial nerve
- F. Suprascapular nerve

Submit

A 12-year-old boy is brought to the emergency department by his mother due to right hand clumsiness. Several hours ago he attempted to climb a tree with a friend but lost his balance and fell from a branch. The boy tried to break the fall by grabbing the tree branch with his right hand. He landed safely on his feet with no head injury or loss of consciousness. On physical examination, he has difficulty performing fine finger movements with the right hand. Which of the following structures is most likely injured in this patient?

- A. Axillary nerve (4%)
- B. Long thoracic nerve (1%)
- ✓ C. Lower trunk of the brachial plexus (75%)
- D. Musculocutaneous nerve (4%)
- E. Radial nerve (14%)
- F. Suprascapular nerve (0%)

Omitted
Correct answer
C

75%
Answered correctly

02 secs
Time Spent

05/31/2020
Last Updated

Explanation

Brachial plexus

Dorsal scapular nerve

To subclavius muscle

Brachial plexus

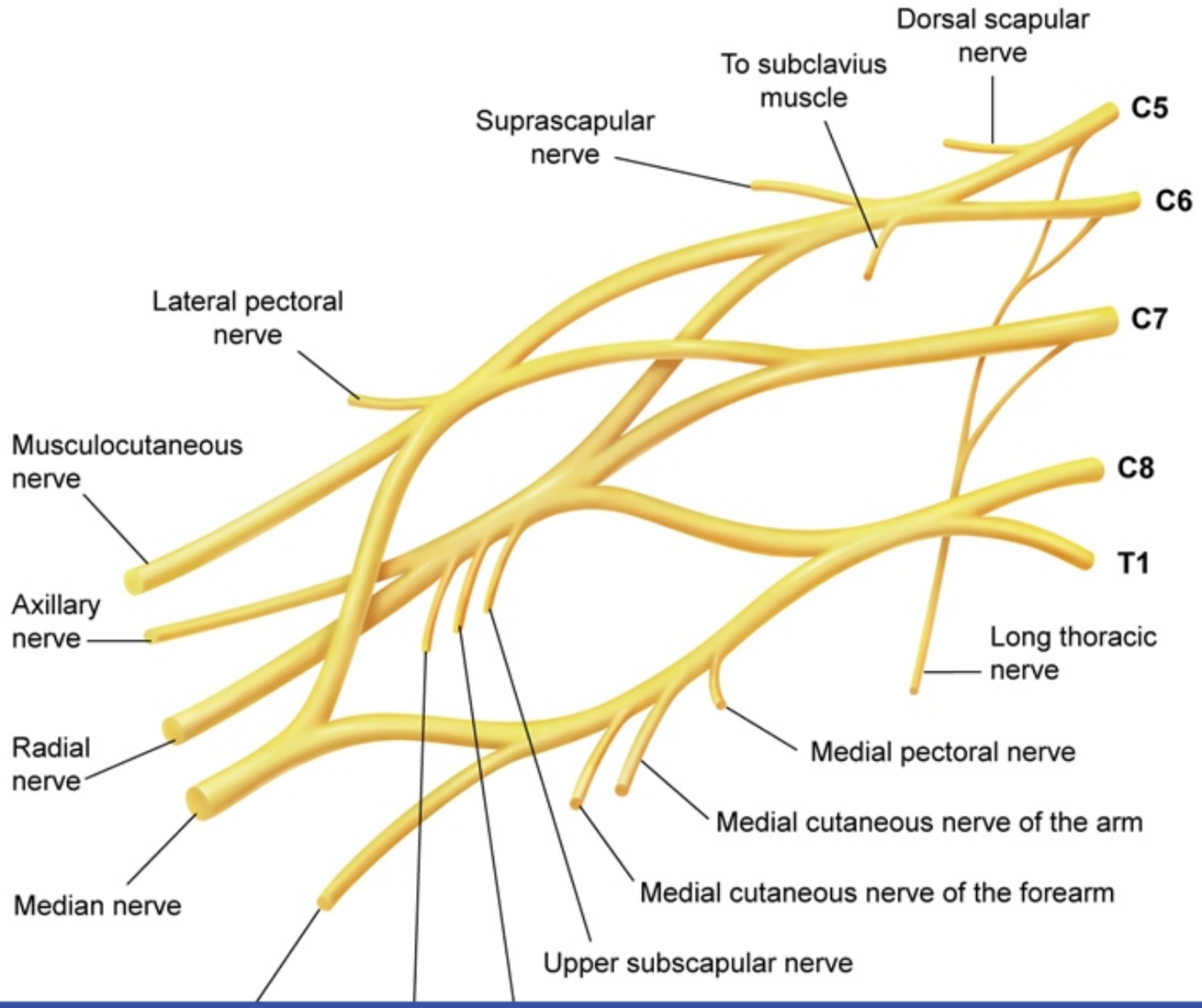

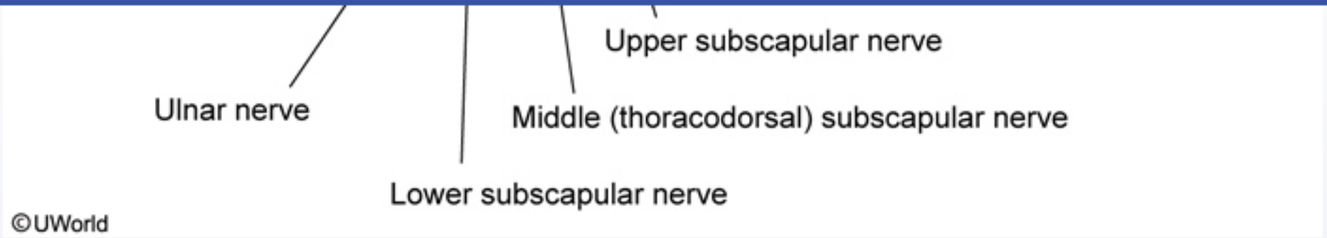

Sudden upward jerking of the arm at the shoulder can cause injury to the **lower trunk** of the brachial plexus. The lower trunk carries nerve fibers from the C8 and T1 spinal levels that ultimately contribute to the median and ulnar nerves. Together, these nerves innervate all of the intrinsic muscles of the hand (eg, lumbricals, interossei, thenar, hypothenar).

Injury to the lower trunk of the brachial plexus may cause paralysis of all the **intrinsic hand muscles (Klumpke's palsy)**. Weakness of lumbricals causes impaired flexion of the metacarpophalangeal joints and impaired extension of the interphalangeal joints. Relative sparing of the extrinsic flexors and extensors of the hand contributes to the **total claw hand deformity** seen in this condition. Sensory loss can also occur over the medial aspect of the hand/forearm. Involvement of the T1 nerve root proximal to the sympathetic trunk may cause concomitant Horner's syndrome (eg, ipsilateral ptosis, miosis, anhidrosis).

(Choice A) Shoulder dislocations or fractures of the proximal humerus can cause axillary nerve injury, which results in weakness of the deltoid and teres minor muscles.

(Choice B) Long thoracic nerve injury classically occurs during axillary lymph node dissection and results in paralysis of the serratus anterior muscle, leading to winging of the scapula.

(Choice D) Injury to the musculocutaneous nerve causes weakened elbow flexion because the nerve innervates the biceps brachii and brachialis muscles.

(Choice E) Fractures at the midshaft of the humerus commonly cause radial nerve injury. Patients may experience posterior forearm and dorsolateral hand numbness with paralysis of the wrist and finger extensors (wrist drop).

(Choice F) The suprascapular nerve innervates the supraspinatus and infraspinatus muscles. Nerve injury may result in problems with abduction and lateral rotation of the arm, respectively.

Educational objective:

flexors and extensors of the hand contributes to the **total claw hand deformity** seen in this condition. Sensory loss can also occur over the medial aspect of the hand/forearm. Involvement of the T1 nerve root proximal to the sympathetic trunk may cause concomitant Horner's syndrome (eg, ipsilateral ptosis, miosis, anhidrosis).

(Choice A) Shoulder dislocations or fractures of the proximal humerus can cause axillary nerve injury, which results in weakness of the deltoid and teres minor muscles.

(Choice B) Long thoracic nerve injury classically occurs during axillary lymph node dissection and results in paralysis of the serratus anterior muscle, leading to winging of the scapula.

(Choice D) Injury to the musculocutaneous nerve causes weakened elbow flexion because the nerve innervates the biceps brachii and brachialis muscles.

(Choice E) Fractures at the midshaft of the humerus commonly cause radial nerve injury. Patients may experience posterior forearm and dorsolateral hand numbness with paralysis of the wrist and finger extensors (wrist drop).

(Choice F) The suprascapular nerve innervates the supraspinatus and infraspinatus muscles. Nerve injury may result in problems with abduction and lateral rotation of the arm, respectively.

Educational objective:
The lower trunk of the brachial plexus carries nerve fibers from the C8 and T1 spinal levels that are responsible for innervating all of the intrinsic muscles of the hand (via the median and ulnar nerves). Sudden upward stretching on the arm at the shoulder can damage the lower trunk, resulting in finger clumsiness with total claw hand deformity.

References

- Brachial plexopathy: a review of traumatic and nontraumatic causes.

Anatomy	Nervous System	Brachial plexus
Subject	System	Topic

Copyright © UWorld. All rights reserved.

A 46-year-old man experiences burning pain in his left thigh and leg. The next day, he notices groups of erythematous, tender, fluid-filled vesicles in the painful region. The lesions gradually crust over the next several days as shown in the exhibit. Which of the following dermatomes are most likely involved in this patient's disease process?

A. L1-L2

B. L3-L4

C. L5-S1

D. S2-S3

E. No specific dermatome pattern

Submit

A 46-year-old man experiences burning pain in his left thigh and leg. The next day, he notices groups of erythematous, tender, fluid-filled vesicles in the painful region. The lesions gradually crust over the next several days as shown in the exhibit. Which of the following dermatomes are most likely involved in this patient's disease process?

- A. L1-L2 (17%)
- ✓ B. L3-L4 (61%)
- C. L5-S1 (9%)
- D. S2-S3 (3%)
- E. No specific dermatome pattern (7%)

Omitted
Correct answer
B

61%
Answered correctly

02 secs
Time Spent

07/03/2020
Last Updated

Explanation

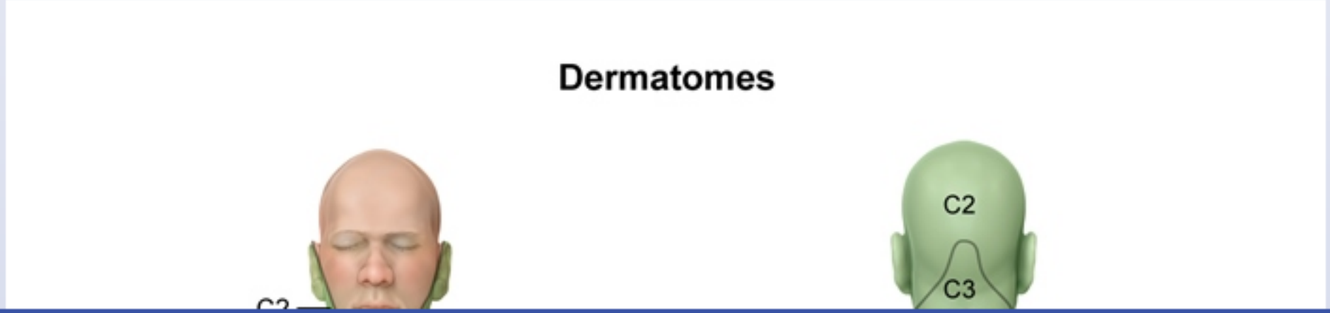

Dermatomes

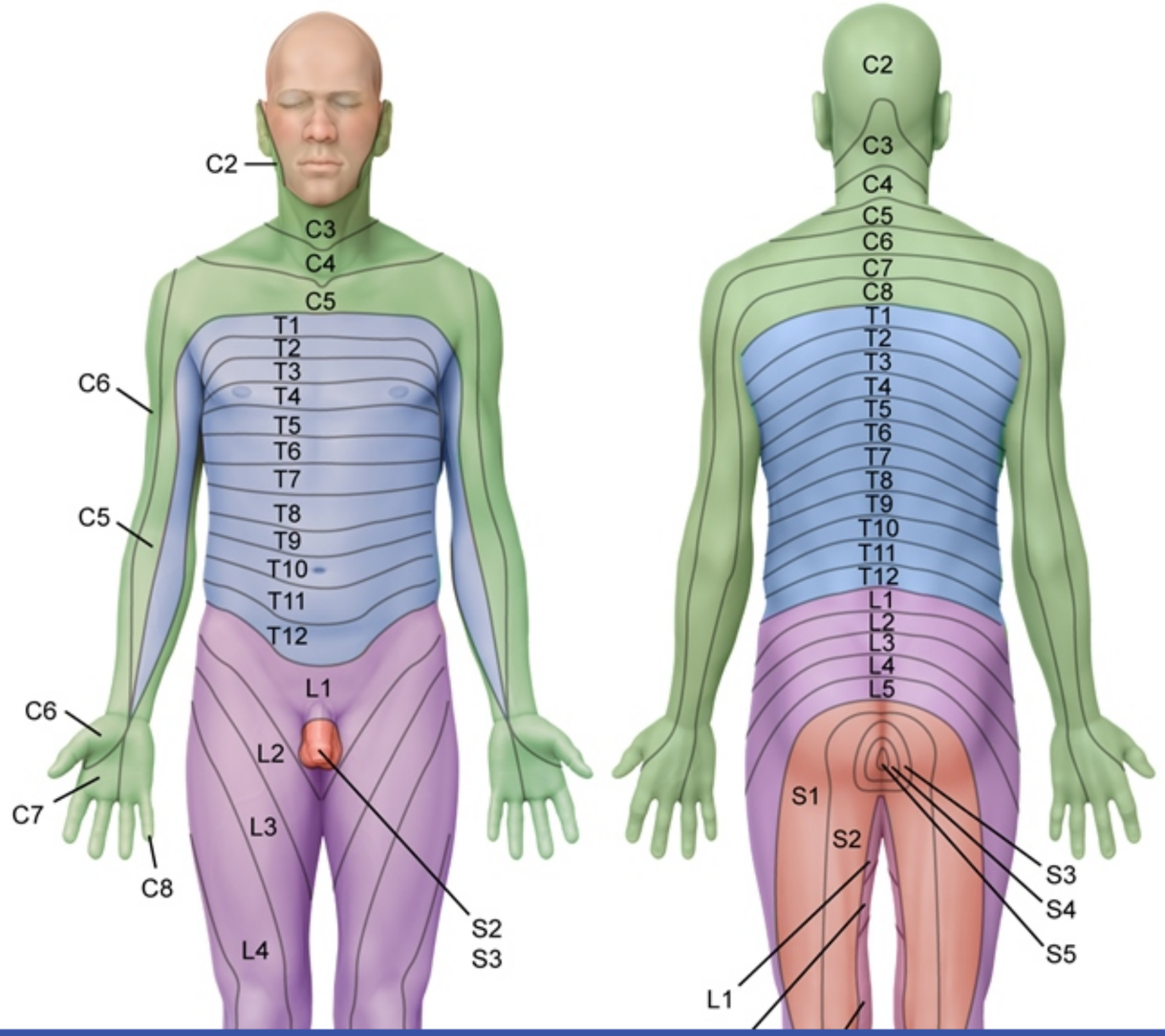
C2
C3
C4
C5
T1
T2
T3
T4
T5
T6
T7
T8
T9
T10
T11
T12
L1
L2
L3
L4
S2
S3
C6
C5
C6
C7
C8
C2
C3
C4
C5
C6
C7
C8
T1
T2
T3
T4
T5
T6
T7
T8
T9
T10
T11
T12
L1
L2
L3
L4
L5
S1
S2
S3
S4
S5
L1

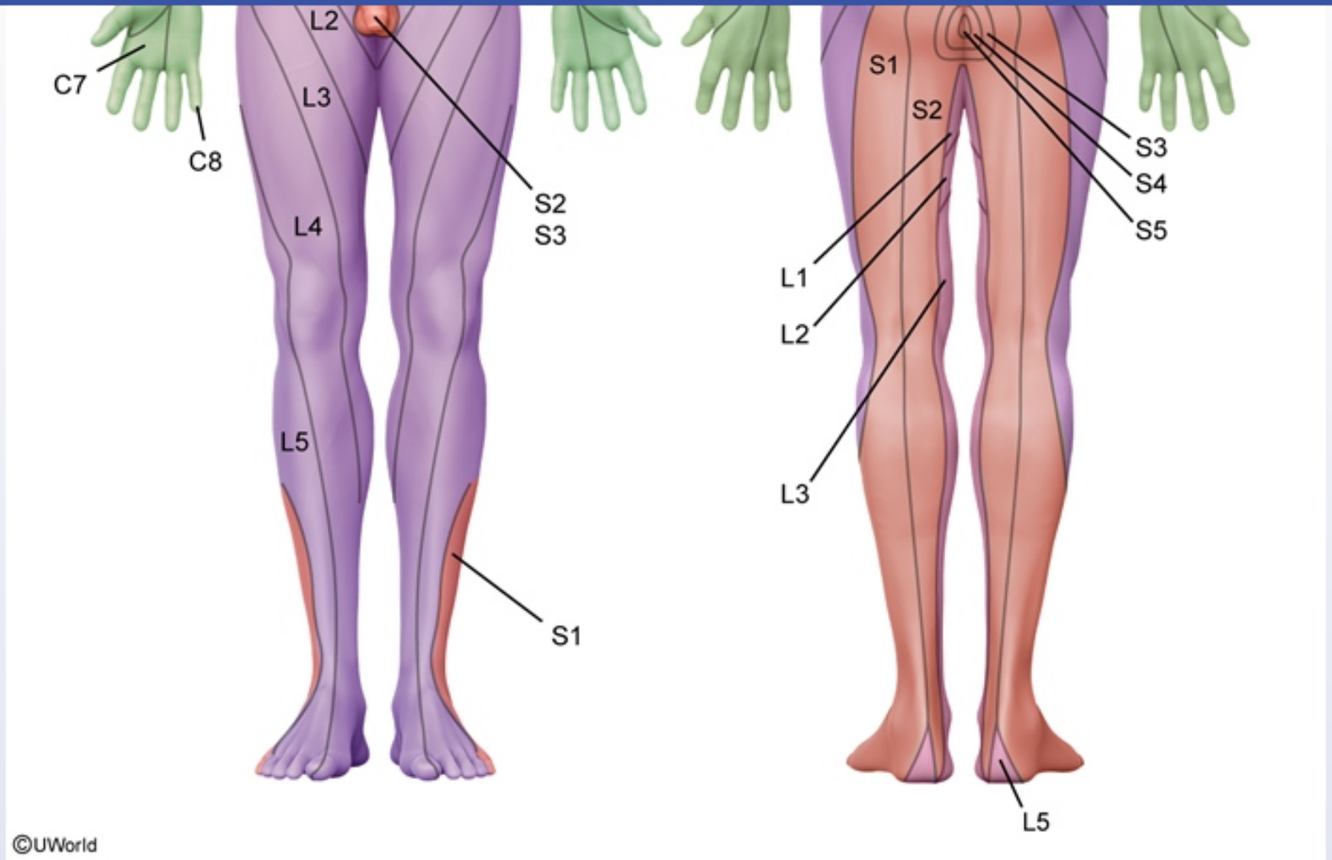

This patient has single and grouped vesicles in various stages of ulceration and crusting, which is consistent with **herpes zoster** (ie, shingles). Following primary VZV infection (ie, chickenpox), the virus migrates via sensory nerves to the **dorsal spinal ganglia**, where it lies dormant for years. Reactivation of the virus typically occurs in a single (or multiple-adjacent) ganglion. This causes hemorrhagic inflammation involving the entire peripheral nerve associated with that ganglion and eruption of a painful, vesicular rash on the skin supplied by that sensory nerve (ie, **dermatome**).

This patient's vesicular rash primarily involves the **anteromedial thigh** and **medial leg**, which is consistent with the dermatomal distribution of **L3 and L4**.

This patient has single and grouped vesicles in various stages of ulceration and crusting, which is consistent with **herpes zoster** (ie, shingles). Following primary VZV infection (ie, chickenpox), the virus migrates via sensory nerves to the **dorsal spinal ganglia**, where it lies dormant for years. Reactivation of the virus typically occurs in a single (or multiple-adjacent) ganglion. This causes hemorrhagic inflammation involving the entire peripheral nerve associated with that ganglion and eruption of a painful, vesicular rash on the skin supplied by that sensory nerve (ie, **dermatome**).

This patient's vesicular rash primarily involves the **anteromedial thigh** and **medial leg**, which is consistent with the dermatomal distribution of **L3 and L4**.

(Choice A) The L1 dermatome is at the level of the inguinal ligament. The L2 dermatome covers the upper anteromedial thigh but does not extend downward into the leg.

(Choice C) The L5 dermatome covers the lateral thigh and anterolateral leg along with the dorsum/sole of the foot. The S1 dermatome includes the posterior thigh and leg and the lateral portion of the foot.

(Choice D) The S2 dermatome supplies portions of the posterior thigh and leg as well as the perineum. S3 primarily supplies the perineum.

(Choice E) Primary VZV infection (ie, chickenpox) produces a generalized vesicular rash. However, reactivation typically occurs in a single (or multiple-adjacent) spinal ganglia, leading to a rash confined to the distribution of those nerves (ie, dermatome).

Educational objective:
Herpes zoster reactivation typically occurs in a single or multiple-adjacent dorsal spinal ganglia, leading to a vesicular rash in a dermatomal distribution. The L3 and L4 dermatomes supply the anteromedial thigh and medial leg.

Anatomy	Nervous System	Herpes zoster
Subject	System	Topic

Copyright © UWorld. All rights reserved.

A 64-year-old man comes to the emergency department due to left lower extremity weakness. The patient was asymptomatic when he went to bed the night before, but he has had difficulty standing after waking up today. He has had no headache, double vision, or back pain. Medical history is significant for hypertension, diabetes mellitus, and myocardial infarction. Temperature is 37 C (98.6 F), blood pressure is 140/90 mm Hg, and pulse is 110/min and irregularly irregular. Left lower extremity examination shows motor power is 0/5, deep tendon reflexes are 3+, and Babinski sign is present. Right lower extremity examination is normal. An abnormality in which of the following structures is the most likely cause of this patient's symptoms?

A. Anterior spinal artery of the lumbosacral region

B. Left posterior inferior cerebellar artery

C. Lumbosacral spinal neuroforamina

D. Right anterior cerebral artery

E. Right middle cerebral artery

Submit

A 64-year-old man comes to the emergency department due to left lower extremity weakness. The patient was asymptomatic when he went to bed the night before, but he has had difficulty standing after waking up today. He has had no headache, double vision, or back pain. Medical history is significant for hypertension, diabetes mellitus, and myocardial infarction. Temperature is 37 C (98.6 F), blood pressure is 140/90 mm Hg, and pulse is 110/min and irregularly irregular. Left lower extremity examination shows motor power is 0/5, deep tendon reflexes are 3+, and Babinski sign is present. Right lower extremity examination is normal. An abnormality in which of the following structures is the most likely cause of this patient's symptoms?

- A. Anterior spinal artery of the lumbosacral region (5%)
- B. Left posterior inferior cerebellar artery (3%)
- C. Lumbosacral spinal neuroforamina (2%)
- ✓ D. Right anterior cerebral artery (74%)
- E. Right middle cerebral artery (13%)

Omitted
Correct answer
D

74%
Answered correctly

01 sec
Time Spent

03/22/2020
Last Updated

Explanation

Cerebral stroke patterns

Sensory **Motor**

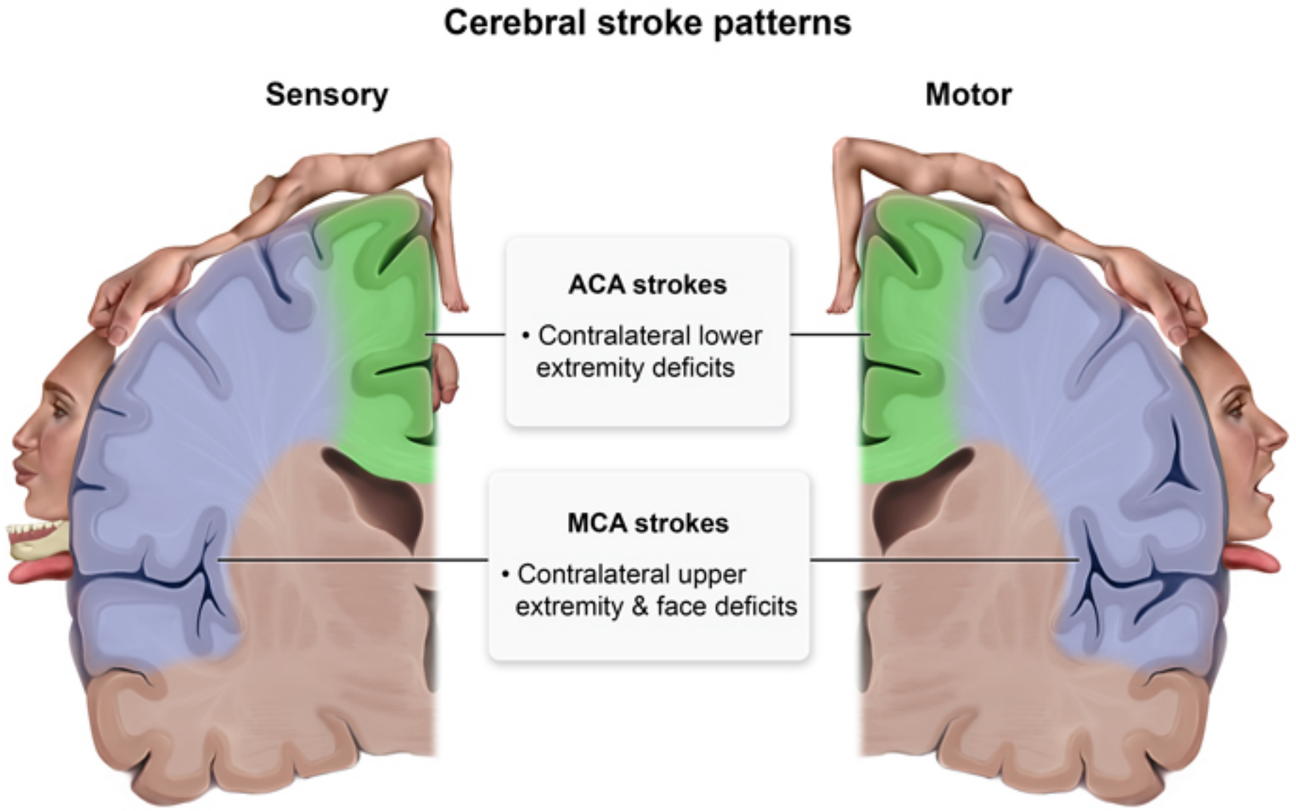

ACA = anterior cerebral artery; **MCA** = middle cerebral artery.

©UWorld

This patient with **atrial fibrillation** (irregularly irregular pulse, tachycardia) has isolated left lower extremity motor deficits, most likely caused by a **cardioembolic stroke** in the **right anterior cerebral artery** (ACA) territory. The ACA supplies the medial aspects of the frontal and parietal lobes, a region which contains the upper motor neurons responsible for contralateral lower extremity motor control. Occlusion of the ACA characteristically causes **contralateral lower limb weakness** with upper motor neuron signs (eg, hyperreflexia, Babinski sign).

The most common etiology of ACA stroke is cardiac embolization due to atrial fibrillation, which can cause blood flow stasis resulting in thrombus formation in the left atrial appendage. Atrial thromboemboli frequently travel to and obstruct branches of ACA or middle cerebral artery (MCA),

This patient with **atrial fibrillation** (irregularly irregular pulse, tachycardia) has isolated left lower extremity motor deficits, most likely caused by a **cardioembolic stroke** in the **right anterior cerebral artery** (ACA) territory. The ACA supplies the medial aspects of the frontal and parietal lobes, a region which contains the upper motor neurons responsible for contralateral lower extremity motor control. Occlusion of the ACA characteristically causes **contralateral lower limb weakness** with upper motor neuron signs (eg, hyperreflexia, Babinski sign).

The most common etiology of ACA stroke is cardiac embolization due to atrial fibrillation, which can cause blood flow stasis resulting in thrombus formation in the left atrial appendage. Atrial thromboemboli frequently travel to and obstruct branches of ACA or middle cerebral artery (MCA), causing cerebral ischemia with associated neurologic defects.

(Choice A) An embolic occlusion of the anterior spinal artery in the lumbosacral region would cause bilateral lower extremity weakness with hyporeflexia (ischemia of the anterior horns and corticospinal tracts) and loss of pain and temperature sensation (ischemia of the spinothalamic tracts) below the level of the lesion.

(Choice B) Posterior inferior cerebellar artery occlusion characteristically causes ischemia in the lateral medulla (Wallenberg syndrome) and inferior cerebellar peduncle, resulting in dysphagia, hoarseness, and vestibulocerebellar symptoms (eg, ataxia, dizziness, nystagmus).

(Choice C) Although lumbosacral neural foraminal stenosis can cause unilateral lower extremity weakness, compression injury of a spinal nerve root (lower motor neuron fibers) at this level would typically result in significant radicular back and leg pain with hyporeflexia.

(Choice E) MCA strokes predominantly affect the upper extremity and are often associated with homonymous hemianopia, aphasia, and hemineglect. Although large MCA strokes can also cause lower extremity weakness, the defects in those cases are usually extensive and involve both the upper and lower extremities (hemiparesis).

Educational objective:
The anterior cerebral artery (ACA) supplies the medial aspects of the frontal and parietal lobes, which contain the upper motor neurons responsible for contralateral lower extremity motor control. Thromboembolic occlusion of the ACA characteristically results in contralateral lower extremity weakness with hyperreflexia.

Anatomy	Nervous System	Ischemic stroke
Subject	System	Topic

This patient with **atrial fibrillation** (irregularly irregular pulse, tachycardia) has isolated left lower extremity motor deficits, most likely caused by a

Exhibit Display

Atrial fibrillation with thrombus formation

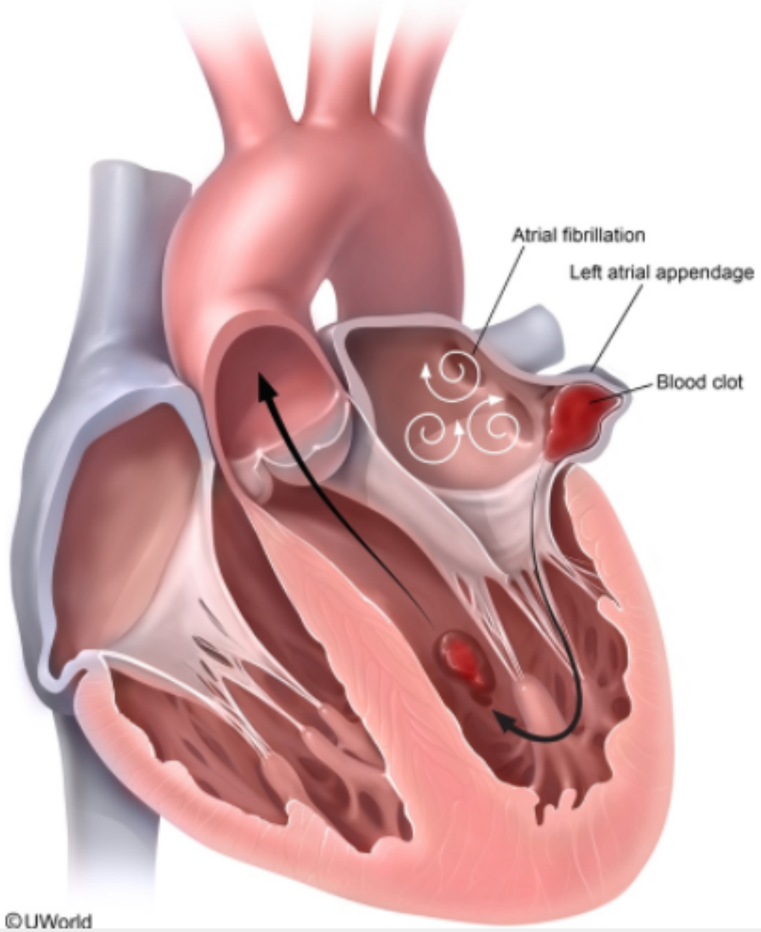

Zoom In | Zoom Out | Reset | Add To New Card | Existing Card

This patient with **atrial fibrillation** (irregularly irregular pulse, tachycardia) has isolated left lower extremity motor deficits, most likely caused by a

Exhibit Display

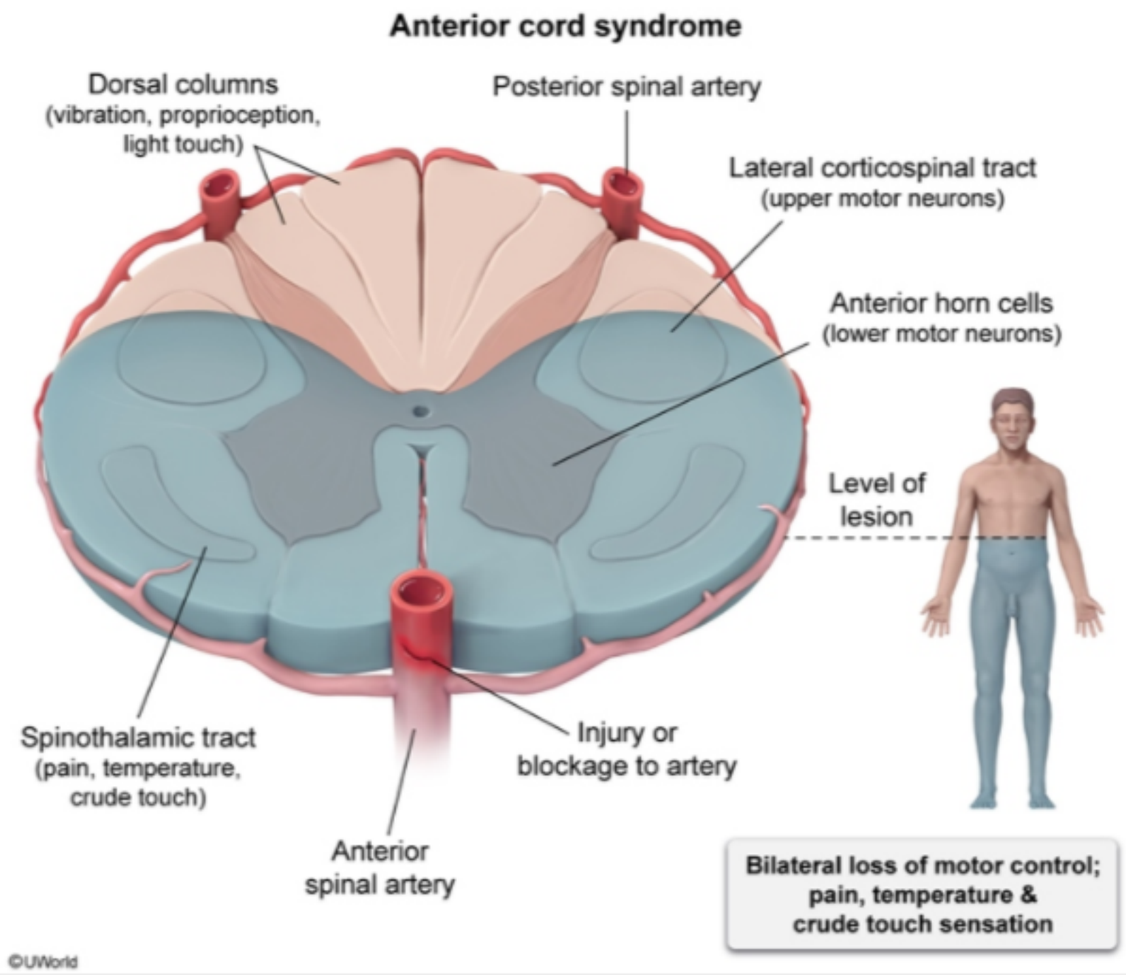

Zoom In | Zoom Out | Reset | Add To New Card | Existing Card

This patient with **atrial fibrillation** (irregularly irregular pulse, tachycardia) has isolated left lower extremity motor deficits, most likely caused by a

Exhibit Display

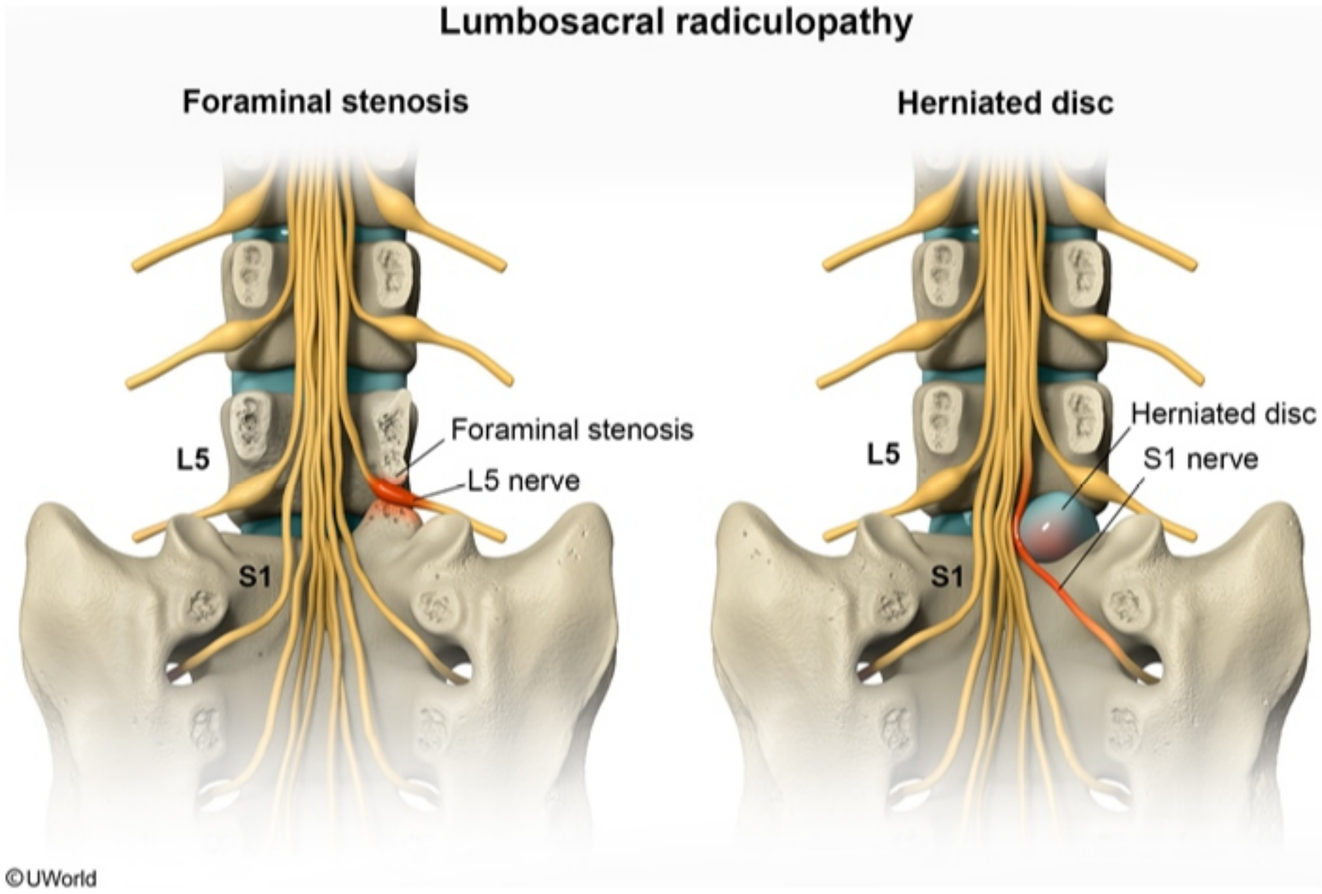

Zoom In | Zoom Out | Reset | Add To New Card | Existing Card

A 43-year-old, right-handed woman is evaluated in the clinic for progressively worsening neurologic symptoms. The patient has a history of diabetes mellitus and hyperlipidemia for which she takes metformin and a statin. She has no history of head trauma or seizures. The patient occasionally drinks wine but does not use tobacco or illicit drugs. Her mother has a history of migraine headaches. A brain MRI is obtained and is shown in the image below:

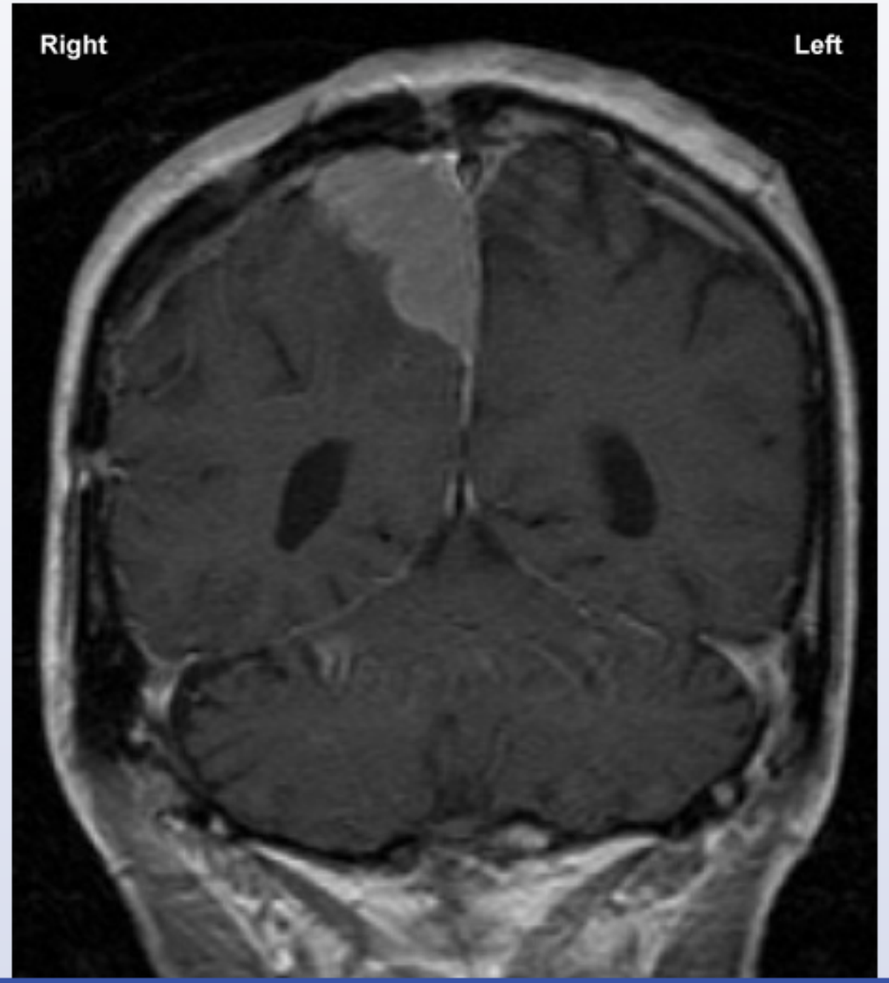

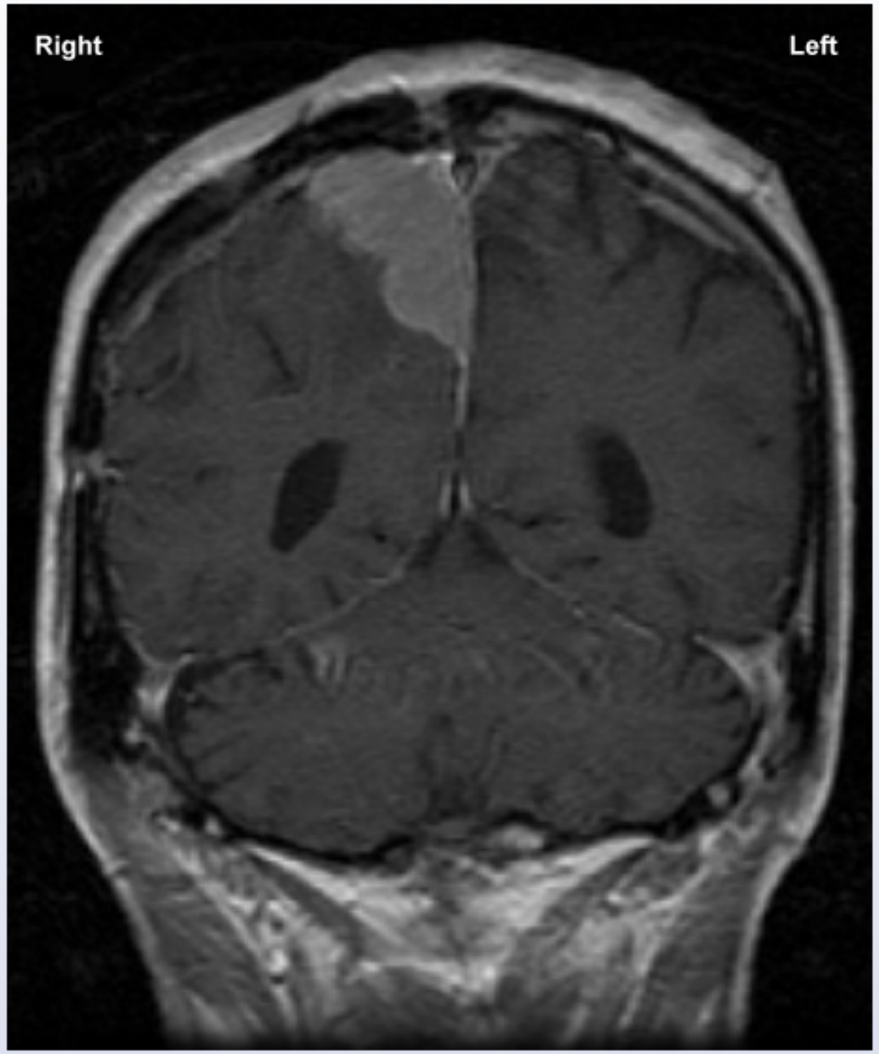

This patient is most likely to have which of the following additional findings?

A. Bitemporal visual field defects

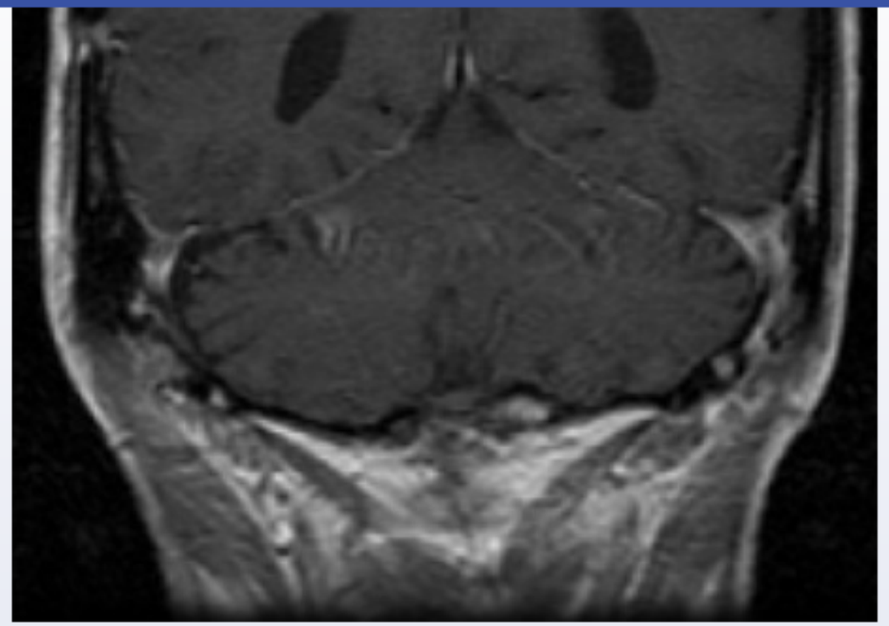

This patient is most likely to have which of the following additional findings?

- A. Bitemporal visual field defects
- B. Hand weakness and spasticity
- C. Lower limb sensory loss and hemineglect
- D. Tinnitus and unilateral hearing loss
- E. Unilateral ptosis and gaze palsy

Submit

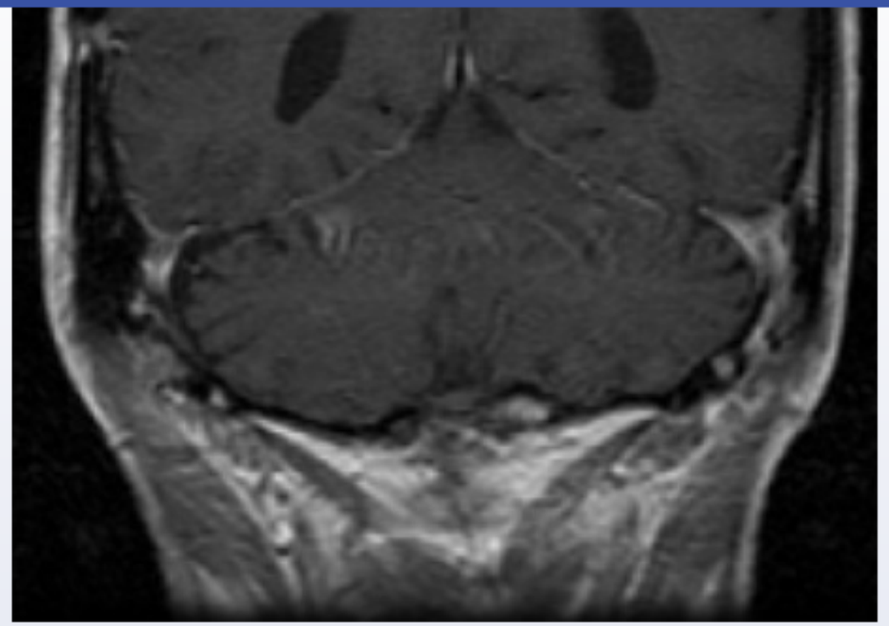

This patient is most likely to have which of the following additional findings?

- A. Bitemporal visual field defects (2%)
- B. Hand weakness and spasticity (14%)
- ✓ C. Lower limb sensory loss and hemineglect (78%)
- D. Tinnitus and unilateral hearing loss (1%)
- E. Unilateral ptosis and gaze palsy (3%)

Omitted
Correct answer

78%
Answered correctly

06 secs
Time Spent

02/10/2020
Last Updated

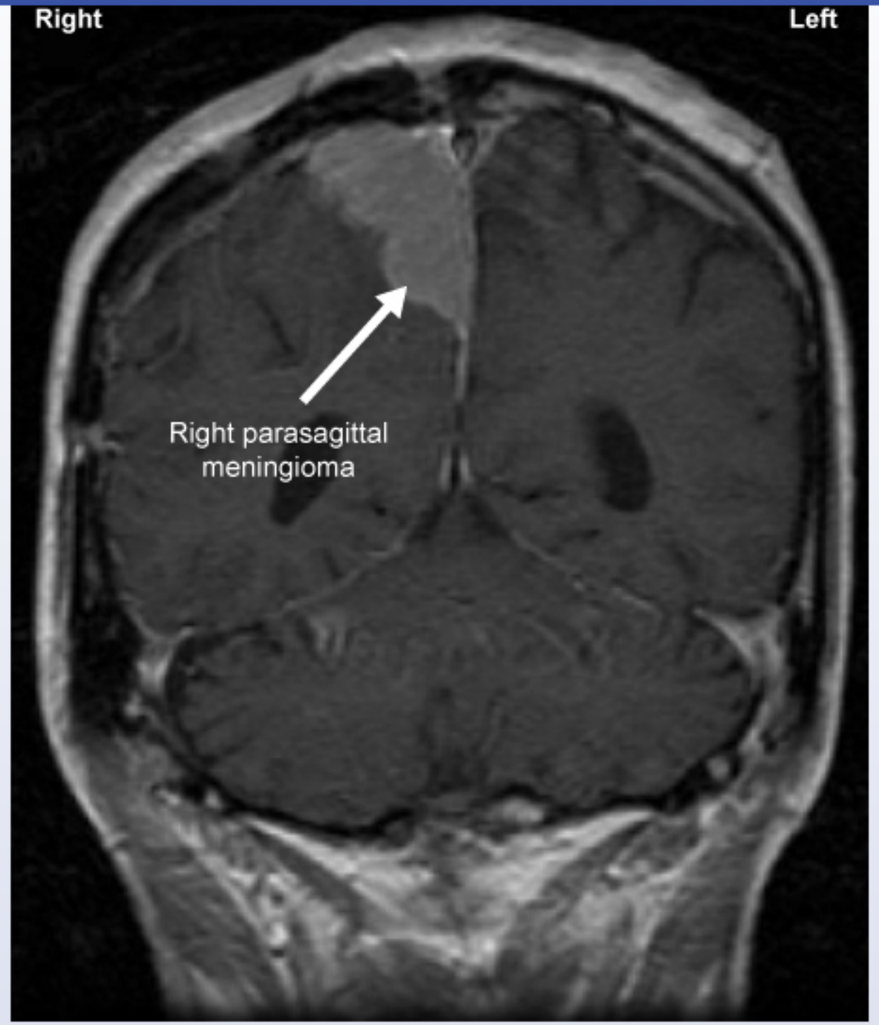

This patient with progressive neurologic symptoms and a well-circumscribed parasagittal tumor most likely has a **meningioma**. Meningiomas are benign, slow-growing intracranial tumors that typically affect adults and tend to arise near **dural reflections** (eg, falx cerebri, tentorium cerebelli). Patients are often asymptomatic but may have headache, seizure, or focal neurologic deficits depending on tumor size and location.

The tumor's parasagittal location compresses the medial portion of the cerebral cortex, which has a somatotopic organization. The medial portion

This patient with progressive neurologic symptoms and a well-circumscribed parasagittal tumor most likely has a **meningioma**. Meningiomas are benign, slow-growing intracranial tumors that typically affect adults and tend to arise near **dural reflections** (eg, falx cerebri, tentorium cerebelli). Patients are often asymptomatic but may have headache, seizure, or focal neurologic deficits depending on tumor size and location.

The tumor's parasagittal location compresses the medial portion of the cerebral cortex, which has a somatotopic organization. The medial portion corresponds with the lower extremities, while the lateral portion corresponds with the trunk and upper extremities. This patient's tumor is affecting the medial portion of the postcentral gyrus (primary somatosensory cortex), most likely resulting in **sensory loss** in the **contralateral lower limb**. Involvement of the adjacent parietal association cortex (particularly in the nondominant hemisphere as in this patient) can result in **contralateral hemineglect** due to this region's role in visuospatial processing.

(Choice A) Bitemporal hemianopia can occur due to compression of the central portion of the optic chiasm and is commonly caused by pituitary masses or craniopharyngiomas.

(Choice B) Hand weakness and spasticity can occur with meningiomas over the lateral convexity compressing the lateral portion of the primary motor cortex in the frontal lobe.

(Choice D) Tinnitus and unilateral hearing loss are common presenting features of vestibular schwannoma, a peripheral nerve tumor characteristically located at the cerebellopontine angle.

(Choice E) Unilateral ptosis and gaze palsy ("down and out" gaze) are characteristic of oculomotor nerve palsy, which may occur with nerve damage due to compression (eg, berry aneurysm, uncal herniation) or microvascular ischemia (eg, diabetes mellitus).

Educational objective:
Meningiomas are common adult intracranial tumors that typically arise in regions of dural reflection (eg, falx cerebri, tentorium cerebelli). Parasagittal lesions compressing the medial portion of the primary somatosensory cortex in the parietal lobe can result in contralateral lower limb sensory loss along with contralateral hemineglect if there is also damage to the parietal association cortex (nondominant hemisphere).

References

- Meningioma.
- Intracranial meningiomas: an overview of diagnosis and treatment.

Anatomy Nervous System Brain tumors

This patient with progressive neurologic symptoms and a well-circumscribed parasagittal tumor most likely has a **meningioma**. Meningiomas are benign, slow-growing intracranial tumors that typically affect adults and tend to arise near **dural reflections** (eg, falx cerebri, tentorium cerebelli).

Exhibit Display

Homunculus

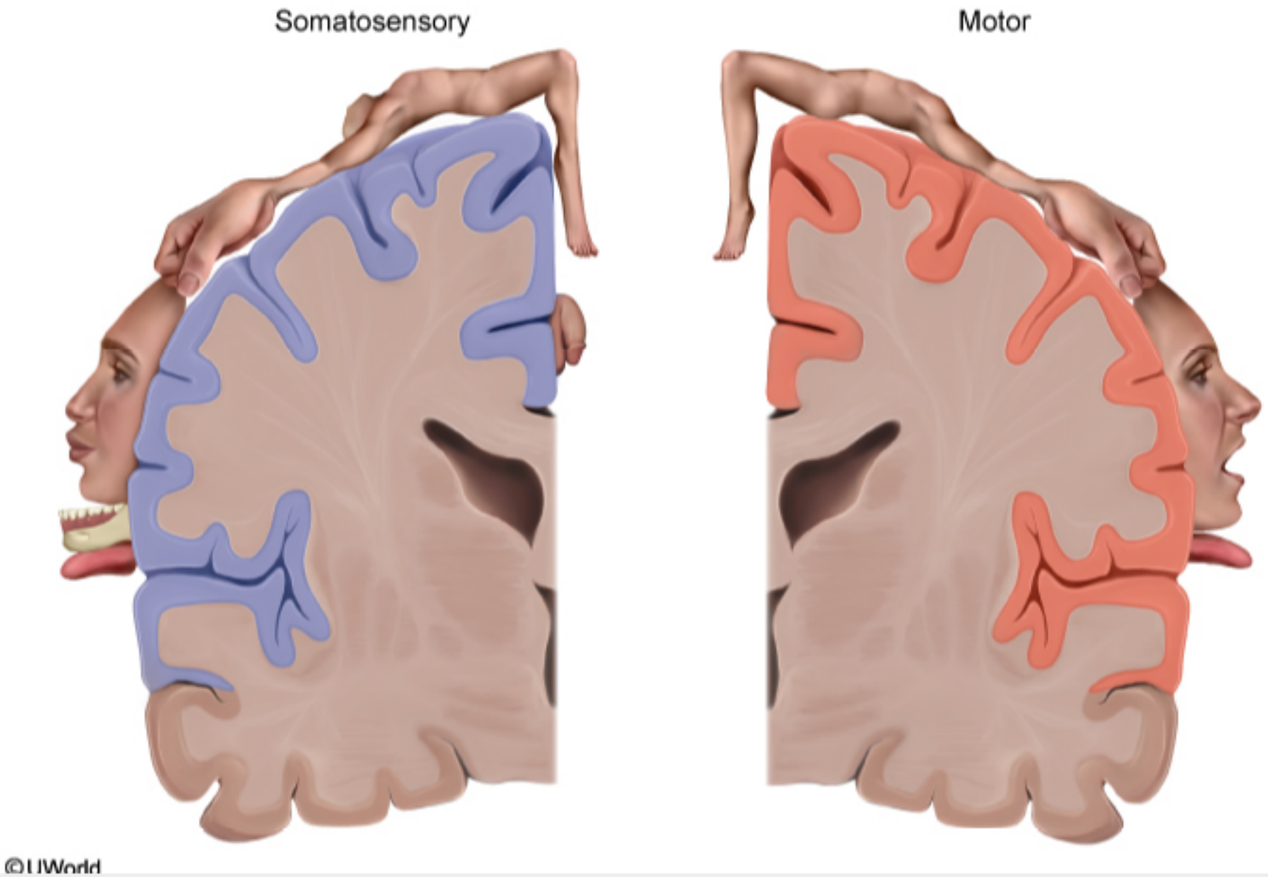

Zoom In | Zoom Out | Reset | Add To New Card | Existing Card

Anatomy | Nervous System | Brain tumors

This patient with progressive neurologic symptoms and a well-circumscribed parasagittal tumor most likely has a **meningioma**. Meningiomas are benign, slow-growing intracranial tumors that typically affect adults and tend to arise near **dural reflections** (eg, falx cerebri, tentorium cerebelli).

Exhibit Display

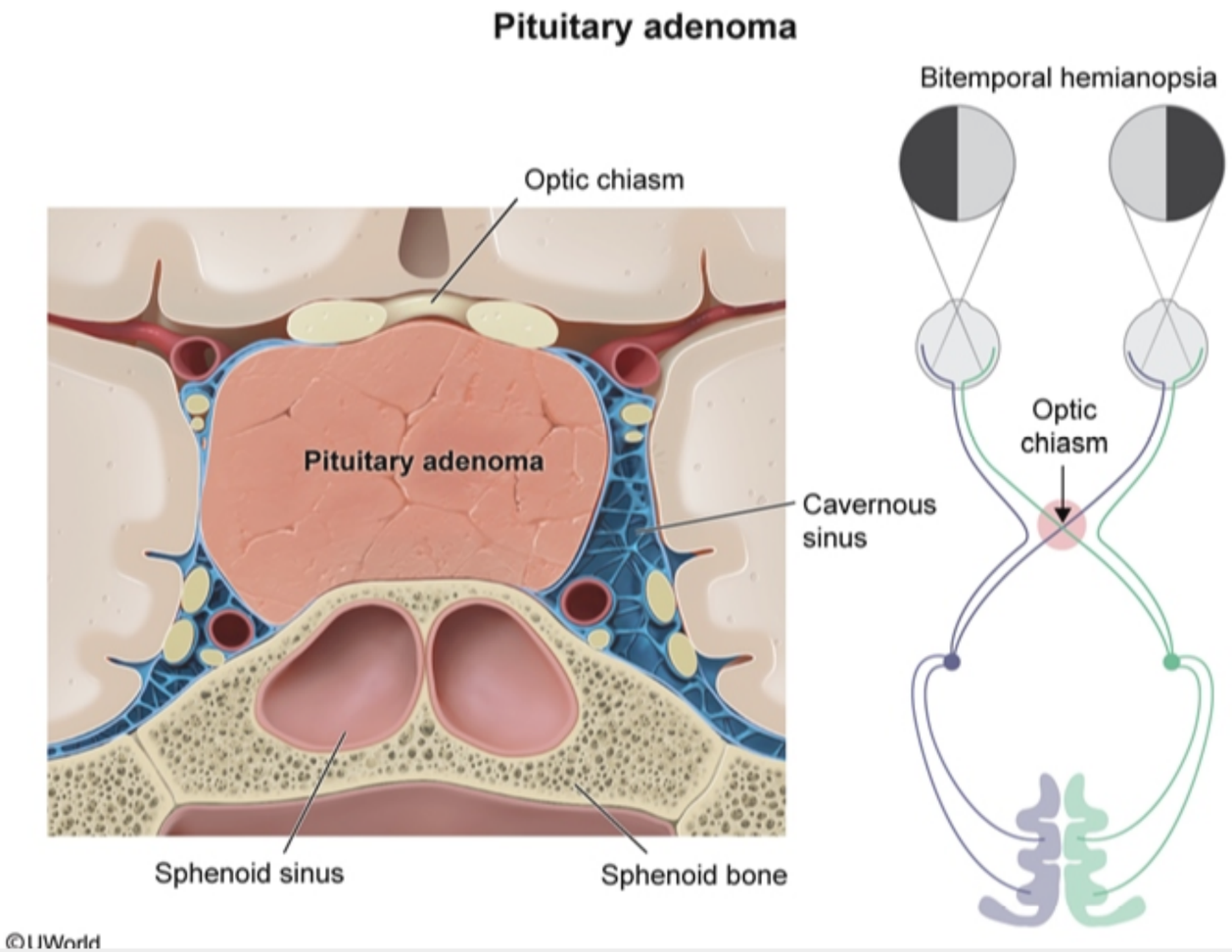

Zoom In | Zoom Out | Reset | Add To New Card | Existing Card

Anatomy | Nervous System | Brain tumors

This patient with progressive neurologic symptoms and a well-circumscribed parasagittal tumor most likely has a **meningioma**. Meningiomas are benign, slow-growing intracranial tumors that typically affect adults and tend to arise near **dural reflections** (eg, falx cerebri, tentorium cerebelli).

Exhibit Display

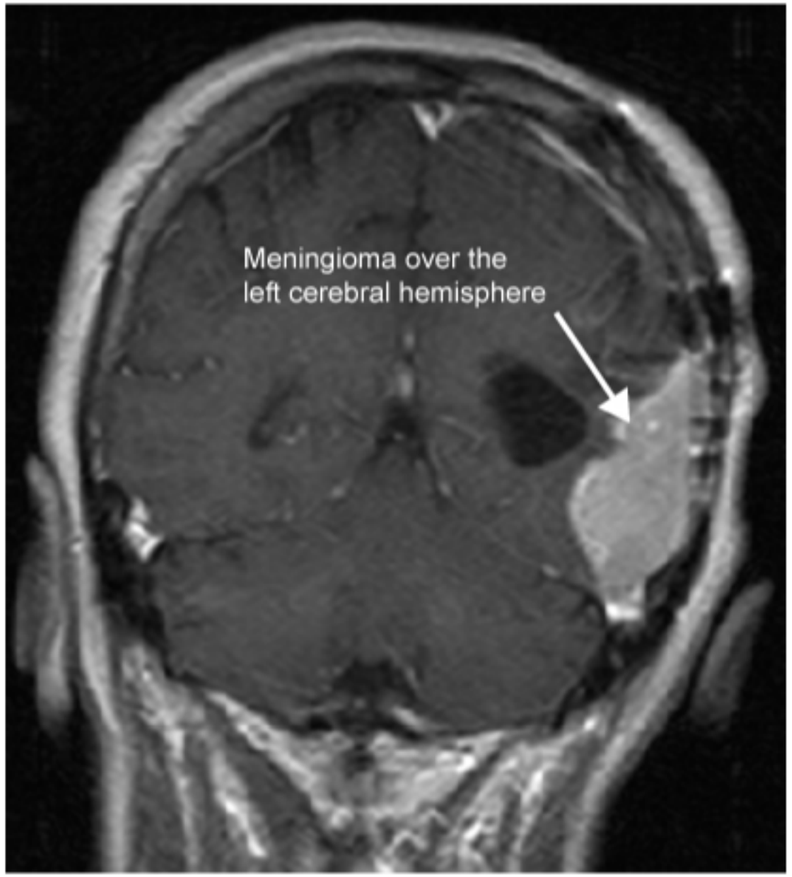

Zoom In | Zoom Out | Reset | Add To New Card | Existing Card

Anatomy | Nervous System | Brain tumors

This patient with progressive neurologic symptoms and a well-circumscribed parasagittal tumor most likely has a **meningioma**. Meningiomas are benign, slow-growing intracranial tumors that typically affect adults and tend to arise near **dural reflections** (eg, falx cerebri, tentorium cerebelli).

Exhibit Display

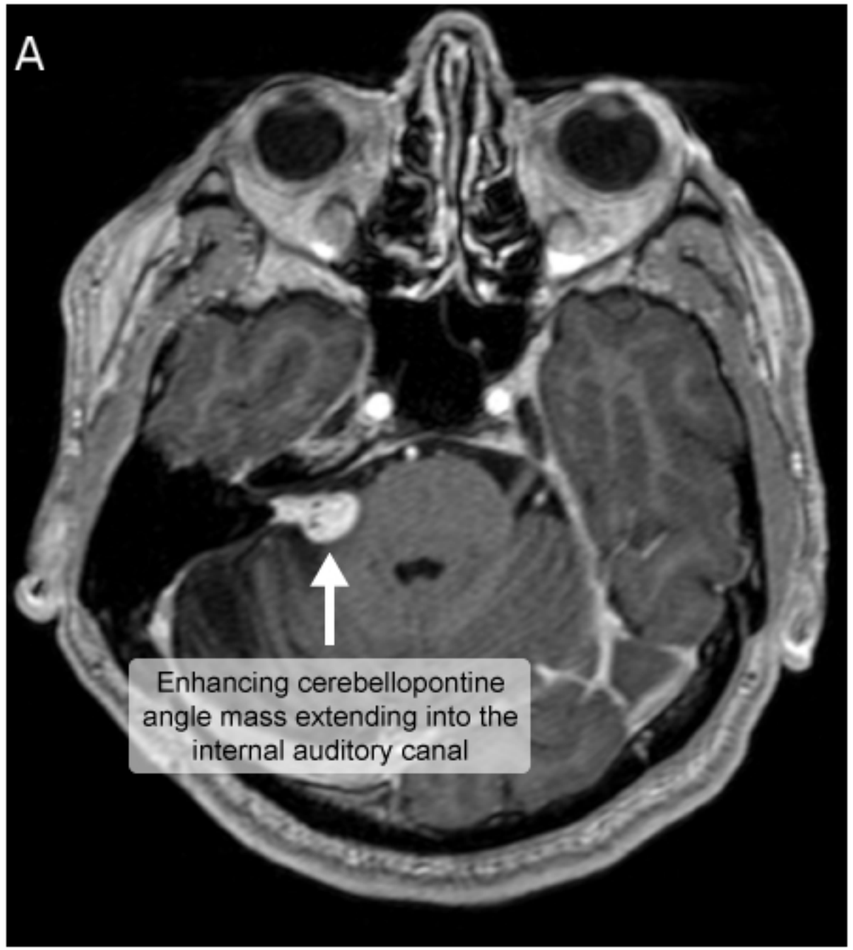

Zoom In | Zoom Out | Reset | Add To New Card | Existing Card

Anatomy | Nervous System | Brain tumors

This patient with progressive neurologic symptoms and a well-circumscribed parasagittal tumor most likely has a **meningioma**. Meningiomas are benign, slow-growing intracranial tumors that typically affect adults and tend to arise near **dural reflections** (eg, falx cerebri, tentorium cerebelli).

Exhibit Display

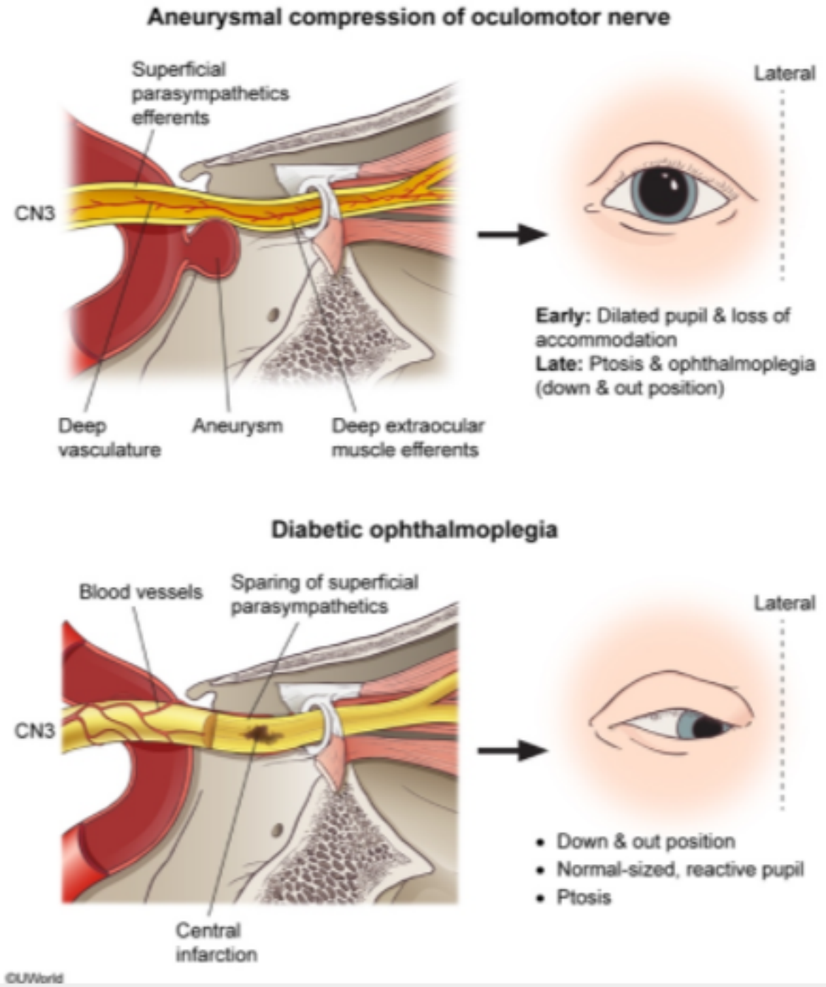

Zoom In | Zoom Out | Reset | Add To New Card | Existing Card

Anatomy | Nervous System | Brain tumors

A 52-year-old man comes to the office after his wife noted that his eyes appeared different. The patient reports no symptoms. Medical history is significant for hypertension and type 2 diabetes mellitus. He has smoked 1.5 packs of cigarettes daily for 25 years. Blood pressure is 140/86 mm Hg and pulse is 84/min. On physical examination, the right pupil is 3 mm and the left pupil is 5 mm. When the light in the examination room is dimmed, the anisocoria increases. Which of the following is the most likely location of the lesion?

- A. Left oculomotor nerve
- B. Left oculosympathetic pathway
- C. Left optic nerve
- D. Right oculomotor nerve
- E. Right oculosympathetic pathway
- F. Right optic nerve

Submit

A 52-year-old man comes to the office after his wife noted that his eyes appeared different. The patient reports no symptoms. Medical history is significant for hypertension and type 2 diabetes mellitus. He has smoked 1.5 packs of cigarettes daily for 25 years. Blood pressure is 140/86 mm Hg and pulse is 84/min. On physical examination, the right pupil is 3 mm and the left pupil is 5 mm. When the light in the examination room is dimmed, the anisocoria increases. Which of the following is the most likely location of the lesion?

- A. Left oculomotor nerve (18%)
- B. Left oculosympathetic pathway (14%)
- C. Left optic nerve (6%)
- D. Right oculomotor nerve (12%)
- ✓ E. Right oculosympathetic pathway (40%)
- F. Right optic nerve (7%)

Omitted
Correct answer
E

40%
Answered correctly

02 secs
Time Spent

04/07/2020
Last Updated

Explanation

Pupillary asymmetry

In room light

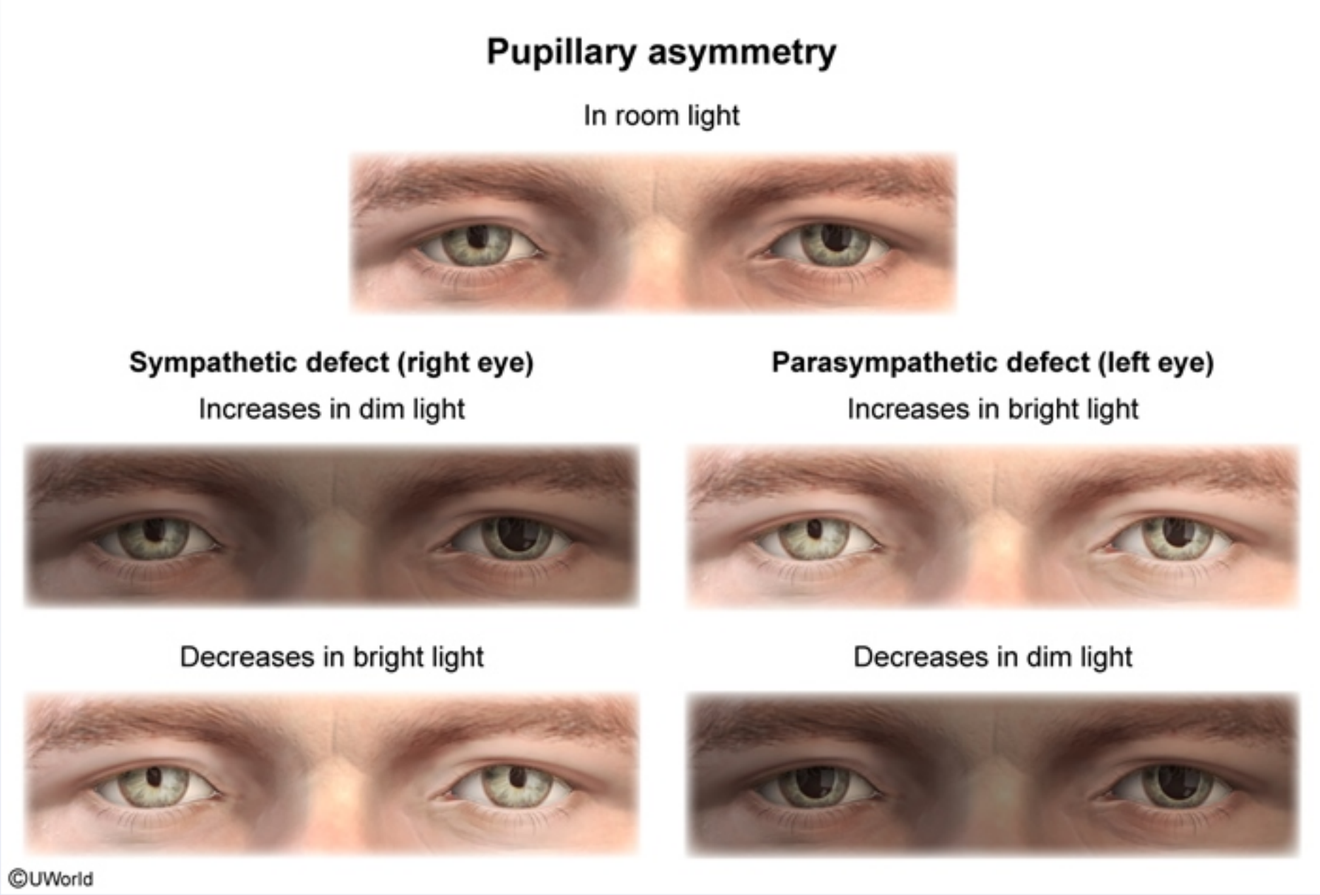

This patient has **anisocoria** (ie, pupillary asymmetry), which indicates a **unilateral defect** in input from either the ocular sympathetic (pupil dilation) or parasympathetic (pupil constriction) pathway. In response to **dim light**, input from the **oculosympathetic pathway** initiates pupillary **dilation**, allowing more light to reach the retina. Under bright light, parasympathetic input from the ipsilateral oculomotor nerve (CN III) initiates pupillary constriction, limiting the amount of light received by the retina.

Determining which pathway is affected in anisocoria can be accomplished by observing the change in pupillary discrepancy in both bright and dim light:

This patient has **anisocoria** (ie, pupillary asymmetry), which indicates a **unilateral defect** in input from either the ocular sympathetic (pupil dilation) or parasympathetic (pupil constriction) pathway. In response to **dim light**, input from the **oculosympathetic pathway** initiates pupillary **dilation**, allowing more light to reach the retina. Under bright light, parasympathetic input from the ipsilateral oculomotor nerve (CN III) initiates pupillary constriction, limiting the amount of light received by the retina.

Determining which pathway is affected in anisocoria can be accomplished by observing the change in pupillary discrepancy in both bright and dim light:

- Asymmetry that increases in dim light indicates that the smaller pupil is unable to dilate (ie, miosis) due to loss of sympathetic nerve input. Under bright light, the asymmetry will decrease because parasympathetic input (pupillary constriction) is unaffected.
- Asymmetry that increases under bright light indicates that the larger pupil is unable to constrict (ie, mydriasis) due to loss of parasympathetic nerve input. In dim light, the asymmetry will decrease because sympathetic input (pupillary dilation) is unaffected.

This patient has **increased asymmetry** in a **dim room**, indicating that the smaller (right) pupil is unable to dilate due to loss of sympathetic nerve input secondary to a **lesion** in the **right oculosympathetic pathway**.

(Choices A and D) An oculomotor nerve lesion would disrupt parasympathetic innervation of the ipsilateral pupil, resulting in anisocoria that increases under bright light because the abnormal larger pupil is unable to constrict in response to light.

(Choice B) Damage to the left oculosympathetic pathway would cause loss of sympathetic input to the left eye, resulting in a fixed, constricted pupil in the left eye (with increased asymmetry in dim light) rather than in the right.

(Choices C and F) The optic nerves carry the afferent portions of the pupillary reflex from each eye. A unilateral optic nerve lesion would not cause pupillary asymmetry, but instead monocular vision loss and decreased bilateral pupillary constriction in response to light entering the affected eye (ie, relative afferent pupillary defect).

Educational objective:
Pupillary asymmetry (ie, anisocoria) is caused by a lesion in the ocular parasympathetic (pupillary constriction) or sympathetic (pupillary dilation) pathways. In this patient, the pupillary asymmetry increases in a dim room, indicating that the smaller right pupil is unable to dilate due to a lesion in the right oculosympathetic pathway.

Determining which pathway is affected in anisocoria can be accomplished by observing the change in pupillary discrepancy in both bright and dim light:

- Asymmetry that increases in dim light indicates that the smaller pupil is unable to dilate (ie, miosis) due to loss of sympathetic nerve input. Under bright light, the asymmetry will decrease because parasympathetic input (pupillary constriction) is unaffected.
- Asymmetry that increases under bright light indicates that the larger pupil is unable to constrict (ie, mydriasis) due to loss of parasympathetic nerve input. In dim light, the asymmetry will decrease because sympathetic input (pupillary dilation) is unaffected.

This patient has **increased asymmetry** in a **dim room**, indicating that the smaller (right) pupil is unable to dilate due to loss of sympathetic nerve input secondary to a **lesion** in the **right oculosympathetic pathway**.

(Choices A and D) An oculomotor nerve lesion would disrupt parasympathetic innervation of the ipsilateral pupil, resulting in anisocoria that increases under bright light because the abnormal larger pupil is unable to constrict in response to light.

(Choice B) Damage to the left oculosympathetic pathway would cause loss of sympathetic input to the left eye, resulting in a fixed, constricted pupil in the left eye (with increased asymmetry in dim light) rather than in the right.

(Choices C and F) The optic nerves carry the afferent portions of the pupillary reflex from each eye. A unilateral optic nerve lesion would not cause pupillary asymmetry, but instead monocular vision loss and decreased bilateral pupillary constriction in response to light entering the affected eye (ie, relative afferent pupillary defect).

Educational objective:
Pupillary asymmetry (ie, anisocoria) is caused by a lesion in the ocular parasympathetic (pupillary constriction) or sympathetic (pupillary dilation) pathways. In this patient, the pupillary asymmetry increases in a dim room, indicating that the smaller right pupil is unable to dilate due to a lesion in the right oculosympathetic pathway.

Anatomy	Nervous System	Horner syndrome
Subject	System	Topic

Copyright © UWorld. All rights reserved.

Determining which pathway is affected in anisocoria can be accomplished by observing the change in pupillary discrepancy in both bright and dim

Exhibit Display

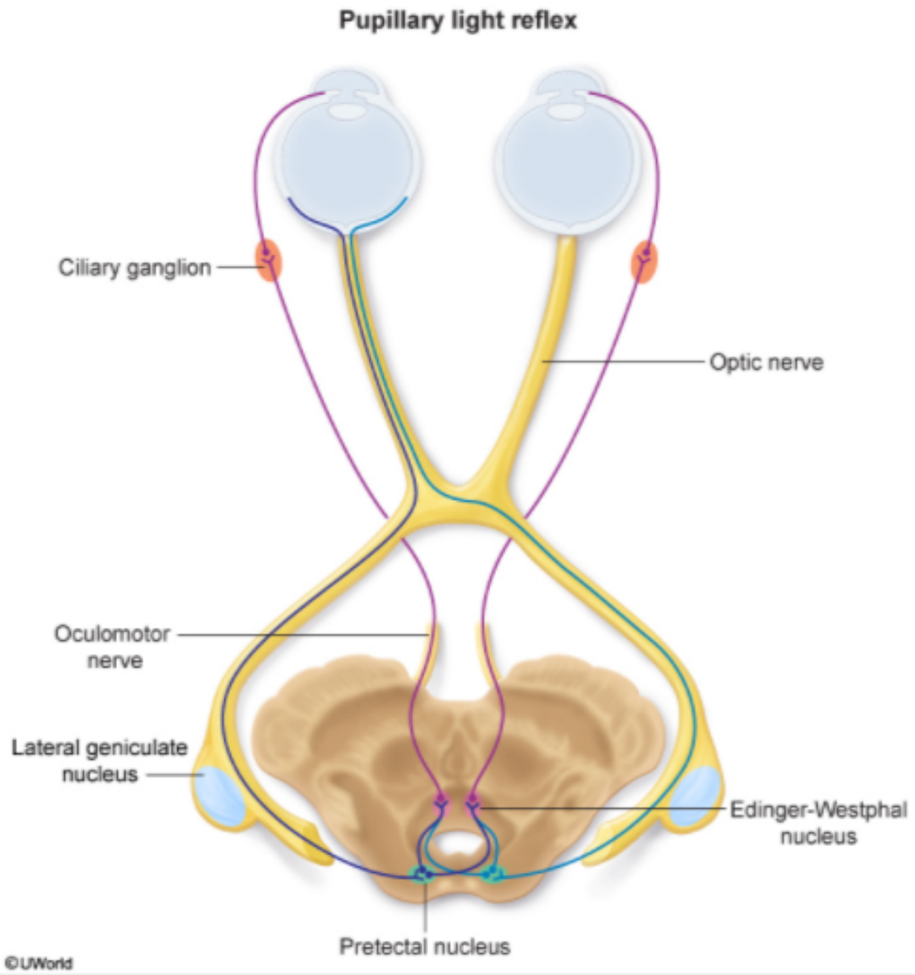

Zoom In
Zoom Out
Reset
Add To Flash Card

Determining which pathway is affected in anisocoria can be accomplished by observing the change in pupillary discrepancy in both bright and dim light:

- Asymmetry that incr ... t. Under bright light, th
- Asymmetry that incr ... netic nerve input. In dim

This patient has **increase** ... rve input secondary to a **lesio**

(Choices A and D) An oc ... increases under bright ligh

(Choice B) Damage to th ... d pupil in the left eye (with ir

(Choices C and F) The c ... cause pupillary asymmetry affected eye (ie, relative a

Educational objective:
Pupillary asymmetry (ie, a ... n) pathways. In this patient, ... sion in the right oculosympathe

Anatomy
Subject

Nervous
System

Exhibit Display

UWorld

Normal pupillary light reflex

0:00 / 1:17

Copyright © UWorld. All rights reserved.

A 64-year-old man comes to the office due to progressive low back pain for the past several months that is beginning to interfere with his job. The patient describes pain in the lower back and buttocks, which worsens with prolonged standing or walking and improves with lying down. He also has occasional sharp, shooting pain that radiates down his right leg. The patient works as a greeter for a local supermarket and was recently given a written warning for taking too many breaks during his shift. He has a history of hypertension and osteoarthritis. Spine imaging reveals degenerative joint changes and a large osteophyte compressing the spinal nerve root exiting through the right neural foramen between the L5 and S1 vertebrae. Which of the following examination findings is most likely present in this patient due to the nerve lesion?

A. Decreased knee reflex

B. Decreased rectal tone

C. Sensory loss in inguinal region

D. Weakness of foot dorsiflexion

E. Weakness of hip flexion

Submit

A 64-year-old man comes to the office due to progressive low back pain for the past several months that is beginning to interfere with his job. The patient describes pain in the lower back and buttocks, which worsens with prolonged standing or walking and improves with lying down. He also has occasional sharp, shooting pain that radiates down his right leg. The patient works as a greeter for a local supermarket and was recently given a written warning for taking too many breaks during his shift. He has a history of hypertension and osteoarthritis. Spine imaging reveals degenerative joint changes and a large osteophyte compressing the spinal nerve root exiting through the right neural foramen between the L5 and S1 vertebrae. Which of the following examination findings is most likely present in this patient due to the nerve lesion?

- A. Decreased knee reflex (6%)
- B. Decreased rectal tone (7%)
- C. Sensory loss in inguinal region (6%)
- ✓ D. Weakness of foot dorsiflexion (68%)
- E. Weakness of hip flexion (10%)

Omitted
Correct answer
D

68%
Answered correctly

03 secs
Time Spent

06/18/2020
Last Updated

Explanation

Features of lumbosacral radiculopathy			
Nerve Root	Reflex affected	Sensory loss*	Weakness
			• Hip flexion (iliopsoas)

Features of lumbosacral radiculopathy			
Nerve Root	**Reflex affected**	**Sensory loss***	**Weakness**
L2-L4**	• Patellar	• Anteromedial thigh • Medial shin	• Hip flexion (iliopsoas) • Hip adduction • Knee extension (quadriceps)
L5	• None	• Lateral shin • Dorsum of the foot	• Foot dorsiflexion & inversion (tibialis anterior) • Foot eversion (peroneus) • Toe extension (extensor hallucis and digitorum)
S1	• Achilles	• Posterior calf • Sole & lateral foot	• Hip extension (gluteus maximus) • Foot plantarflexion (gastrocnemius)
S2-S4**	• None	• Perineum	• Urinary or fecal incontinence • Sexual dysfunction

*Radicular pain typically has a similar distribution to sensory loss.

** Difficult to distinguish clinically.

This patient has lumbosacral radiculopathy due to an osteophyte at the **L5-S1 neural foramen** resulting in compression of the **L5 nerve root**. Spinal nerves in the lumbosacral spine exit below their corresponding vertebral body level (eg, L5 nerve root exits between L5 and S1 vertebral bodies). However, because of the presence of multiple spinal nerve roots in the lumbosacral area (ie, cauda equina), nerve root compression can occur at different vertebral levels through 2 distinct mechanisms:

- **Spinal spondylosis:** Degenerative changes and osteophyte formation can narrow the neural foramina. This leads to nerve root compression as it **passes through the neural foramina** (in this patient, an osteophyte is compressing the exiting L5 nerve root).
- **Vertebral disc herniation:** A tear in the intervertebral disc annulus can lead to herniation of the nucleus pulposus. If this occurs laterally, it can compress the exiting nerve root as it passes through the neural foramina. However, if it occurs more centrally, it can protrude into the

This patient has lumbosacral radiculopathy due to an osteophyte at the **L5-S1 neural foramen** resulting in compression of the **L5 nerve root**. Spinal nerves in the lumbosacral spine exit below their corresponding vertebral body level (eg, L5 nerve root exits between L5 and S1 vertebral bodies). However, because of the presence of multiple spinal nerve roots in the lumbosacral area (ie, cauda equina), nerve root compression can occur at different vertebral levels through 2 distinct mechanisms:

- **Spinal spondylosis:** Degenerative changes and osteophyte formation can narrow the neural foramina. This leads to nerve root compression as it **passes through the neural foramina** (in this patient, an osteophyte is compressing the exiting L5 nerve root).
- **Vertebral disc herniation:** A tear in the intervertebral disc annulus can lead to herniation of the nucleus pulposus. If this occurs laterally, it can compress the exiting nerve root as it passes through the neural foramina. However, if it occurs more centrally, it can protrude into the spinal canal and compress other nerves in the cauda equina that exit one or more **levels below the area of herniation**.

L5 radiculopathy causes sensory loss and back pain that radiates down the leg in an L5 dermatomal distribution (eg, buttocks, lateral thigh and calf, dorsal foot). Weakness occurs in muscles innervated by fibers from the L5 spinal root, which include the tibialis anterior (**foot dorsiflexion** and inversion), peroneus (foot eversion), and extensor hallucis longus (great toe extension).

(Choice A) The patellar (knee) reflex is mediated by the quadriceps muscle, which is innervated by L2-L4 nerve roots.

(Choice B) Decreased rectal tone can be seen with damage to the pudendal nerve, which originates from the S2-S4 nerve roots.

(Choice C) The skin overlying the inguinal region is innervated by fibers from the L1 spinal nerve root that travel in the ilioinguinal and genitofemoral nerves.

(Choice E) Hip flexion occurs due to contraction of the iliopsoas, which is innervated by the L2-L4 nerve roots.

Educational objective:
Spinal nerves in the lumbosacral spine exit through the neural foramina that is below the corresponding vertebral body level (eg, L5 nerve root exits between L5 and S1 vertebral bodies) and can be compressed at the neural foramina due to osteophyte formation. In addition to back pain, L5 radiculopathy often presents with sensory loss over the lateral thigh, calf, and dorsal foot and weakness of great toe extension and foot dorsiflexion, inversion, and eversion.

References

- A review of lumbar radiculopathy, diagnosis, and treatment.

compression as it **passes through the neural foramina** (in this patient, an osteophyte is compressing the exiting L5 nerve root).

- **Vertebral disc herniation:** A tear in the intervertebral disc annulus can lead to herniation of the nucleus pulposus. If this occurs laterally, it can compress the exiting nerve root as it passes through the neural foramina. However, if it occurs more centrally, it can protrude into the spinal canal and compress other nerves in the cauda equina that exit one or more **levels below the area of herniation**.

L5 radiculopathy causes sensory loss and back pain that radiates down the leg in an L5 dermatomal distribution (eg, buttocks, lateral thigh and calf, dorsal foot). Weakness occurs in muscles innervated by fibers from the L5 spinal root, which include the tibialis anterior (**foot dorsiflexion** and inversion), peroneus (foot eversion), and extensor hallucis longus (great toe extension).

(Choice A) The patellar (knee) reflex is mediated by the quadriceps muscle, which is innervated by L2-L4 nerve roots.

(Choice B) Decreased rectal tone can be seen with damage to the pudendal nerve, which originates from the S2-S4 nerve roots.

(Choice C) The skin overlying the inguinal region is innervated by fibers from the L1 spinal nerve root that travel in the ilioinguinal and genitofemoral nerves.

(Choice E) Hip flexion occurs due to contraction of the iliopsoas, which is innervated by the L2-L4 nerve roots.

Educational objective:
Spinal nerves in the lumbosacral spine exit through the neural foramina that is below the corresponding vertebral body level (eg, L5 nerve root exits between L5 and S1 vertebral bodies) and can be compressed at the neural foramina due to osteophyte formation. In addition to back pain, L5 radiculopathy often presents with sensory loss over the lateral thigh, calf, and dorsal foot and weakness of great toe extension and foot dorsiflexion, inversion, and eversion.

References

- A review of lumbar radiculopathy, diagnosis, and treatment.

Anatomy	Nervous System	Radiculopathy
Subject	System	Topic

Copyright © UWorld. All rights reserved.

S1	• Achilles	• Sole & lateral foot	• Foot plantarflexion (gastrocnemius)
S2-S4**	•		• Urinary or fecal incontinence

*Radicular pain typically

** Difficult to distinguish

This patient has lumbosac
Spinal nerves in the lumb
bodies). However, becau
occur at different vertebra

- **Spinal spondylosi**
  compression as it **p**
- **Vertebral disc herr**
  can compress the e
  spinal canal and co

L5 radiculopathy causes
calf, dorsal foot). Weakne
and inversion), peroneus (

(Choice A) The patellar (

(Choice B) Decreased re

(Choice C) The skin over
genitofemoral nerves.

(Choice E) Hip flexion occurs due to contraction of the iliopsoas, which is innervated by the L2-L4 nerve roots.

Educational objective:

Exhibit Display

Relation of spinal nerve roots to vertebrae

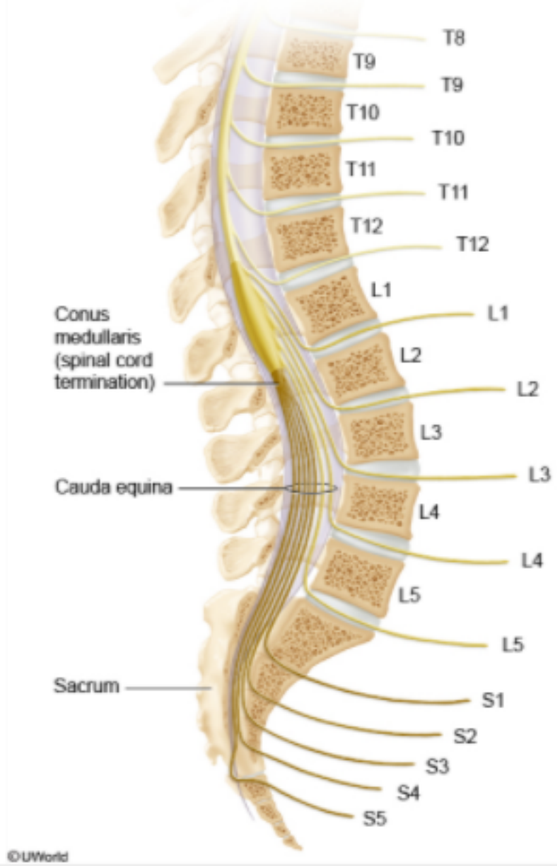

Zoom In Zoom Out Reset Add To Flash Card

A 71-year-old man comes to the office due to a painful rash on his right forehead. Two days ago, he felt burning pain on his right forehead and today noticed some blisters. On examination, there is a vesicular rash involving the right forehead and right side of the nose. The patient is at risk of blindness in the right eye due to involvement of which of the following cranial nerves?

- A. Abducens
- B. Facial
- C. Oculomotor
- D. Optic
- E. Trigeminal
- F. Trochlear

Submit

A 71-year-old man comes to the office due to a painful rash on his right forehead. Two days ago, he felt burning pain on his right forehead and today noticed some blisters. On examination, there is a vesicular rash involving the right forehead and right side of the nose. The patient is at risk of blindness in the right eye due to involvement of which of the following cranial nerves?

- A. Abducens (0%)
- B. Facial (2%)
- C. Oculomotor (1%)
- D. Optic (30%)
- ✓ E. Trigeminal (64%)
- F. Trochlear (0%)

Omitted
Correct answer
E

64%
Answered correctly

02 secs
Time Spent

03/09/2020
Last Updated

Explanation

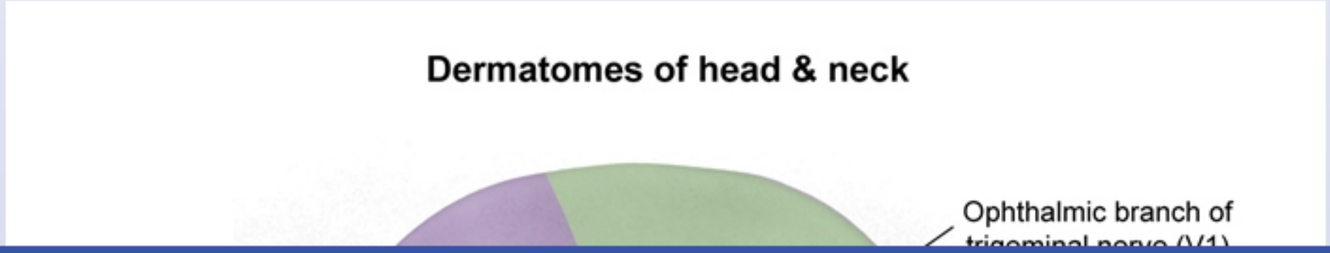

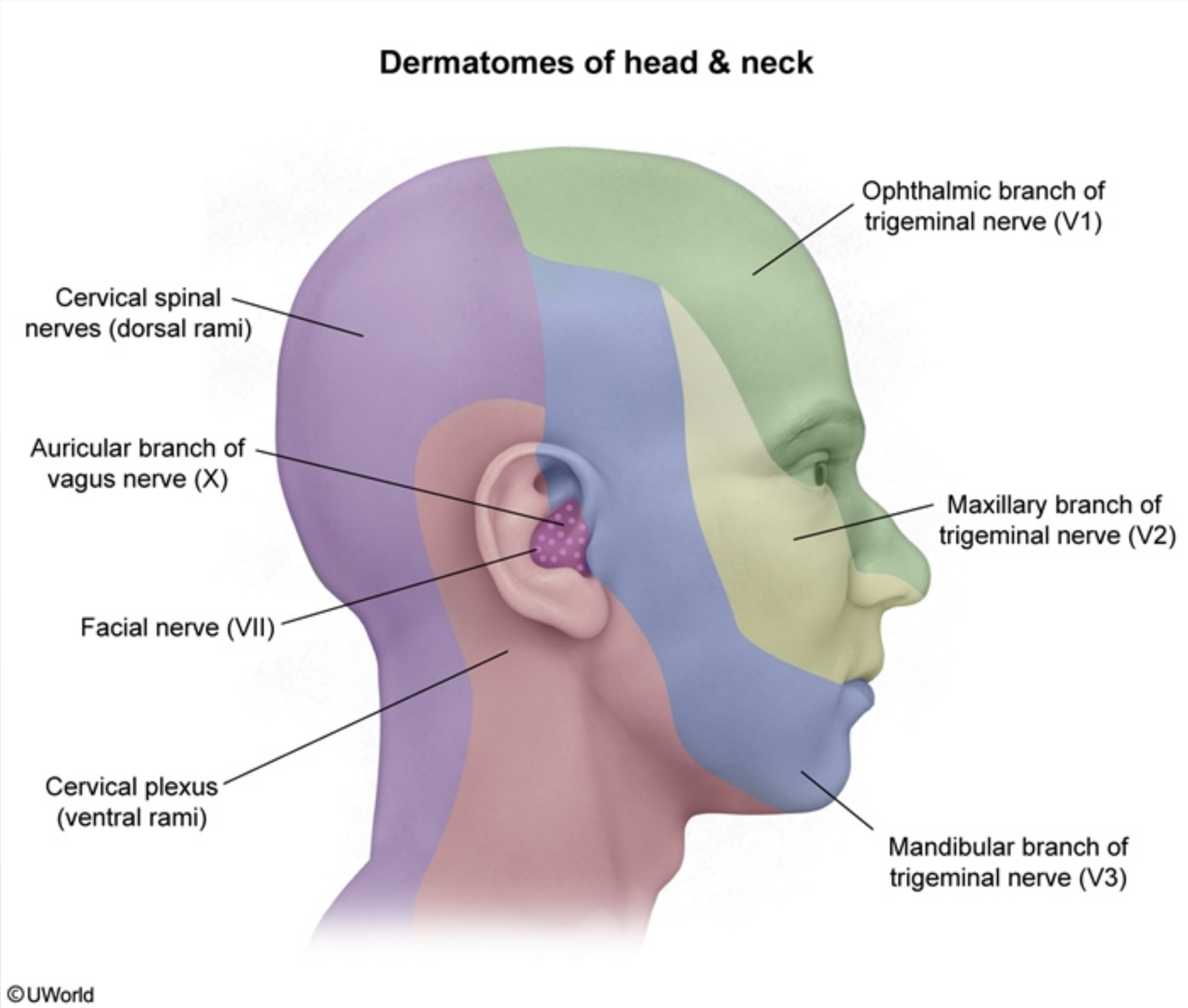
Dermatomes of head & neck
Ophthalmic branch of trigeminal nerve (V1)
Cervical spinal nerves (dorsal rami)
Auricular branch of vagus nerve (X)
Maxillary branch of trigeminal nerve (V2)
Facial nerve (VII)
Cervical plexus (ventral rami)
Mandibular branch of trigeminal nerve (V3)
©UWorld

©UWorld

This patient has **herpes zoster ophthalmicus**, which is caused by reactivation of latent varicella-zoster virus (VZV) in the trigeminal ganglion. Following primary VZV infection (ie, chickenpox), the virus migrates via sensory nerves to the cranial nerve and dorsal spinal ganglia, where it lies **dormant** for years. Reactivation of the virus typically occurs in a single ganglion and causes a painful, vesicular rash in a **dermatomal distribution**.

Viral **reactivation within the trigeminal ganglion** most often affects the ophthalmic division of the trigeminal nerve (CN V1), leading to development of a vesicular rash within the **V1 distribution** (eg, unilateral forehead, side of the nose, and periorbital area). Because CN V1 also conveys sensory innervation of the cornea (sensory limb of the corneal/blink reflex), involvement can cause **acute keratitis**, which can lead to vision loss. Vesicular lesions on the side and tip of the nose (ie, **Hutchinson sign**) have a high correlation with subsequent eye involvement because the nasociliary branch of CN V1 innervates both the eye and the side/tip of the nose.

(Choices A, C, and F) The oculomotor (CN III), trochlear (CN IV), and abducens (CN VI) nerves provide motor innervation to the extraocular muscles. Dysfunction can result in double vision. However, these nerves are not involved in this patient's condition and would not cause blindness if they were.

(Choice B) The facial nerve (CN VII) is affected in herpes zoster oticus (Ramsay Hunt syndrome), which classically presents with ear pain, vesicles in the external auditory canal or auricle, and facial paralysis. The facial nerve innervates the orbicularis oculi muscle to close the eye; therefore, patients with facial nerve paralysis are at risk of exposure keratitis, which can lead to blindness. However, this patient's facial nerve is unaffected.

(Choice D) In rare instances, zoster can cause blindness due to acute retinal necrosis and/or neuritis of the optic nerve (CN II). However, this patient has zoster involvement of CN V1.

Educational objective:
Herpes zoster ophthalmicus is caused by viral reactivation within the trigeminal nucleus. It affects the ophthalmic branch of the trigeminal nerve (CN V1) and can lead to blindness due to acute keratitis because V1 conveys sensory information from the cornea.

References

- Herpes zoster ophthalmicus: acute keratitis.

distribution.

Viral **reactivation within the trigeminal ganglion** most often affects the ophthalmic division of the trigeminal nerve (CN V1), leading to development of a vesicular rash within the **V1 distribution** (eg, unilateral forehead, side of the nose, and periorbital area). Because CN V1 also conveys sensory innervation of the cornea (sensory limb of the corneal/blink reflex), involvement can cause **acute keratitis**, which can lead to vision loss. Vesicular lesions on the side and tip of the nose (ie, **Hutchinson sign**) have a high correlation with subsequent eye involvement because the nasociliary branch of CN V1 innervates both the eye and the side/tip of the nose.

(Choices A, C, and F) The oculomotor (CN III), trochlear (CN IV), and abducens (CN VI) nerves provide motor innervation to the extraocular muscles. Dysfunction can result in double vision. However, these nerves are not involved in this patient's condition and would not cause blindness if they were.

(Choice B) The facial nerve (CN VII) is affected in herpes zoster oticus (Ramsay Hunt syndrome), which classically presents with ear pain, vesicles in the external auditory canal or auricle, and facial paralysis. The facial nerve innervates the orbicularis oculi muscle to close the eye; therefore, patients with facial nerve paralysis are at risk of exposure keratitis, which can lead to blindness. However, this patient's facial nerve is unaffected.

(Choice D) In rare instances, zoster can cause blindness due to acute retinal necrosis and/or neuritis of the optic nerve (CN II). However, this patient has zoster involvement of CN V1.

Educational objective:
Herpes zoster ophthalmicus is caused by viral reactivation within the trigeminal nucleus. It affects the ophthalmic branch of the trigeminal nerve (CN V1) and can lead to blindness due to acute keratitis because V1 conveys sensory information from the cornea.

References

- Herpes zoster ophthalmicus: acute keratitis.

Anatomy	Nervous System	Herpes zoster
Subject	System	Topic

Copyright © UWorld. All rights reserved.

Ce
(V

©UWo

This patient has **herpes z**
Following primary VZV inf
dormant for years. Reac
distribution.

Viral **reactivation within t**
development of a vesicula
conveys sensory innervati
vision loss. Vesicular lesi
because the nasociliary b

(Choices A, C, and F) Th
muscles. Dysfunction car
blindness if they were.

(Choice B) The facial ne
vesicles in the external au
therefore, patients with fac
unaffected.

lies

so

is

(Choice D) In rare instances, zoster can cause blindness due to acute retinal necrosis and/or neuritis of the optic nerve (CN II). However, this

Exhibit Display

Zoom In
Zoom Out
Reset
Add To Flash Card

Exhibit Display

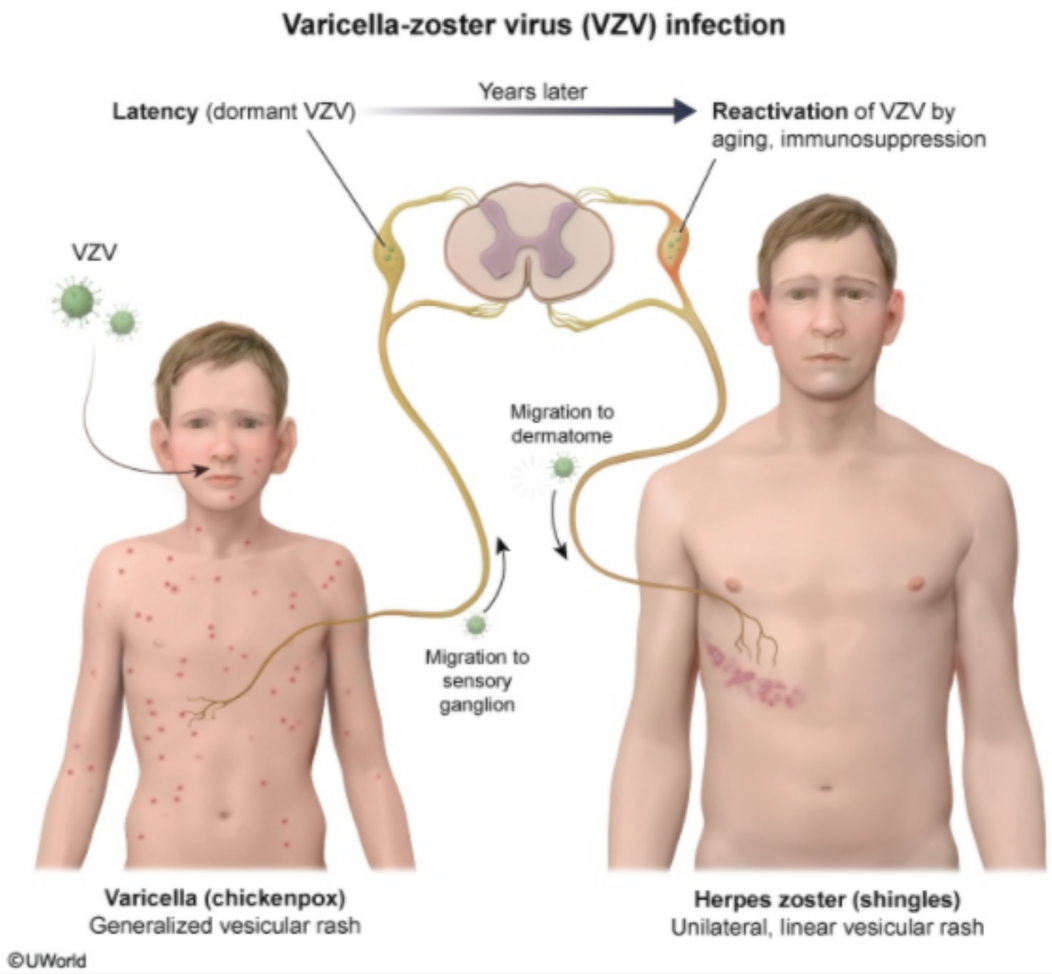

Zoom In Zoom Out Reset Add To Flash Card

(Choice D) In rare instances, zoster can cause blindness due to acute retinal necrosis and/or neuritis of the optic nerve (CN II). However, this

Exhibit Display

Zoom In
Zoom Out
Reset
Add To Flash Card

(Choice D) In rare instances, zoster can cause blindness due to acute retinal necrosis and/or neuritis of the optic nerve (CN II). However, this

A 65-year-old man is brought to the emergency department due to acute-onset, right-sided weakness and slurred speech. He also has a severe headache and nausea. Medical history is significant for poorly controlled hypertension and chronic tobacco use. Blood pressure is 240/120 mm Hg and pulse is 104/min. On physical examination, the patient is lethargic with right hemiparesis and lower facial weakness, right hemisensory loss, and dysarthria. Noncontrast CT scan of the head is shown in the image below.

Which of the following cerebral blood vessels is most likely affected in this patient?

A. Cortical branches

Which of the following cerebral blood vessels is most likely affected in this patient?

- A. Cortical branches
- B. Inferior division of middle cerebral artery
- C. Lenticulostriate arteries
- D. Pontine arteries
- E. Posterior cerebral artery
- F. Superior division of middle cerebral artery

Submit

Which of the following cerebral blood vessels is most likely affected in this patient?

- A. Cortical branches (1%)
- B. Inferior division of middle cerebral artery (19%)
- ✓ C. Lenticulostriate arteries (59%)
- D. Pontine arteries (2%)
- E. Posterior cerebral artery (1%)
- F. Superior division of middle cerebral artery (15%)

Omitted
Correct answer

59%
Answered correctly

04 secs
Time Spent

07/06/2020
Last Updated

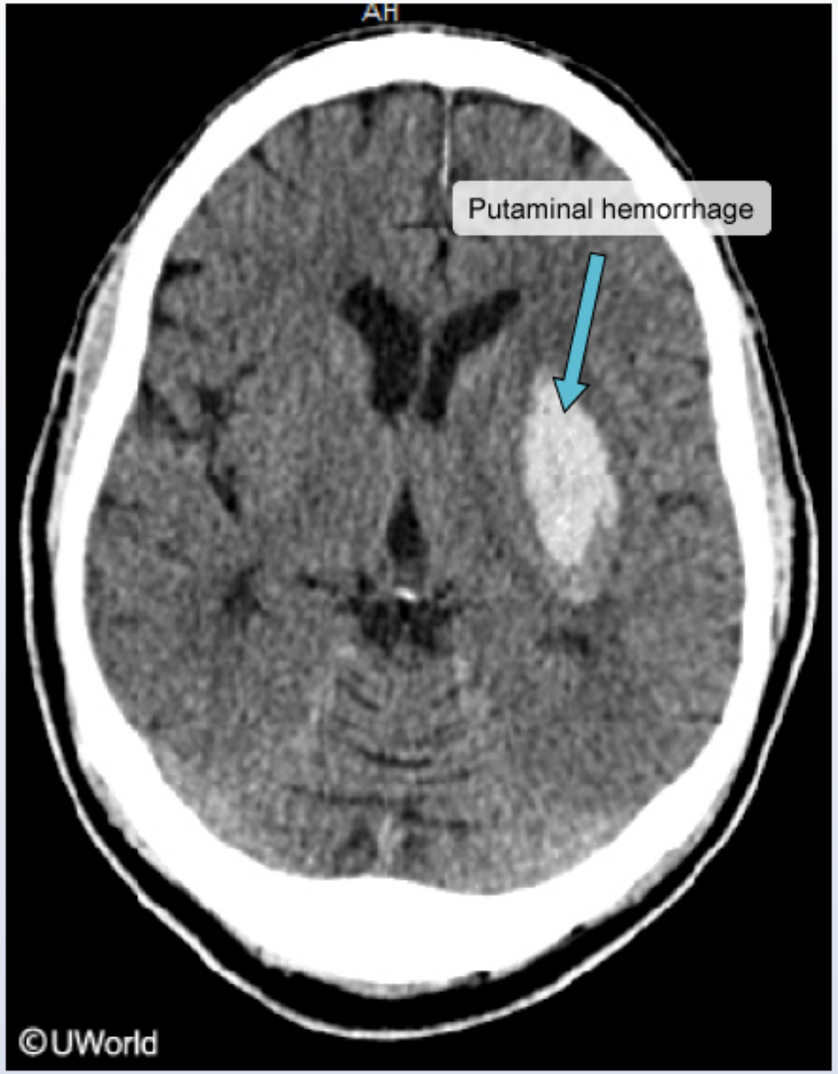

This patient's CT findings (eg, hyperdense mass) are consistent with an acute **putaminal hemorrhage** (ie, affecting the basal ganglia). Because of their location, putaminal hemorrhages almost always affect the adjacent **internal capsule**, leading to **dysarthria**, contralateral **hemiparesis**,

©UWorld

This patient's CT findings (eg, hyperdense mass) are consistent with an acute **putaminal hemorrhage** (ie, affecting the basal ganglia). Because of their location, putaminal hemorrhages almost always affect the adjacent **internal capsule**, leading to **dysarthria**, contralateral **hemiparesis**, and contralateral **hemisensory loss** due to disruption of the corticobulbar, corticospinal, and somatosensory fibers. As the hemorrhage expands, it leads to increase intracranial pressure (headache, nausea/vomiting, and altered mental status), midline shift from mass effect, and possible cerebral herniation.

Hypertensive vasculopathy involving the small, penetrating branches of the major cerebral arteries is the most common cause of spontaneous deep intracerebral hemorrhage. Chronic hypertension leads to the formation of Charcot-Bouchard aneurysms, which may ultimately rupture and bleed within the deep brain structures. The most frequently affected locations include the basal ganglia (putamen), cerebellar nuclei, and pons. The basal ganglia are supplied by the **lenticulostriate arteries**, which are deep, small vessel branches off the middle cerebral arteries.

(Choice A) Cortical branches of the major cerebral arteries are affected in lobar hemorrhages (eg, occipital), as opposed to deep hypertensive hemorrhages. Spontaneous lobar hemorrhages tend to occur in the elderly due to amyloid angiopathy.

(Choices B, E, and F) The middle (inferior and superior divisions) and posterior cerebral arteries are large, proximal vessels arising from the circle of Willis. These arteries are typically associated with ischemic stroke due to thrombotic/embolic vessel occlusion or subarachnoid hemorrhage after saccular aneurysm rupture; intracerebral hemorrhage involving the basal ganglia is more likely due to rupture of deep penetrating arteries.

(Choice D) The pontine arteries are small branches of the basilar artery that can rupture in the setting of poorly controlled chronic hypertension. Pontine hemorrhages usually occur close to the midline and affect both sides of the pons. They typically present with coma (disruption of the reticular activating system), locked-in syndrome (corticospinal and corticobulbar tracts), and pinpoint pupils (descending sympathetic tract).

Educational objective:
Spontaneous deep intracerebral hemorrhage is typically caused by hypertensive vasculopathy involving the small, penetrating branches of the major cerebral arteries. The most frequently affected locations include the basal ganglia (putamen), cerebellar nuclei, thalamus, and pons. The putamen is supplied by the lenticulostriate arteries, which are deep, small vessel branches off the middle cerebral arteries.

References

- Update in intracerebral hemorrhage

©UWorld

Exhibit Display

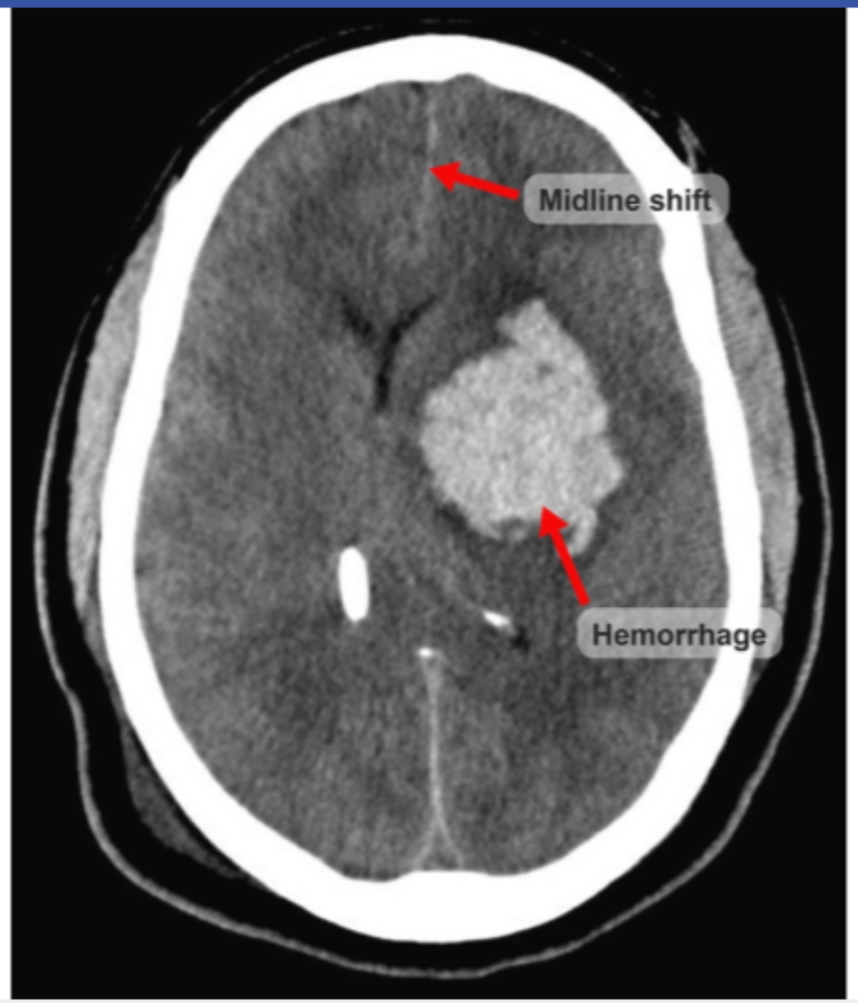

Zoom In Zoom Out Reset Add To New Card | Existing Card

Update in intracerebral hemorrhage

©UWorld

Exhibit Display

Blood supply to the cerebral hemispheres

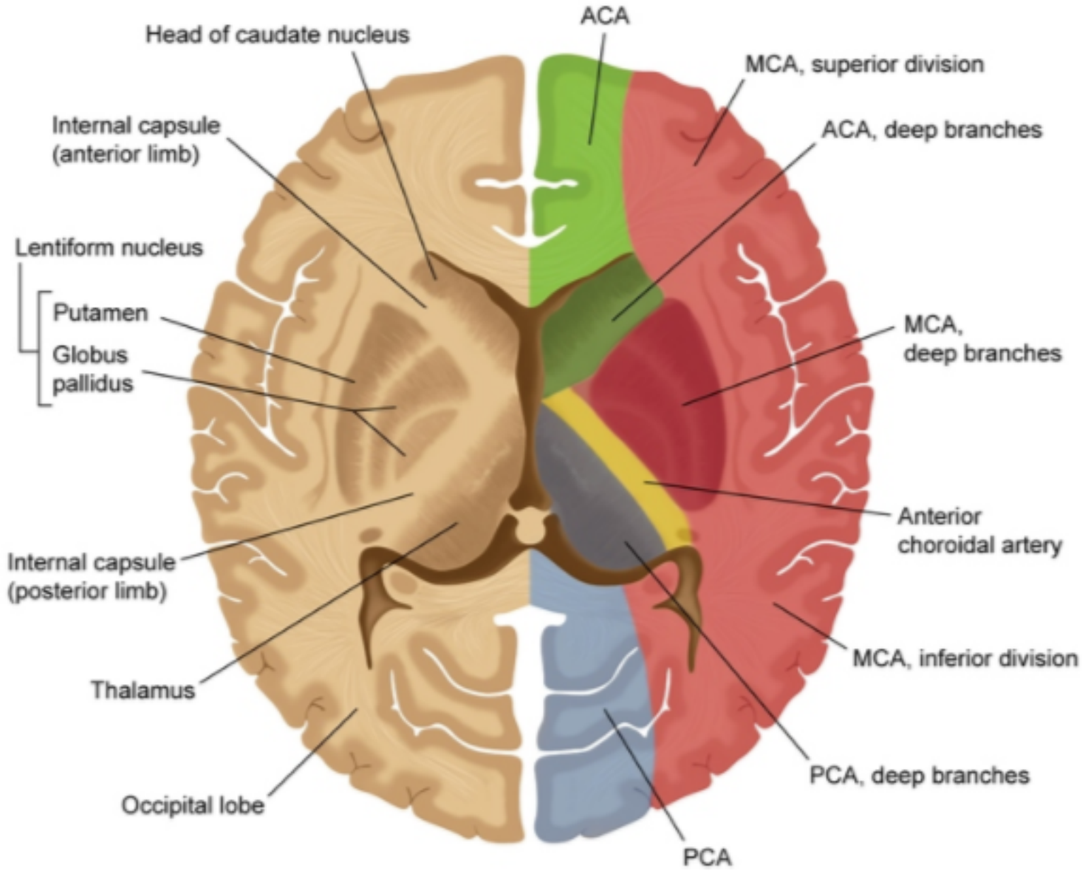

©UWorld

Zoom In | Zoom Out | Reset | Add To New Card | Existing Card

©UWorld

Exhibit Display

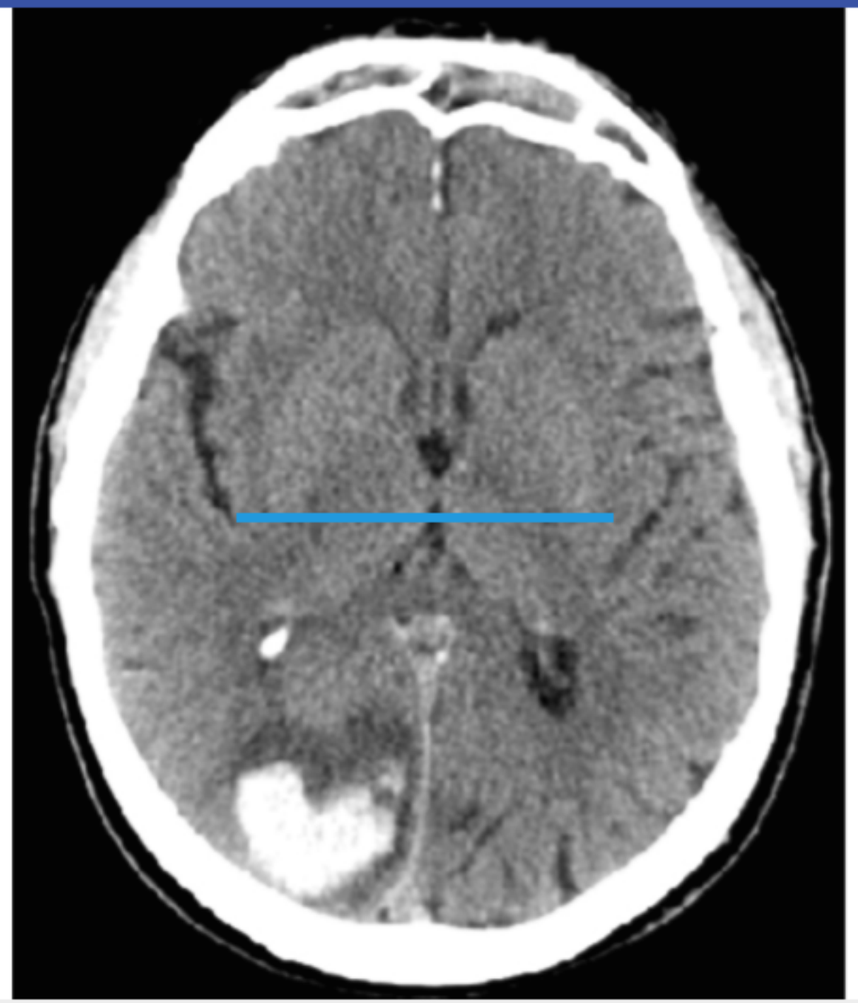

Zoom In
Zoom Out
Reset
Add To New Card | Existing Card

cerebral herniation.

Hypertensive vasculopathy involving the small, penetrating branches of the major cerebral arteries is the most common cause of spontaneous deep intracerebral hemorrhage. Chronic hypertension leads to the formation of Charcot-Bouchard aneurysms, which may ultimately rupture and bleed within the deep brain structures. The most frequently affected locations include the basal ganglia (putamen), cerebellar nuclei, and pons. The basal ganglia are supplied by the **lenticulostriate arteries**, which are deep, small vessel branches off the middle cerebral arteries.

(Choice A) Cortical branches of the major cerebral arteries are affected in lobar hemorrhages (eg, occipital), as opposed to deep hypertensive hemorrhages. Spontaneous lobar hemorrhages tend to occur in the elderly due to amyloid angiopathy.

(Choices B, E, and F) The middle (inferior and superior divisions) and posterior cerebral arteries are large, proximal vessels arising from the circle of Willis. These arteries are typically associated with ischemic stroke due to thrombotic/embolic vessel occlusion or subarachnoid hemorrhage after saccular aneurysm rupture; intracerebral hemorrhage involving the basal ganglia is more likely due to rupture of deep penetrating arteries.

(Choice D) The pontine arteries are small branches of the basilar artery that can rupture in the setting of poorly controlled chronic hypertension. Pontine hemorrhages usually occur close to the midline and affect both sides of the pons. They typically present with coma (disruption of the reticular activating system), locked-in syndrome (corticospinal and corticobulbar tracts), and pinpoint pupils (descending sympathetic tract).

Educational objective:
Spontaneous deep intracerebral hemorrhage is typically caused by hypertensive vasculopathy involving the small, penetrating branches of the major cerebral arteries. The most frequently affected locations include the basal ganglia (putamen), cerebellar nuclei, thalamus, and pons. The putamen is supplied by the lenticulostriate arteries, which are deep, small vessel branches off the middle cerebral arteries.

References

- Update in intracerebral hemorrhage.

Anatomy	Nervous System	Hemorrhagic stroke
Subject	System	Topic

Copyright © UWorld. All rights reserved.

A 63-year-old man comes to the physician's office due to long-standing osteoarthritis that is refractory to over-the-counter analgesics. After discussing various treatment options with his physician, the patient is referred to a surgeon for right total hip arthroplasty. His acute postoperative course is unremarkable. During a follow-up appointment, the patient reports difficulty walking despite minimal pain. On examination, he leans to his right side when walking. When asked to stand on his right leg, the patient's left hip tilts downward. Which of the following nerves is most likely injured in this patient?

A. Femoral

B. Inferior gluteal

C. Obturator

D. Sciatic

E. Superior gluteal

Submit

A 63-year-old man comes to the physician's office due to long-standing osteoarthritis that is refractory to over-the-counter analgesics. After discussing various treatment options with his physician, the patient is referred to a surgeon for right total hip arthroplasty. His acute postoperative course is unremarkable. During a follow-up appointment, the patient reports difficulty walking despite minimal pain. On examination, he leans to his right side when walking. When asked to stand on his right leg, the patient's left hip tilts downward. Which of the following nerves is most likely injured in this patient?

A. Femoral (1%)
B. Inferior gluteal (18%)
C. Obturator (6%)
D. Sciatic (2%)
✓ E. Superior gluteal (70%)

Omitted
Correct answer
E

70%
Answered correctly

02 secs
Time Spent

04/20/2020
Last Updated

Explanation

Superior gluteal nerve injury

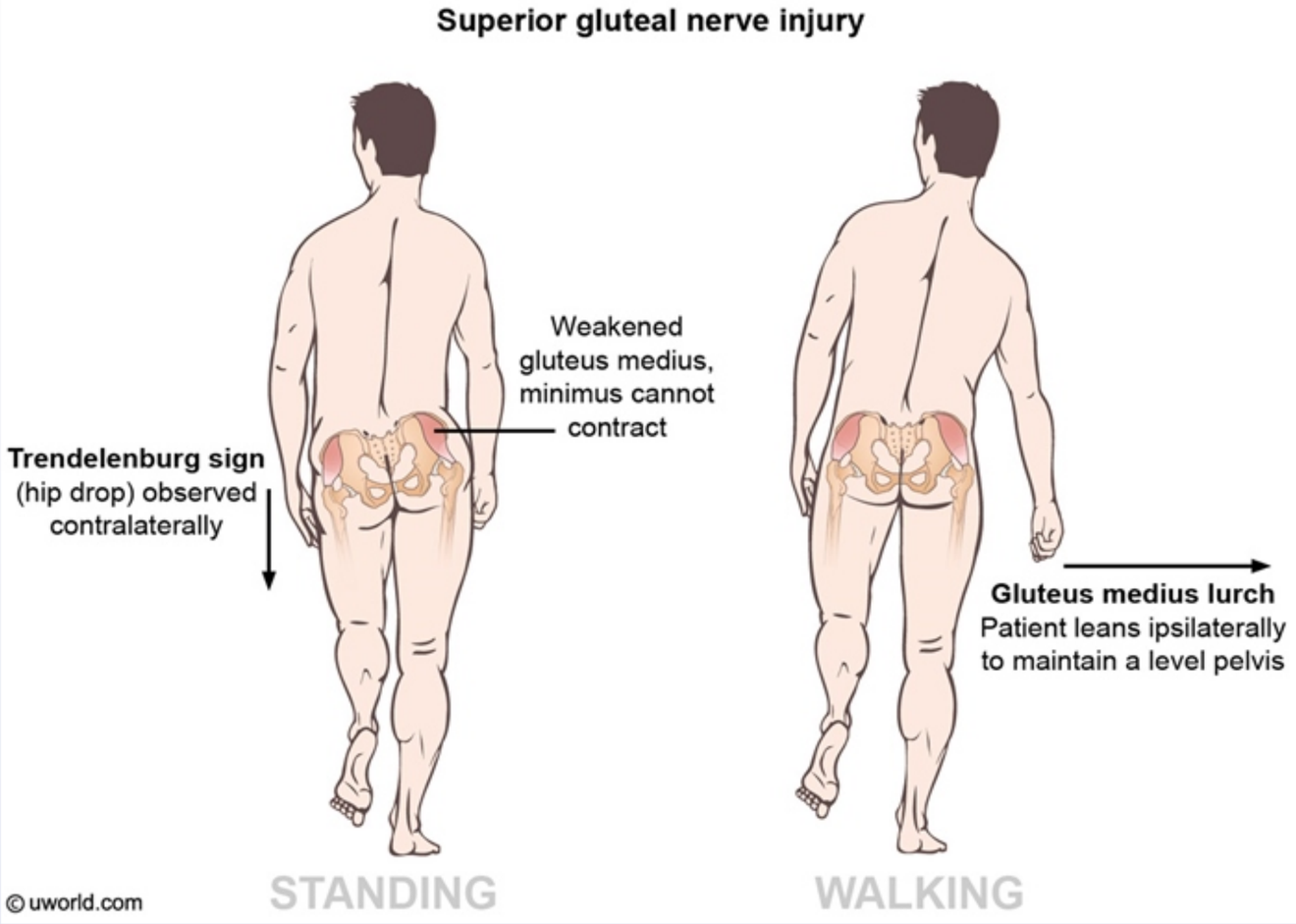

This patient has **superior gluteal nerve injury**, which is most often caused by pelvic trauma or iatrogenic damage occurring during hip surgery or buttocks injections. The superior gluteal nerve innervates the gluteus medius, gluteus minimus, and tensor fasciae latae muscles. These muscles function to stabilize the pelvis and abduct the thigh. Weakness of the gluteus medius and gluteus minimus muscles will cause the pelvis to sag toward the **unaffected (contralateral) side** when the patient stands on the affected leg (**positive Trendelenburg sign**). When walking, the patient will lean toward the **affected (ipsilateral) side** to compensate for the hip drop (**gluteus medius lurch**).

This patient has **superior gluteal nerve injury**, which is most often caused by pelvic trauma or iatrogenic damage occurring during hip surgery or buttocks injections. The superior gluteal nerve innervates the gluteus medius, gluteus minimus, and tensor fasciae latae muscles. These muscles function to stabilize the pelvis and abduct the thigh. Weakness of the gluteus medius and gluteus minimus muscles will cause the pelvis to sag toward the **unaffected (contralateral) side** when the patient stands on the affected leg (**positive Trendelenburg sign**). When walking, the patient will lean toward the **affected (ipsilateral) side** to compensate for the hip drop (**gluteus medius lurch**).

(Choice A) The femoral nerve innervates the muscles responsible for flexion of the thigh at the hip (eg, iliacus and sartorius muscles) and extension of the leg at the knee (eg, quadriceps femoris). It also supplies sensory innervation to the skin on the anterior thigh and medial leg. Injury results in knee buckling and loss of the patellar reflex.

(Choice B) The inferior gluteal nerve innervates the gluteus maximus muscle, which is responsible for extension and external rotation of the thigh at the hip. Inferior gluteal nerve injury typically causes difficulty in rising from a seated position and climbing stairs.

(Choice C) Injury of the obturator nerve causes impaired thigh adduction and medial thigh sensory loss.

(Choice D) The sciatic nerve innervates the muscles in the posterior compartment of the thigh (ie, hamstrings). It subsequently divides into the tibial and common fibular/common peroneal nerves, which provide motor and sensory innervation to the leg and foot.

Educational objective:
Superior gluteal nerve injury results in weakness and paralysis of the gluteus medius, gluteus minimus, and tensor fasciae latae muscles. This causes the pelvis to tilt downward toward the contralateral side (positive Trendelenburg sign). Patients will also lean toward the ipsilateral side when walking to help stabilize the pelvis (gluteus medius gait).

Anatomy	Nervous System	Falls
Subject	System	Topic

Copyright © UWorld. All rights reserved.

A 58-year-old man comes to the office due to worsening right upper extremity weakness over the past 4 weeks. The patient frequently travels for work and has had difficulty carrying heavy bags and getting luggage into or out of the overhead bins. He also has had neck and shoulder pain for the past several months, which he attributes to stress. The patient reports no trauma, and medical history is significant for hypertension. Physical examination shows weakness of shoulder abduction and loss of the biceps reflex on the right side. Pinprick sensation is decreased over the right lateral arm and forearm. Which of the following pathologic processes is most likely underlying this patient's current symptoms?

A. Axonal loss in the corticospinal tracts

B. Cystic expansion of the central canal

C. Degenerative changes in the vertebral joints

D. Microinjury and tear of the rotator cuff tendons

E. Rupture of the long head of the biceps tendon

Submit

A 58-year-old man comes to the office due to worsening right upper extremity weakness over the past 4 weeks. The patient frequently travels for work and has had difficulty carrying heavy bags and getting luggage into or out of the overhead bins. He also has had neck and shoulder pain for the past several months, which he attributes to stress. The patient reports no trauma, and medical history is significant for hypertension. Physical examination shows weakness of shoulder abduction and loss of the biceps reflex on the right side. Pinprick sensation is decreased over the right lateral arm and forearm. Which of the following pathologic processes is most likely underlying this patient's current symptoms?

A. Axonal loss in the corticospinal tracts (7%)

B. Cystic expansion of the central canal (16%)

✓ C. Degenerative changes in the vertebral joints (53%)

D. Microinjury and tear of the rotator cuff tendons (16%)

E. Rupture of the long head of the biceps tendon (5%)

Omitted
Correct answer
C

53%
Answered correctly

02 secs
Time Spent

07/03/2020
Last Updated

Explanation

Mechanisms of radiculopathy

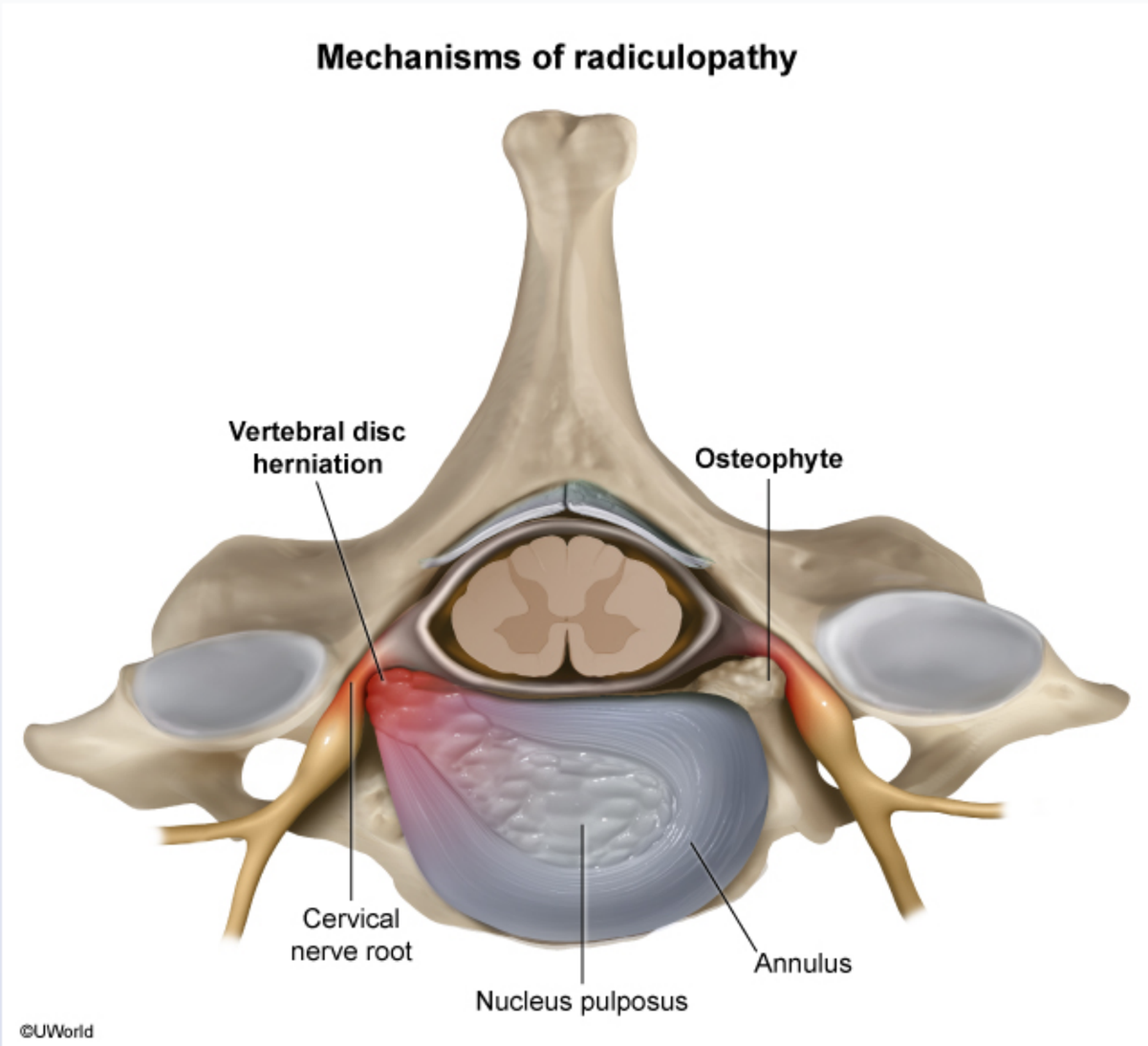

This patient's sensory (eg, lateral arm/forearm sensation loss) and motor deficits (eg, impaired shoulder abduction, biceps reflex) are not isolated to the distribution of a single peripheral nerve (eg, median, ulnar), but rather follow the **C5 dermatomal and myotomal distribution**, indicating

©UWorld

This patient's sensory (eg, lateral arm/forearm sensation loss) and motor deficits (eg, impaired shoulder abduction, biceps reflex) are not isolated to the distribution of a single peripheral nerve (eg, median, ulnar), but rather follow the **C5 dermatomal and myotomal distribution**, indicating **cervical radiculopathy**.

The manifestations of cervical radiculopathies vary depending on the affected nerve root but typically present with **neck or arm pain** associated with motor and/or sensory deficits. Radiculopathies occur due to **compression of spinal nerve roots**, which is most commonly due to either:

- **Spinal spondylosis:** Aging leads to **degeneration** of the vertebral bodies, discs, and joints. Disc space decreases, and joint stress results in osteophyte (eg, bone spur) formation, which slowly narrows the neural foramina and leads to a **subacute onset** of symptoms (as seen in this patient).
- **Vertebral disc herniation:** Degeneration of ligamentous fibers can lead to a tear in the intervertebral disc annulus, resulting in herniation of the nucleus pulposus with potential nerve root compression. Disc rupture typically occurs acutely (eg, during weight lifting).

(Choice A) Axonal loss in the corticospinal tracts occurs in amyotrophic lateral sclerosis, a neurodegenerative disease that affects both upper and lower motor neurons. Although it can result in weakness and atrophy, it would also result in upper motor neuron signs (eg, hyperreflexia), and sensory disturbances would be atypical.

(Choice B) Syringomyelia results from cystic expansion of the central canal in the spinal cord. This can result in upper extremity weakness and sensory deficits, but because it expands from the central portion of the spinal cord, both upper extremities are typically affected, most often in a "cape" distribution.

(Choice D) Microinjury and tear of the rotator cuff tendons can result in weakness of shoulder abduction. However, sensory deficits are unexpected.

(Choice E) Rupture of the long head of the biceps tendon could result in shoulder pain that is aggravated by repetitive overhead activities; a loss of the biceps reflex may be observed if the rupture is complete. However, it would not cause weakness of shoulder abduction (biceps flexes and supinates the forearm) and sensory deficits would not be present.

Educational objective:
Cervical radiculopathy typically results in neck and/or arm pain associated with neurologic deficits that follow a dermatomal/myotomal pattern.

cervical radiculopathy.

The manifestations of cervical radiculopathies vary depending on the affected nerve root but typically present with **neck or arm pain** associated with motor and/or sensory deficits. Radiculopathies occur due to **compression of spinal nerve roots**, which is most commonly due to either:

- **Spinal spondylosis:** Aging leads to **degeneration** of the vertebral bodies, discs, and joints. Disc space decreases, and joint stress results in osteophyte (eg, bone spur) formation, which slowly narrows the neural foramina and leads to a **subacute onset** of symptoms (as seen in this patient).
- **Vertebral disc herniation:** Degeneration of ligamentous fibers can lead to a tear in the intervertebral disc annulus, resulting in herniation of the nucleus pulposus with potential nerve root compression. Disc rupture typically occurs acutely (eg, during weight lifting).

(Choice A) Axonal loss in the corticospinal tracts occurs in amyotrophic lateral sclerosis, a neurodegenerative disease that affects both upper and lower motor neurons. Although it can result in weakness and atrophy, it would also result in upper motor neuron signs (eg, hyperreflexia), and sensory disturbances would be atypical.

(Choice B) Syringomyelia results from cystic expansion of the central canal in the spinal cord. This can result in upper extremity weakness and sensory deficits, but because it expands from the central portion of the spinal cord, both upper extremities are typically affected, most often in a "cape" distribution.

(Choice D) Microinjury and tear of the rotator cuff tendons can result in weakness of shoulder abduction. However, sensory deficits are unexpected.

(Choice E) Rupture of the long head of the biceps tendon could result in shoulder pain that is aggravated by repetitive overhead activities; a loss of the biceps reflex may be observed if the rupture is complete. However, it would not cause weakness of shoulder abduction (biceps flexes and supinates the forearm) and sensory deficits would not be present.

Educational objective:
Cervical radiculopathy typically results in neck and/or arm pain associated with neurologic deficits that follow a dermatomal/myotomal pattern. Osteophytes that form due to degenerative changes in the vertebral joints can progressively narrow the neural foramina leading to nerve root compression.

cervical radiculopathy.

The manifestations of cervical radiculopathies vary depending on the affected nerve root but typically present with **neck or arm pain** associated with motor and/or sensory

- **Spinal spondylosis** in osteophyte (eg, b this patient).
- **Vertebral disc herr** the nucleus pulposu

(Choice A) Axonal loss i lower motor neurons. Alth sensory disturbances wou

(Choice B) Syringomyelia sensory deficits, but becau "cape" distribution.

(Choice D) Microinjury a unexpected.

(Choice E) Rupture of the of the biceps reflex may b supinates the forearm) an

Educational objective:
Cervical radiculopathy typ Osteophytes that form due compression.

ults
n in
n of
and
nd
a
oss
nd

Exhibit Display

Features of cervical radiculopathy

Nerve root (Disc space)	Reflex affected	Sensory loss*	Weakness
C5 (C4-5)	• Biceps	• Lateral upper arm	• Shoulder abduction (deltoid) • Elbow flexion (biceps)
C6 (C5-6)	• Biceps • Brachioradialis	• Thumb • Index finger	• Elbow flexion (biceps) • Forearm pronation/supination (brachioradialis) • Wrist extension
C7 (C6-7)	• Triceps	• Dorsal forearm • Middle finger	• Elbow extension (triceps) • Wrist flexion • Finger extension
C8 (C7-T1)	• Finger flexors**	• Ring & little fingers	• Finger flexion & extension • Thumb flexion & abduction
T1 (T1-2)	• Finger flexors**	• Medial forearm	• Finger abduction & adduction

*In addition to neck/shoulder pain, radicular pain typically has a similar distribution to sensory loss.
**Not typically evaluated clinically.

Add To Flash Card

cervical radiculopathy.

Exhibit Display

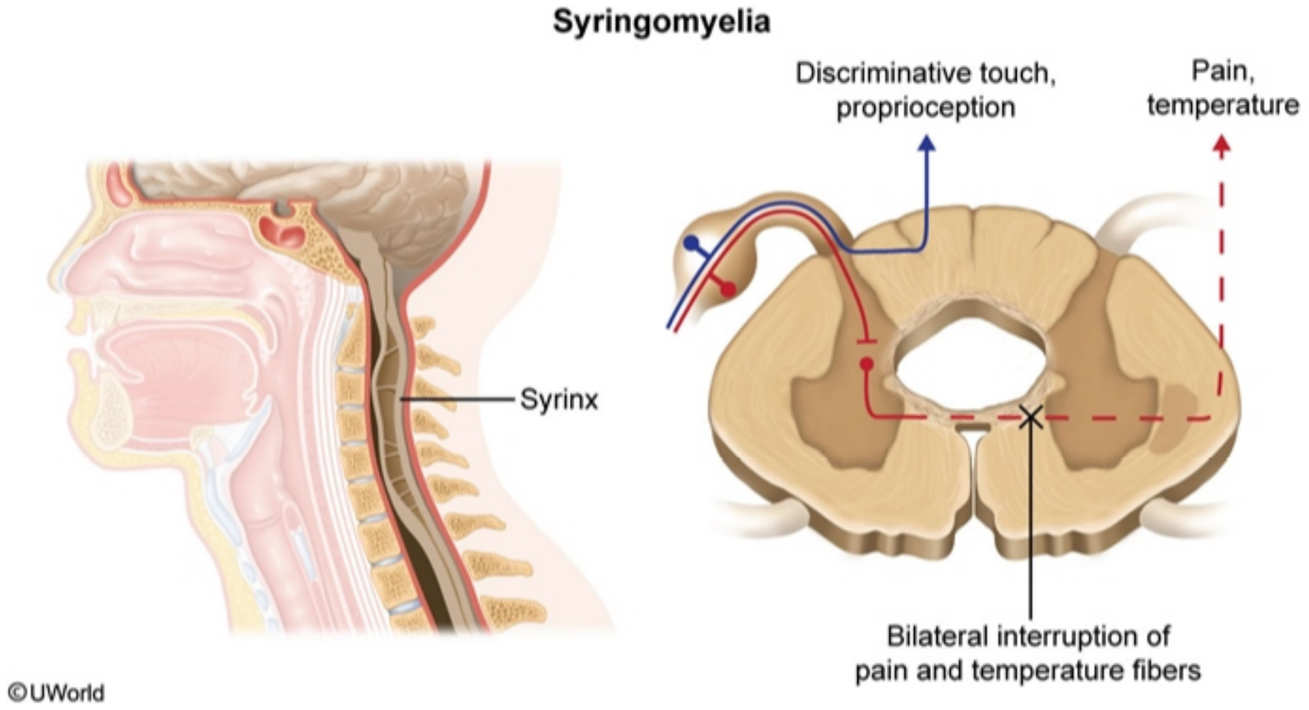

Zoom In
Zoom Out
Reset
Add To Flash Card

- **Spinal spondylosis:** Aging leads to **degeneration** of the vertebral bodies, discs, and joints. Disc space decreases, and joint stress results in osteophyte (eg, bone spur) formation, which slowly narrows the neural foramina and leads to a **subacute onset** of symptoms (as seen in this patient).

- **Vertebral disc herniation:** Degeneration of ligamentous fibers can lead to a tear in the intervertebral disc annulus, resulting in herniation of the nucleus pulposus with potential nerve root compression. Disc rupture typically occurs acutely (eg, during weight lifting).

(Choice A) Axonal loss in the corticospinal tracts occurs in amyotrophic lateral sclerosis, a neurodegenerative disease that affects both upper and lower motor neurons. Although it can result in weakness and atrophy, it would also result in upper motor neuron signs (eg, hyperreflexia), and sensory disturbances would be atypical.

(Choice B) Syringomyelia results from cystic expansion of the central canal in the spinal cord. This can result in upper extremity weakness and sensory deficits, but because it expands from the central portion of the spinal cord, both upper extremities are typically affected, most often in a "cape" distribution.

(Choice D) Microinjury and tear of the rotator cuff tendons can result in weakness of shoulder abduction. However, sensory deficits are unexpected.

(Choice E) Rupture of the long head of the biceps tendon could result in shoulder pain that is aggravated by repetitive overhead activities; a loss of the biceps reflex may be observed if the rupture is complete. However, it would not cause weakness of shoulder abduction (biceps flexes and supinates the forearm) and sensory deficits would not be present.

Educational objective:
Cervical radiculopathy typically results in neck and/or arm pain associated with neurologic deficits that follow a dermatomal/myotomal pattern. Osteophytes that form due to degenerative changes in the vertebral joints can progressively narrow the neural foramina leading to nerve root compression.

Anatomy	Nervous System	Radiculopathy
Subject	System	Topic

Copyright © UWorld. All rights reserved.